THE CENTRAL NERVOUS SYSTEM OF *NAUTILUS*

By J. Z. YOUNG, F.R.S.
Department of Anatomy, University College London

(*Received* 15 *May* 1964)

[Plates 1 to 7]

CONTENTS

The central nervous system of *Nautilus* shows greater similarity to that of coleoid cephalopods than appears at first sight. In the area where the three main cords of the nervous system meet there is a region comparable in position to the magnocellular lobe of coleoids, and it contains large cells. It receives some static nerve fibres and is the origin of the nerves of the ocular tentacles.

The anterior suboesophageal cord is not a single entity. The brachial nerves and nerves of the hood arise from its anterior part, which is directly continuous with the cerebral cord. The funnel nerves arise from a distinct part, continuous with the magnocellular and palliovisceral regions. If the tentacles are innervated from a region derived from the cerebral cord then they cannot be closely compared with the foot of other molluscs.

The cerebral cord shows no clear internal division into lobes, but it is nevertheless organized on a plan recognizably like that of coleoids. Its anterior portion contains large cells and gives rise to the connectives that control the buccal mass. It receives the labial nerves and probably gustatory fibres. In the hinder part of the cerebral cord four regions are recognized. An outer dorsal plexiform zone receives afferents from many sources and perhaps serves to allow responses to combinations of inputs. It is especially developed as lateral cerebral lobes at the entry of the brachial nerve fibres. This zone may be compared with the inferior and superior frontal lobes of *Octopus*.

Fibres pass from the plexiform zone through a layer of small cells to a laminated zone of specialized neuropil. This region corresponds approximately to the vertical lobe of coleoids, but the similarity is not very great. The centre of the cerebral cord contains larger cells, probably providing the output channels to other centres. The ventral portion contains commissural bundles.

The olfactory lobes are relatively larger and the optic lobes smaller than in coleoids. Both are lateral continuations of the cerebral cord and have the same basic structure as the latter. The optic nerve fibres do not form a chiasma between the retina and the optic lobe. The optic lobe shows a general similarity to that of coleoids but there is no external granular layer and no peduncle lobe. There is no distinct optic gland but cells that perhaps represent optic gland tissue occur between the optic and cerebral lobes.

The statocyst is a simple sack with no signs of macula or crista. Its duct remains open in the adult. The static nerve fibres run partly to the magnocellular lobe, partly to the cerebral cord.

The plan of the cerebral cord of *Nautilus* thus appears as a general sketch of the system that exists in coleoids. The 'higher' centres for producing responses from combinations of inputs and perhaps for memory storage are only beginning to emerge from an undivided centre for the reflex control of the operations of feeding.

The fact that *Nautilus* has remained macrosmatic and has poor vision may be connected with the relative simplicity of its higher centres. Nevertheless, its nervous system contains vastly more channels and complex parts than are found in any non-cephalopod mollusc.

INTRODUCTION

It has been clear since the first description by Richard Owen (1832) that the organization of the nervous system of *Nautilus* is very different from that of all other existing cephalopods. The system is usually said to be based on the plan of simple supraoesophageal, pedal and pallioviscera1 nerve cords. Closer examination shows that various differentiated lobes are present, but they are interestingly different from those of coleoid cephalopods. Besides its pin-hole camera eyes and large optic lobes *Nautilus* has large olfactory organs and lobes. There is also a pair of simple statocysts. It has pre- and post-ocular sensory tentacles (Willey 1897*a*), which have their own controlling centre in the brain. The remaining tentacles are of course also highly differentiated and certainly have both receptor and motor functions, being 'adhesive', unlike the ocular tentacles (Willey 1897*b*).

A wide range of information therefore flows into the nervous system of *Nautilus* and some special lobes are present for its analysis. Nevertheless, the supraoesophageal ganglia do not show the differentiated lobes for receptor and higher motor functions that are so striking in higher cephalopods (see Thore 1939; Boycott & Young 1950; Young 1961). Looking at the *Nautilus* brain one has therefore the impression of something that is in some real sense 'simpler' than the familiar 'modern' cephalopod brains and yet at the same time 'different' and indeed even 'differentiated', in its own way. Recent information about the life of the animal confirms that it has indeed its own special modes of action (Bidder 1962). *Nautilus* has survived with some characteristics little changed since all other nautiloids became extinct in the Jurassic period, perhaps 150 million years ago, but it cannot be assumed that everything in it has remained unaltered for this period. Many special features may have developed. Even if this is so there is no doubt that the animal can be regarded as an early offshoot, specialized perhaps, but remaining in many respects at a simple stage of organization. Study of it has proved rewarding in attempting to reconstruct how the homeostatic organization of the cephalopod nervous system has gradually developed to its present state. Indeed by looking at *Nautilus* one can see even further back, to the stages when central nervous systems arose.

There seems to be no previous detailed study of the internal structure of this nervous system. The gross anatomy was described by Keferstein (1866), Huxley (1859), v. Jhering (1877), Kerr (1895), and Griffin (1897 and 1900) but they all base their accounts on Owen.

Even the descriptions of the gross anatomy, depending on dissection, which is difficult in this animal, have given only a poor indication of the shapes of the lobes of the central nervous system. Individual parts have been dealt with by various authors; the eyes by Hensen (1865) and Merton (1905), tentacles and rhinophore by Keferstein (1866) and sexually dimorphic tentacles and spadix by Fernandez (1907) and Vayssière (1896). The present study therefore attempts to provide a fuller description of the gross anatomy of the nervous system, based upon dissection and re-construction from sections. In addition there is as full an account of the internal structure and fibre connexions as is possible with the limited material available.

MATERIALS AND METHODS

The material comes from three sources. A number of specimens from Dr A. Willey's expedition (1897) preserved in alcohol are now at University College. Secondly, through the kindness of Professor D. Barker, I was able to obtain eight specimens from Noumea preserved in formalin. Thirdly, Dr A. Bidder kindly sent a specimen from Noumea after fixation in 10% formol in sea water. She also fixed a number of brains in 3% potassium bichromate or with 10% formol for Golgi staining and sent them to London. No neurons were stained, but the preparations were useful in other ways. Willey's specimens are recorded as *N. pompilius* Lam. The others, because of their origin, are probably of the group known as *N. macromphalus* Sowerby. As there are no known differences between the soft parts of these 'species', all specimens will be considered together.

The central nervous system of *Nautilus* is widely spread out and difficult to dissect. It is therefore necessary to cut long series of sections through large blocks of undissected material. This was done for several series after staining the block by the modified Cajal's method that has been found to be effective in other cephalopods (Young 1939). In *Nautilus* the silver stain has not been really successful, but cells and their nuclei are often well shown and tracts of nerve fibres and neuropil are vaguely differentiated. Other series stained with haematoxylin and eosin or Mallory's or Masson's stains, generally showed less than the Cajal preparations.

The preserved tissues of *Nautilus* proved to be very difficult to stain differentially either with silver or dyes. It is therefore not easy to illustrate the points of micro-anatomy. An attempt has, nevertheless, been made to provide photographic evidence wherever possible since no other descriptions of the histology of the nervous system of the animal are available.

FORM OF THE CENTRAL NERVOUS SYSTEM

At first sight it seems that there is little similarity between the system of ganglionated nervous cords that are found in *Nautilus* and the nerve centres concentrated round the oesophagus of a coleoid cephalopod (figure 1). By looking at the nervous system from the side or medially, however, we see at once a quite striking resemblance (figures 2 and 3). Figure 2 has been made by reconstruction from transverse sections, and shows the maximum outlines of the lobes projected on to a single plane. This view shows that the system is made up of one supraoesophageal and two suboesophageal parts. The three meet at the sides in a region that belongs to none of the other regions but is lateral (or peri-oesophageal). This region exactly corresponds to the position of the magnocellular lobe of

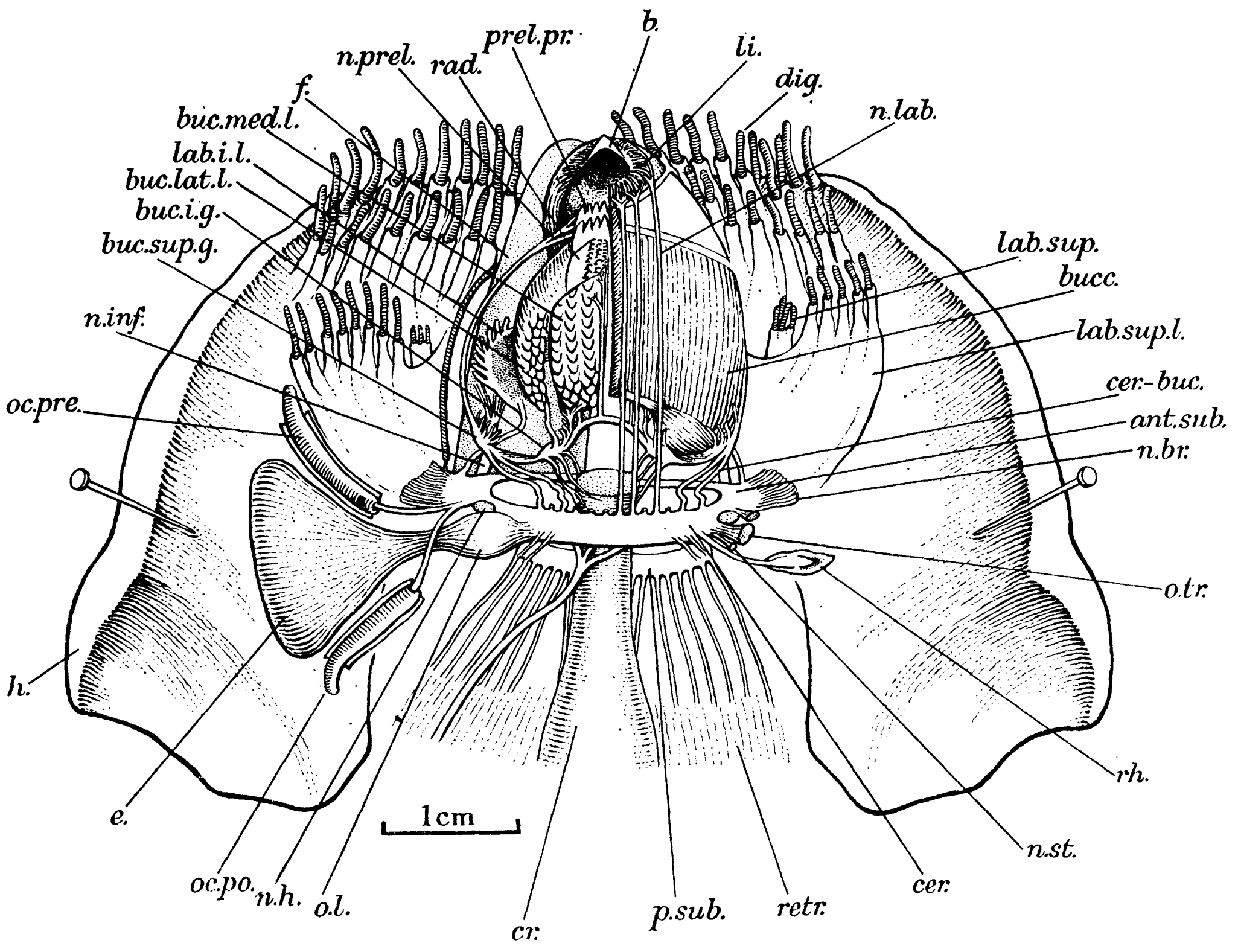

FIGURE 1. Drawing of dissection of the nervous system and buccal mass. The dissection has been carried deeper on the left than the right. The tentacles are shown somewhat diagrammatically. For abbreviations see p. 25.

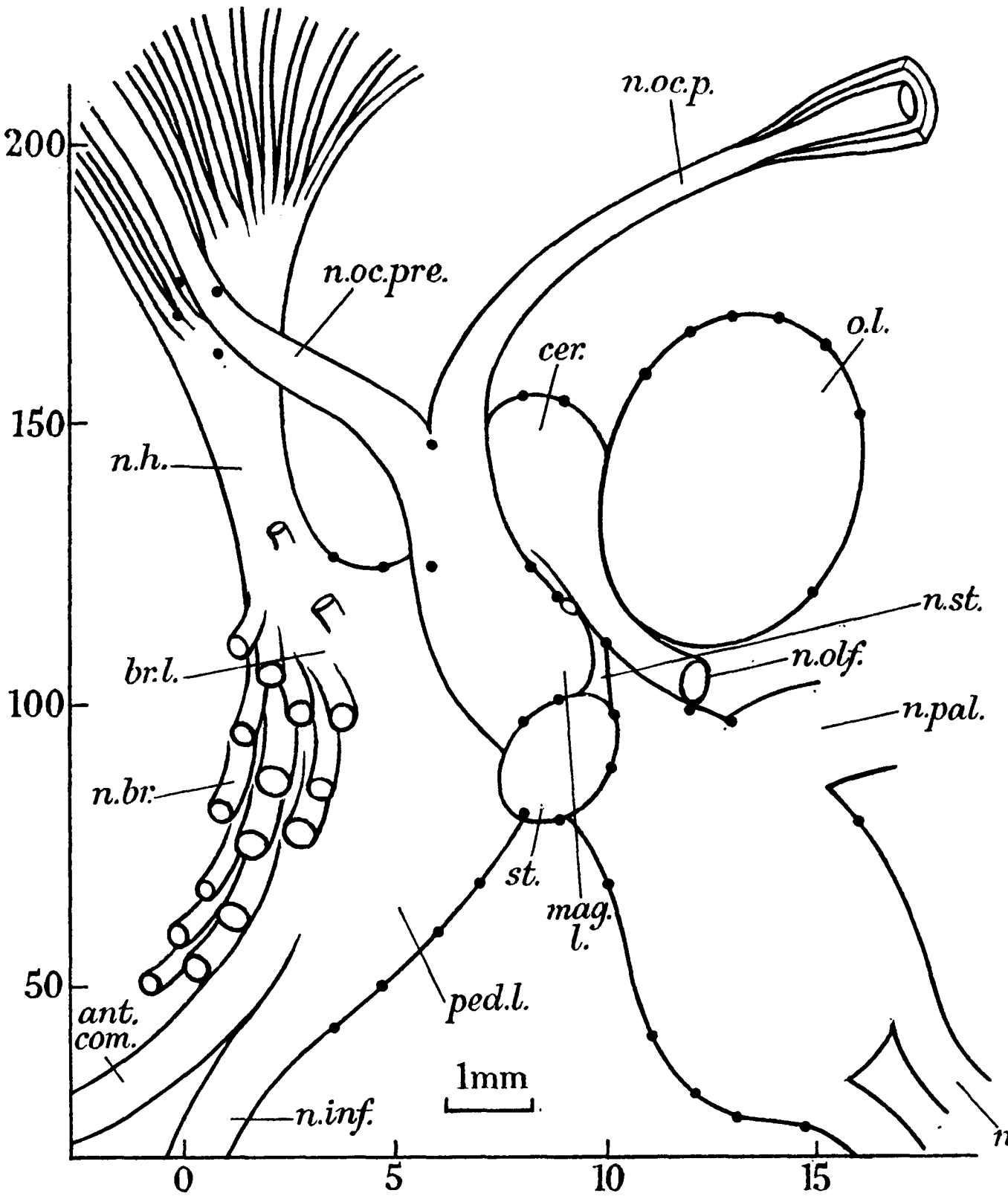

FIGURE 2. Reconstruction of the maximum outlines of the lobes of the central nervous system as seen from the side. The reconstruction was made by measuring on photographs of serial transverse sections at a magnification of 15 ×. Some of the plotted points are shown. The brachial and other nerves have been completed diagrammatically. (Scales arbitrary.)

coleoids (Young 1939). As in the latter it contains some of the most important motor centres of the animal.

The region at the sides of the circumoesophageal ring is indeed the 'central' part of the whole system. Not only do the three cords converge here but at this level the afferent fibres from the eyes, arms, lips, statocysts, olfactory organs and cephalic tentacles all enter. This lateral region of the brain influences the main motor systems, namely the buccal mass, the arms, the funnel and the head retractor muscles. It is not yet possible, however, to understand, even in a general way, how this central co-ordination of action is produced.

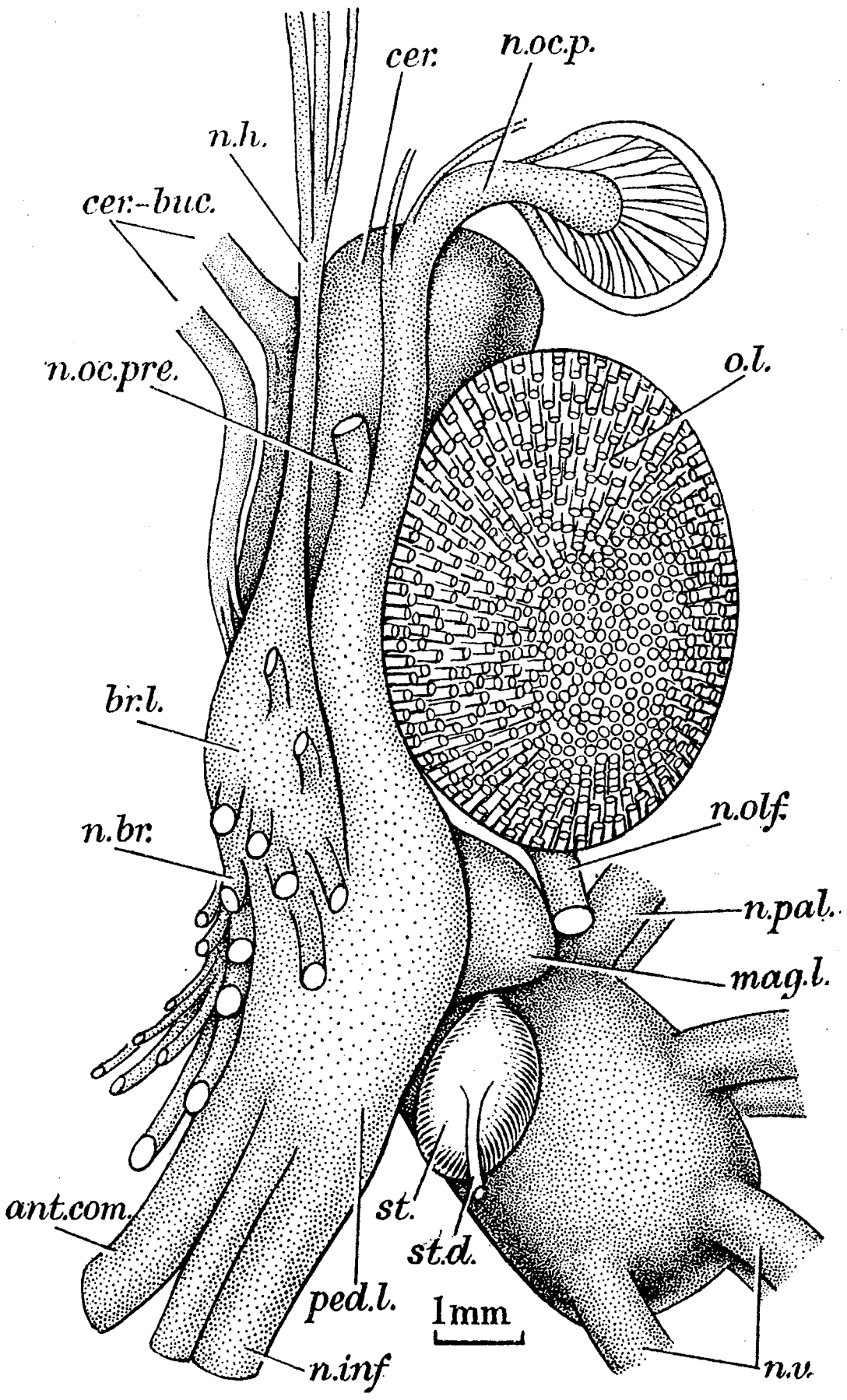

FIGURE 3. Reconstruction of the outlines of the main parts of the nervous system from tracings of serial sagittal sections, as seen from the side.

REGIONS OF THE CENTRAL NERVOUS SYSTEM

The region at the side of the brain is difficult to dissect and has therefore never been properly described. Moreover, the nomenclature generally used for the nervous system in molluscs provides no names for describing these lateral regions, although they are so important. In the mid-line there is no difficulty in recognizing a supraoesophageal (cerebral) cord and anterior and posterior suboesophageal ones. Difficulties arise when we try to compare these cords with the ganglia of other molluscs. In particular the anterior cord is often called 'pedal'. It gives rise to nerves for the tentacles and the funnel, and since the latter is undoubtedly a derivative of the foot the tentacles are considered to arise from the same source. It will be shown later that in fact the anterior cord contains two distinct parts. One part is directly continuous with the supraoesophageal cord, whilst the other more posterior part gives rise to the nerve to the funnel and is continuous dorsally with the magnocellular region. It can therefore be argued that the more anterior part is truly 'brachial' and the posterior 'pedal'. The former is essentially cerebral, and indeed innervates the head shield as well as the tentacles. These latter may therefore well be cephalic structures after all and the name cephalopod in this sense is a misnomer (Kerr 1895).

While there is still too little information to be certain about this, it is best to speak of 'anterior suboesophageal cord'. The only disadvantage of this name is that the structure in question does not exactly correspond to the anterior suboesophageal (pre-brachial and brachial) lobe of coleoids (Boycott & Young 1965).

Further lobes that will be recognized are first the optic lobes at the sides, clearly comparable to those of coleoids, and especially interesting in *Nautilus* because they are directly continuous with the supraoesophageal cord (figure 8). Secondly, the olfactory lobes lie in the expected position, at the back of the optic tract, but are much larger than in recent cephalopods. *Nautilus* can be regarded as a 'macrosmatic animal', the later cephalopods being 'microsmatic'. The olfactory lobes, like the optic, are lateral extensions of the supraoesophageal cord. There are two pairs of 'ocular tentacles', absent in the coleoids. These are innervated from the upper part of the magnocellular region, which lies at the side of the brain (figures 2 and 4).

The cerebro-buccal connectives arise from small swellings at the sides and front of the supraoesophageal cords, and these swellings will be called the posterior buccal lobes. Various other regions will be recognized within the supraoesophageal cords (p. 13), but the only lobules that are clearly differentiated are called 'lateral cerebral lobes' and lie at the sides, above the anterior suboesophageal cord and near the region where all the receptor systems enter (figure 4). They correspond approximately to the inferior frontal centres of some coleoids but they may be a special development of *Nautilus* (p. 22).

The buccal nerve apparatus was described by Kerr (1895) and Griffin (1900). They called the ganglia at the sides of the buccal mass 'pharyngeal', but they seem clearly to correspond to the superior buccal ganglia of decapods and they will be so named here (figure 1). The 'buccal ganglia' of these authors then become 'inferior buccal' and, as they thought, they probably give rise to the 'sympathetic' nerves, as in coleoid cephalopods. The naming of these ganglia is of some importance, since the view will be taken that the whole organization of the cerebral centres is concerned largely with the mechanism allowing for decision as to what to eat (p. 22).

The superior buccal ganglia are joined to the supraoesophageal cord by two pairs of cerebro-buccal connectives. From these ganglia prelingual nerves run to the lower lips (figure 1). The lips may be part of the tentacular apparatus and their nerves perhaps really come from the brachial lobes (p. 12).

POSTERIOR SUBOESOPHAGEAL CORD (PALLIOVISCERAL)

In its median part the cord is circular in section, with visceral nerves springing from its postero-ventral region (figure 9, plate 1). Around all other parts of the periphery of the cord there is a thick layer of large pear-shaped cells, reaching 20 to 40 μm (nuclei

10 μm) in diameter. The largest cells lie mostly at the periphery, with somewhat smaller ones in the deeper layers (figure 11, plate 1). The smallest are about 10 μm in diameter (nuclei 6 μm).

The centre of the cord does not consist of a simple neuropil but contains islands of cells of medium and smaller size (figure 10, plate 1). There are also numerous blood vessels.

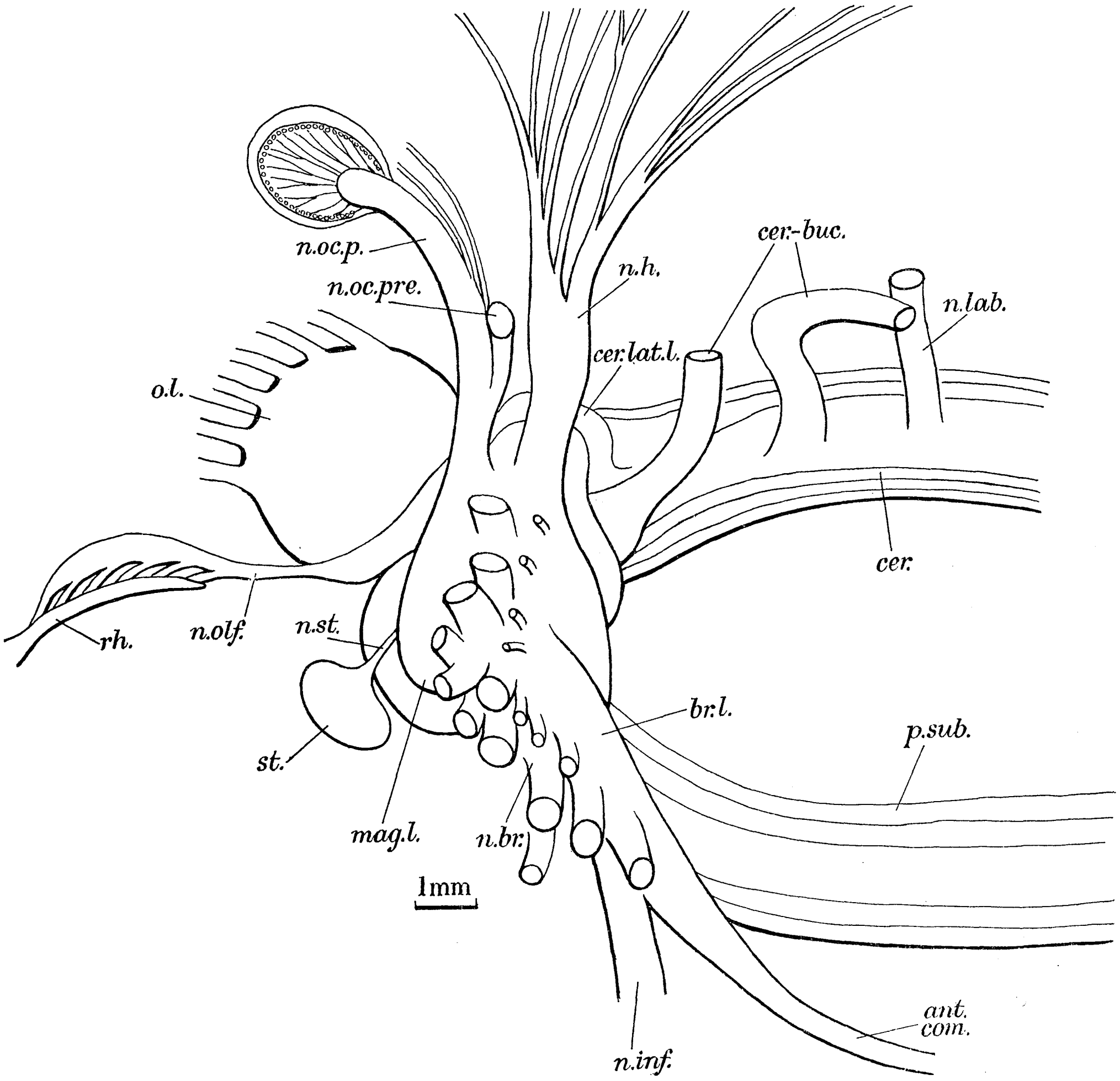

FIGURE 4. Reconstruction of central nervous system from tracings of serial transverse sections. As seen from the front.

The only obvious differentiation within the cord is the presence of many commissural bundles in the postero-ventral region (figure 9, plate 1). As in higher cephalopods the visceral nerve bundles leave partly above, and partly below these commissures.

Passing more laterally the cord comes to have few cells on its posterior face. The pallial nerves are then seen arising from the postero-dorsal margin (figure 12, plate 1). The pallial nerves run mainly to the large head retractor muscles, by which the animal withdraws into its shell. Some bundles run through the muscles to the wall of the mantle, which is non-muscular. There are no stellate ganglia.

From the dorsal edge of the posterior cord there also arise some small bundles that run up behind the cerebral cord and are lost among the muscles of the head (figure 13, plate 1; figure 49, plate 5). They have been provisionally called ophthalmic nerves.

At its dorso-lateral end the posterior cord comes into contact with the back of the anterior suboesophageal cord (figure 14, plate 1). There is some interchange of fibres and both cords receive fibres here from the lower (motor) part of the supraoesophageal cord. However, the posterior cord does not here run up directly into the supraoesophageal region but continues laterally as the magnocellular region.

At this level we therefore see on a sagittal section complete continuity between the cerebral and anterior suboesophageal cords, but a gap between the cerebral and posterior cords (figure 14, plate 1; figure 34, plate 3). This gap will be called the cerebral fissure and it contains a large artery. More laterally the magnocellular lobe passes up *behind* the cerebral fissure, which thus appears as a hole in sagittal section. Still further laterally the fissure opens again to form a crack between the olfactory and magnocellular lobes (figure 24, plate 2).

Anterior suboesophageal cord

The problem of describing the parts of this cord involves the difficult question of whether the cephalic shield, tentacles and funnel should all be regarded as derivatives of the molluscan foot. The nerves for all of these arise from the anterior suboesophageal cord but the cells of origin of the funnel nerve fibres are probably in the more posterior part of the cord, or perhaps in the magnocellular lobe. The funnel is almost certainly to be regarded as a pedal derivative and the term 'pedal cord' as applied to the whole structure involves us in great difficulties. It will be better to use the neutral 'anterior suboesophageal cord', recognizing that it has anterior brachial and posterior infundibular parts.

The main bulk of the anterior suboesophageal cord lies at the sides as a pair of strap-like structures (figure 1). Each cord narrows ventro-medially to form a thin strand, the anterior suboesophageal commissure. Unlike the posterior commissure this contains few nerve

Description of plate 1

Figure 9. Sagittal section of posterior suboesophageal cord near the mid-line showing origin of visceral nerves.

Figure 10. Sagittal section of posterior suboesophageal cord near the mid-line, showing cell layer and neuropil.

Figure 11. T.S. posterior suboesophageal cord showing cell layers and bundles of fibres running transversely.

Figure 12. Sagittal section of posterior suboesophageal cord near its lateral edge, showing origin of pallial nerves.

Figure 13. Sagittal section of lateral part of posterior suboesophageal cord, showing origins of the nerves that run behind the cerebral cord (ophthalmic nerves).

Figure 14. Sagittal section at point of union of the three cords.

Figure 15. Section somewhat lateral to figure 14.

Figure 16. Sagittal section of lower part of anterior suboesophageal cord.

Figure 17. Sagittal section to show continuity of structure between the cerebral cord and brachial part of the anterior suboesophageal cord.

Figure 18. Sagittal section to show brachial nerve fibres running directly to the lateral cerebral lobe.

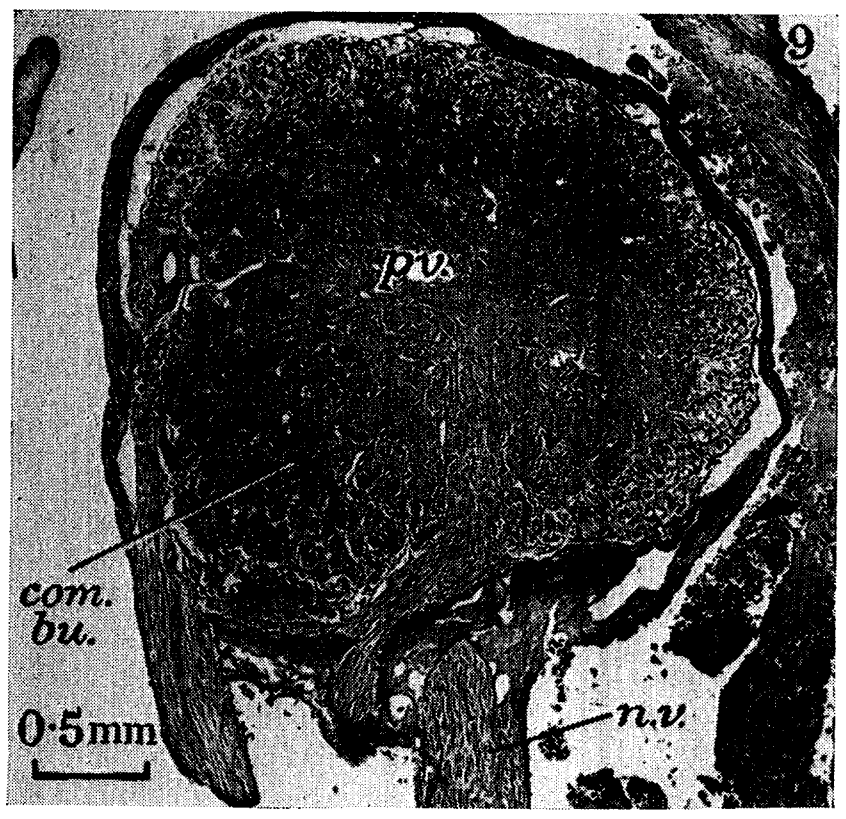
9
pv.
com.
bu.
n.v.
0·5mm

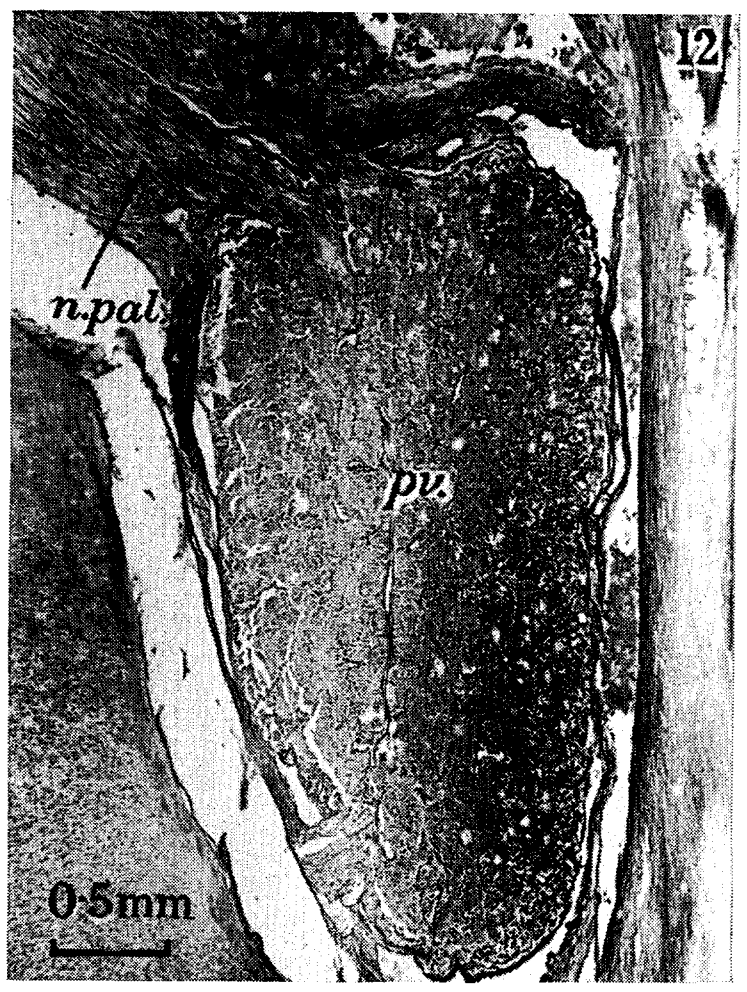
12
n.pal.
pv.
0·5mm


11
100 μm


13
n.op.
pv.
200 μm

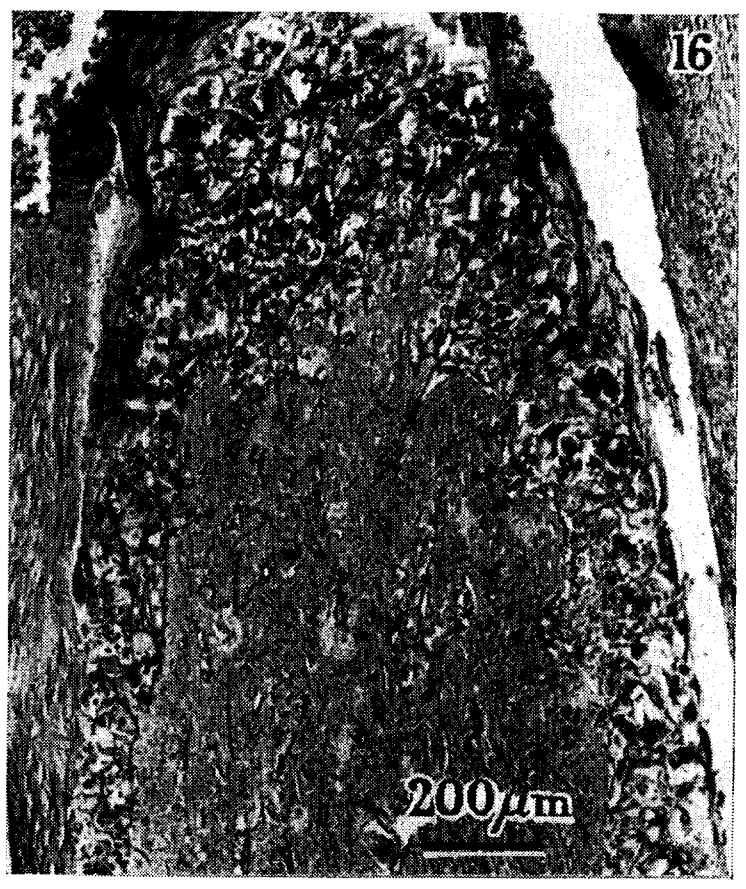
16
200 μm

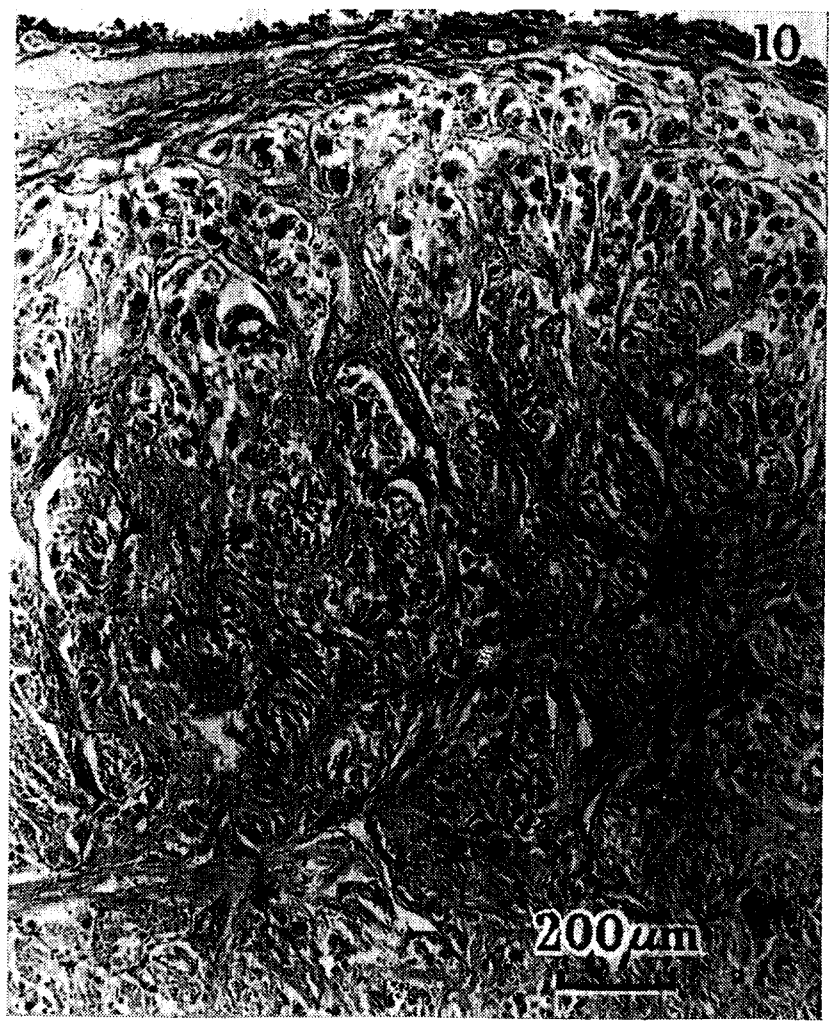
10
200 μm


17
cer.
br.l.
200 μm


14
cer
cer.fis.
pv.
ant.
sub.
1mm


15
cer.fis.
br.
l.
st.
ant.
com.
n.inf.
1mm

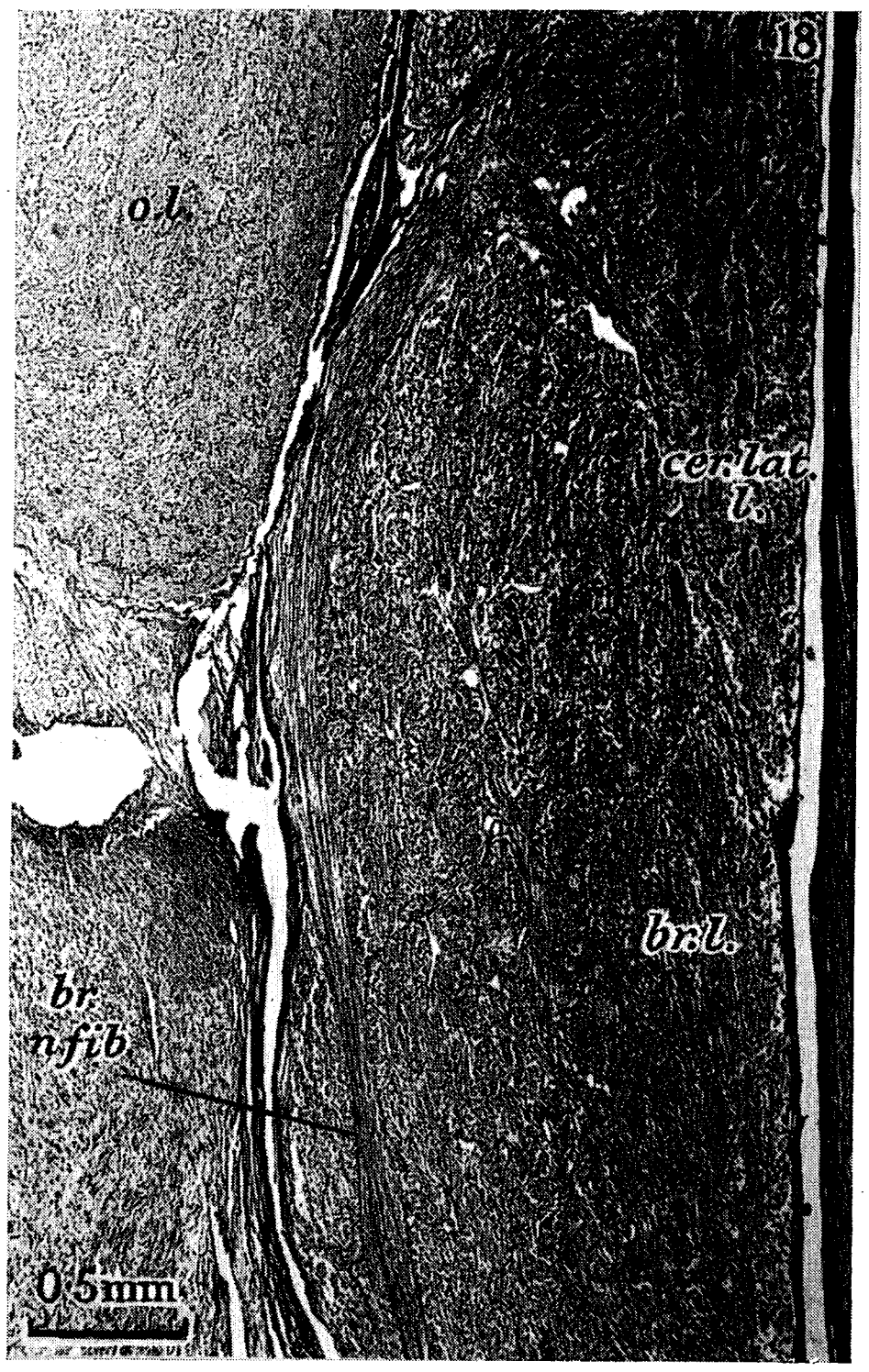
18
o.l.
cer.lat.
l.
br.l.
br.
n.fib.
0·5mm

(Facing p. 8)


19
inf.l.
br.l.
40 μm

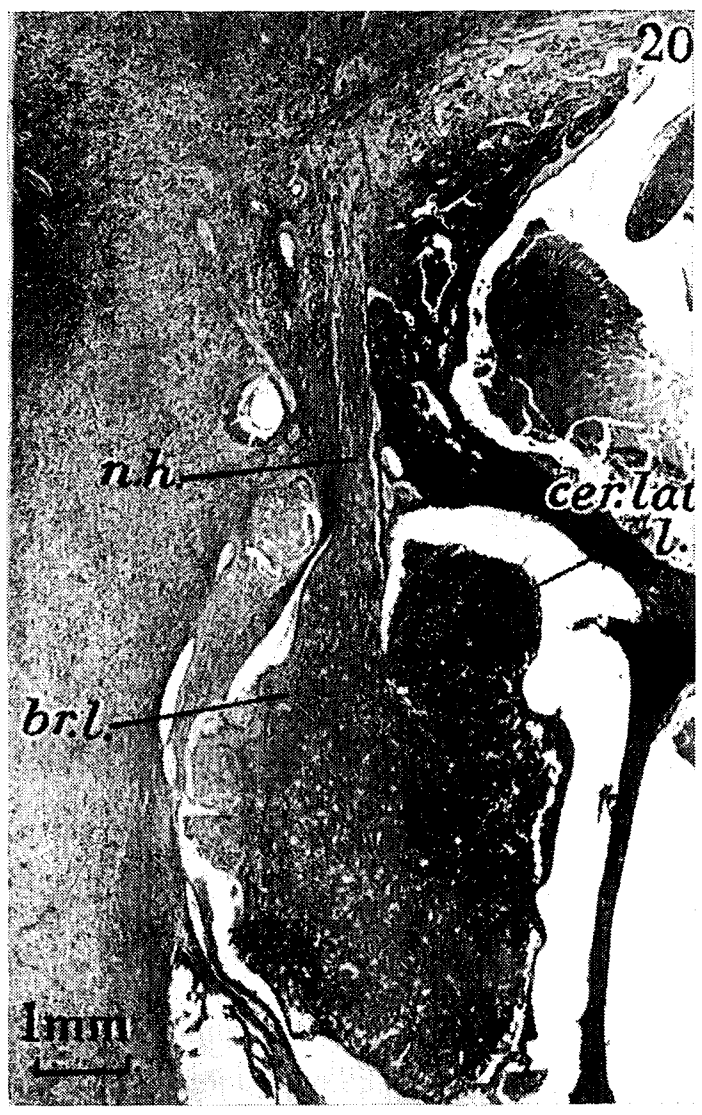
20
n.h.
cer.lat. l.
br.l.
1mm

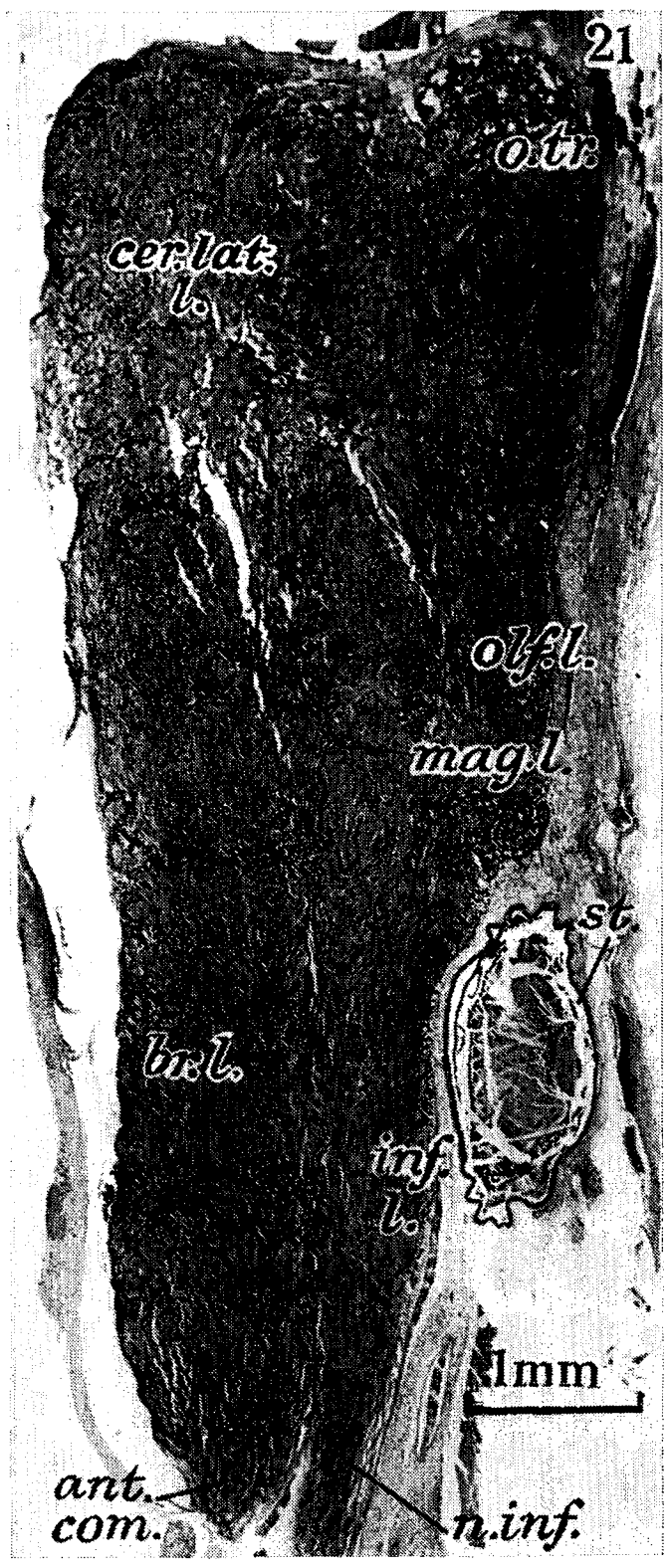
21
o.tr.
cer.lat. l.
olf.l.
mag.l.
st.
br.l.
inf. l.
1mm
ant. com.
n.inf.


22
gc.
n.st.
st.
200 μm

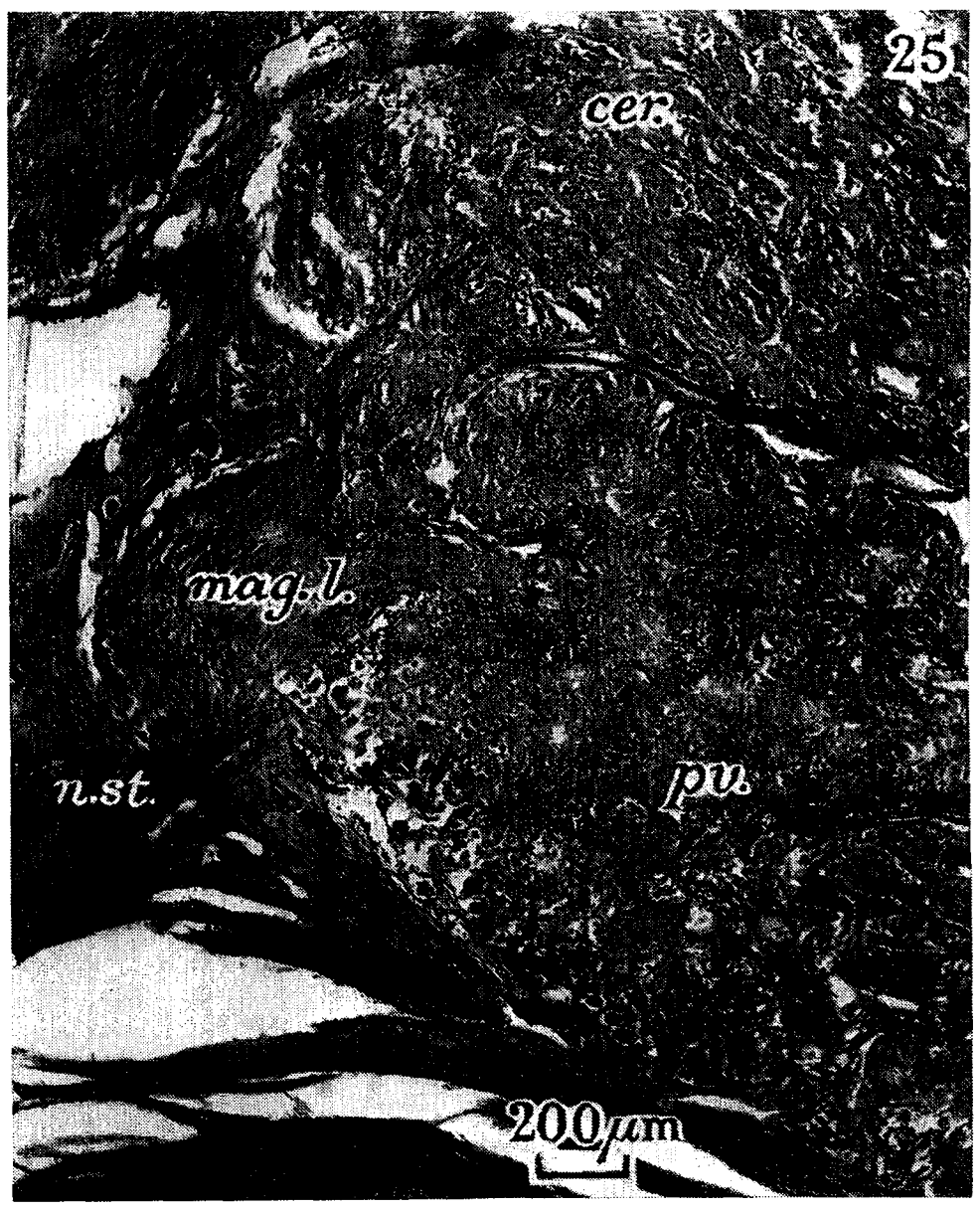
25
cer.
mag.l.
n.st.
pv.
200 μm


26
50 μm

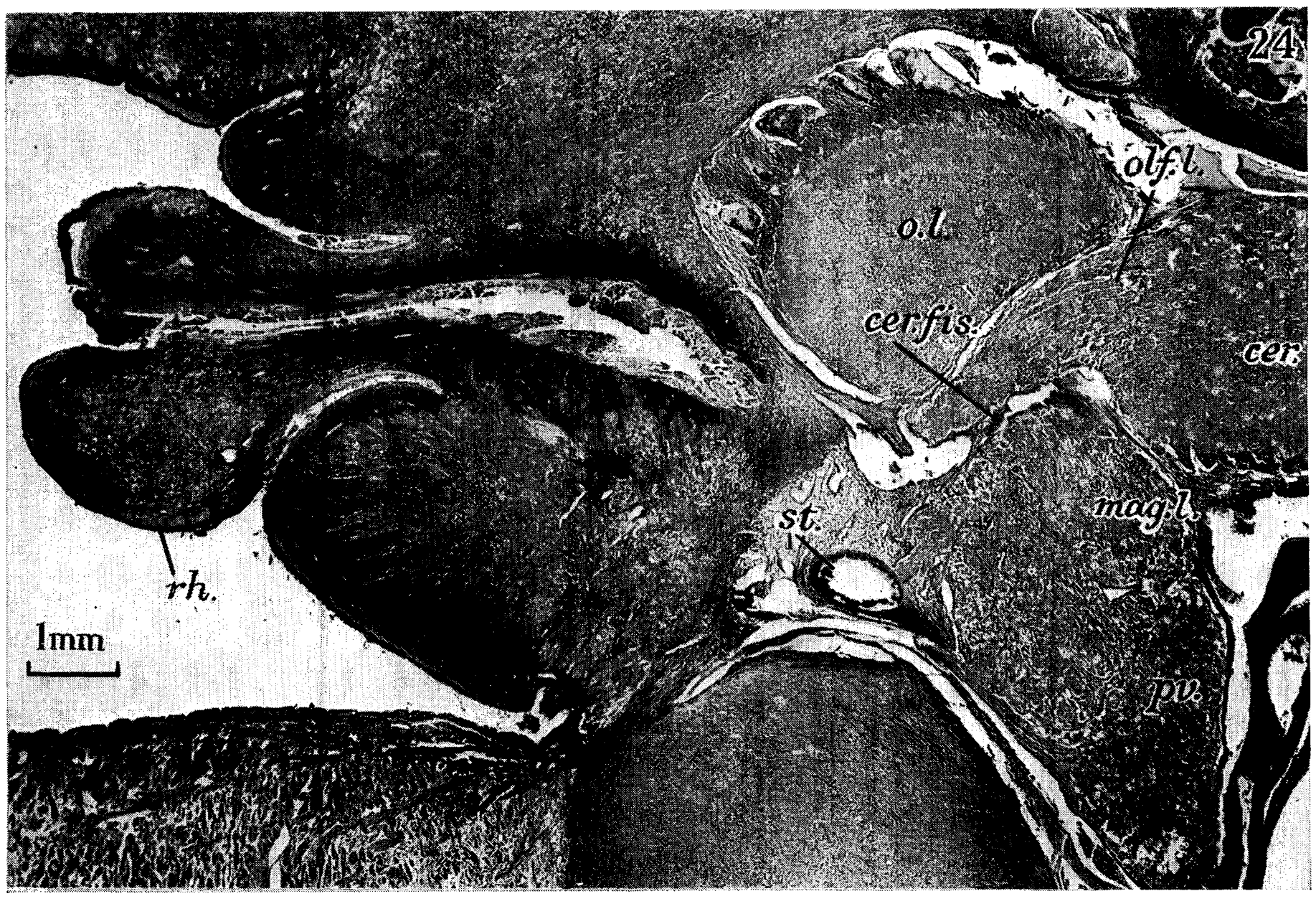
24
olf.l.
o.l.
cer.fis.
cer.
mag.l.
st.
rh.
1mm
pv.


23
n.oc.p.
cer.lat.l.
cer.
mag.l.
st.
1mm

PLATE 2

FIGURE 19. Sagittal section of boundary between infundibular and brachial lobes.

FIGURE 20. T.S. lateral region of brachial lobe, showing origins of nerve to the hood.

FIGURE 21. Sagittal section to show union of the brachial with the cerebral lobe and of the infundibular with the magnocellular lobe.

FIGURE 22. Sagittal section of entry of static nerves to the magnocellular lobe, showing the giant cells (much shrunken).

FIGURE 23. T.S. of origin of the nerve to the post-ocular tentacle from the magnocellular lobe.

FIGURE 24. T.S. showing the cerebral fissure. Also the rhinophore and its cavity and the olfactory and optic lobes.

FIGURE 25. T.S. entry of static nerve and some of its fibres running to the posterior cord.

FIGURE 26. Section of nerve cord and cells in post-ocular tentacle.

Plate 3

Figure 27. T.S. wall of statocyst. The figure shows the cells in their correct orientation with the inner ends pointing upwards. Haematoxylin and eosin.

Figure 28. T.S. wall and contents of statocyst. As figure 27.

Figure 29. T.S. statocyst to show Kölliker's canal.

Figure 30. Sagittal section of the outer end of Kölliker's canal.

Figure 31. Proximal part of Kölliker's canal in a sagittal section, showing ciliated cells.

Figure 32. T.S. of origin of static nerve.

Figure 33. Sagittal section to show static nerve fibres running to the cerebral cord. Haematoxylin and eosin.

Figure 34. Sagittal section to show origin of the lateral cerebro-buccal connective.

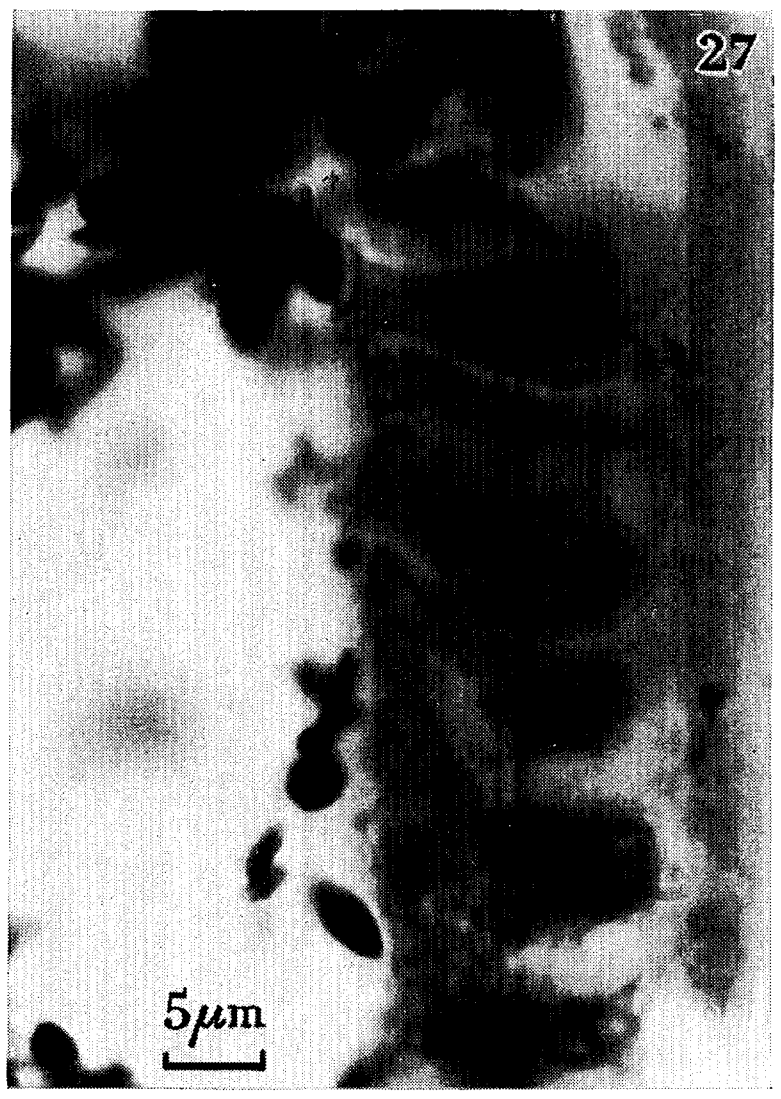
27
5μm


28
10μm

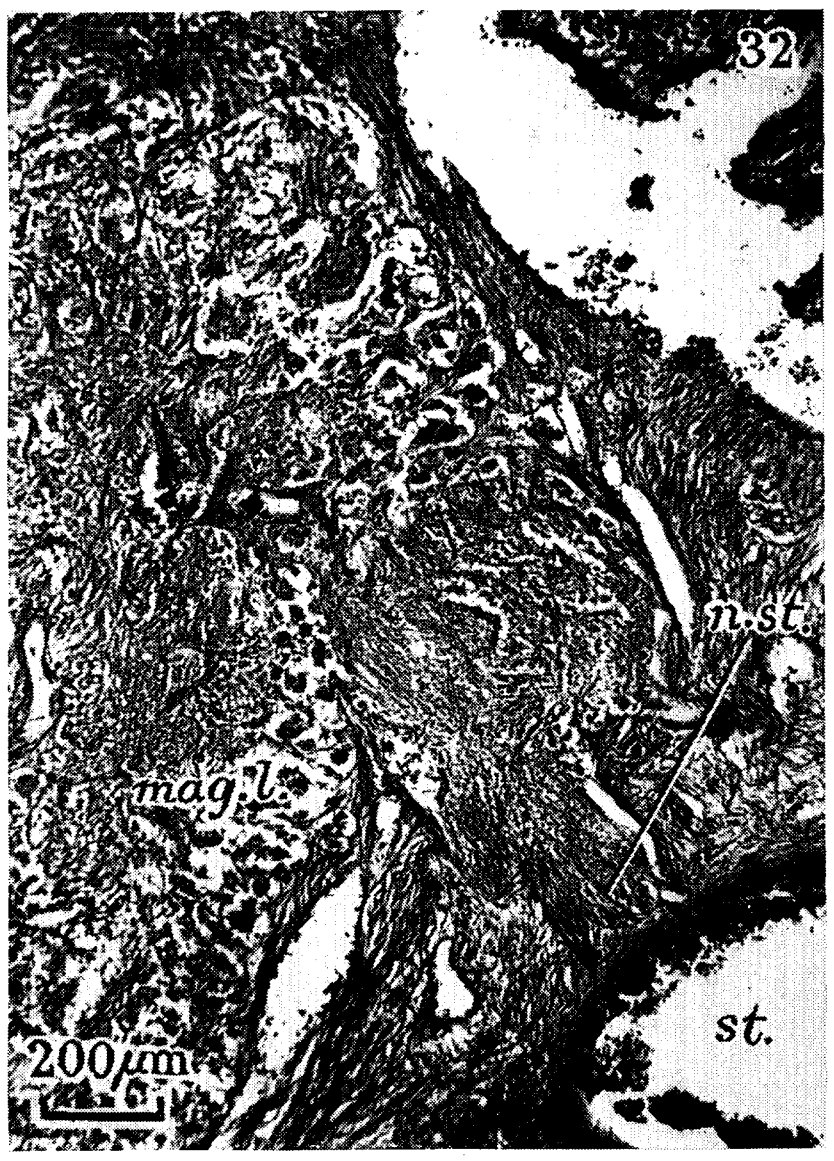
32
n.st.
mag.l.
st.
200μm

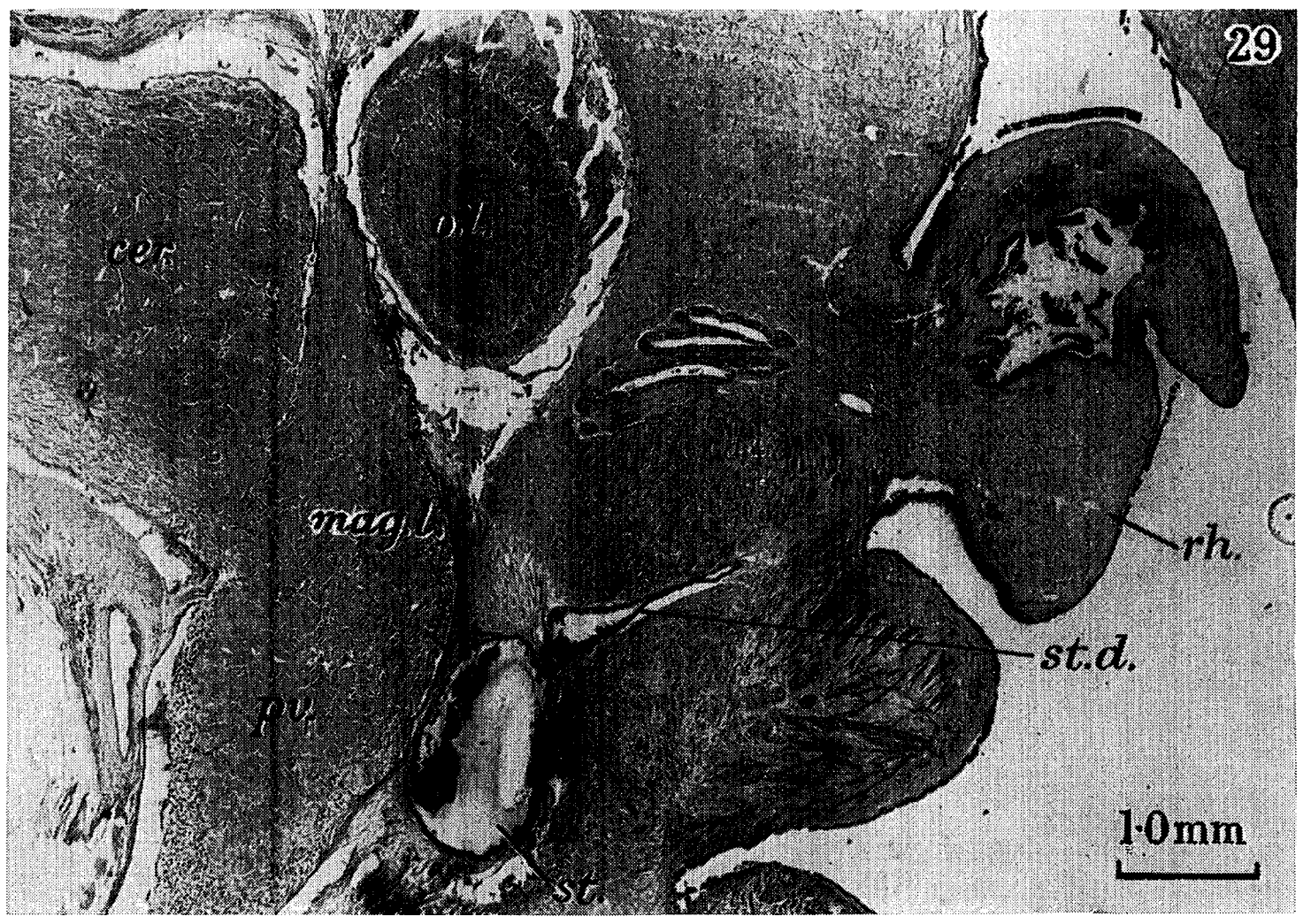
29
cer.
o.l.
mag.l.
pv.
st.
rh.
st.d.
1·0mm

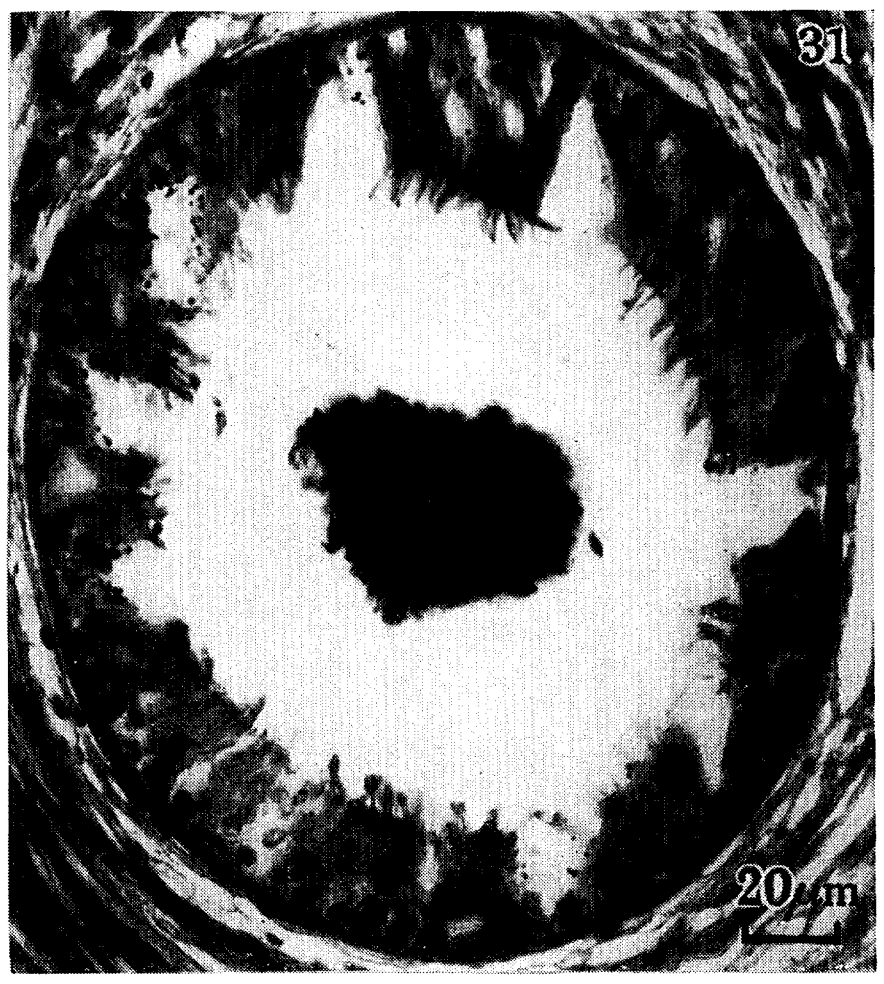
31
20μm

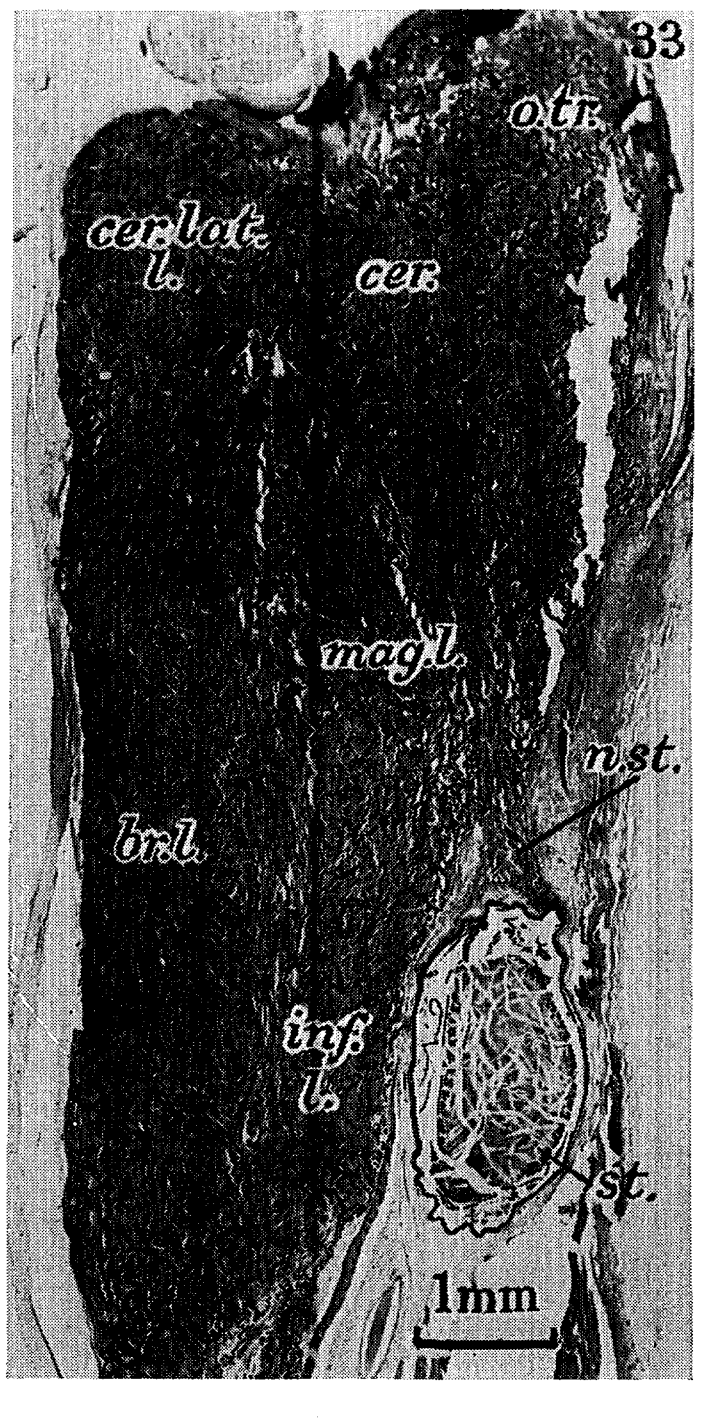
33
o.tr.
cer.lat.l.
cer.
mag.l.
n.st.
br.l.
inf. l.
st.
1mm

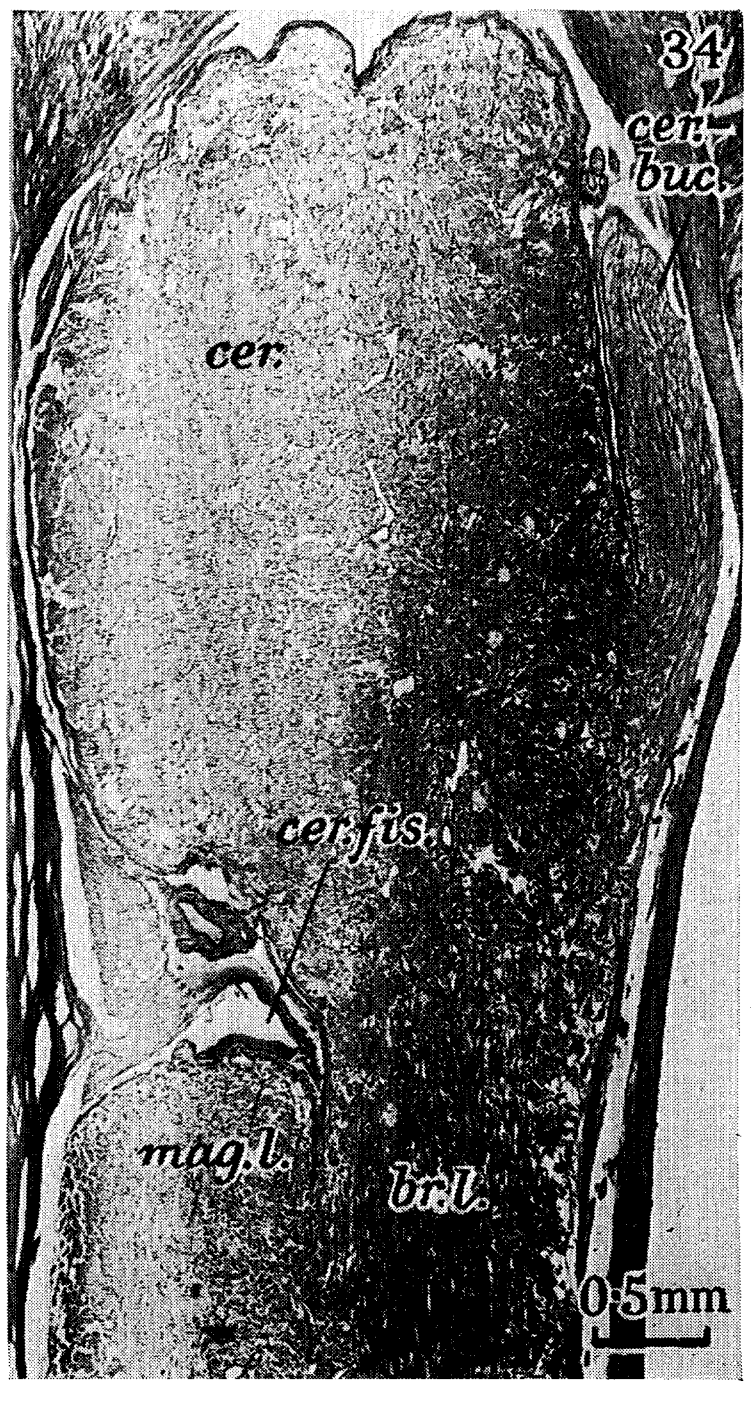
34
cer.buc.
cer.
cer.fis.
mag.l.
br.l.
0·5mm

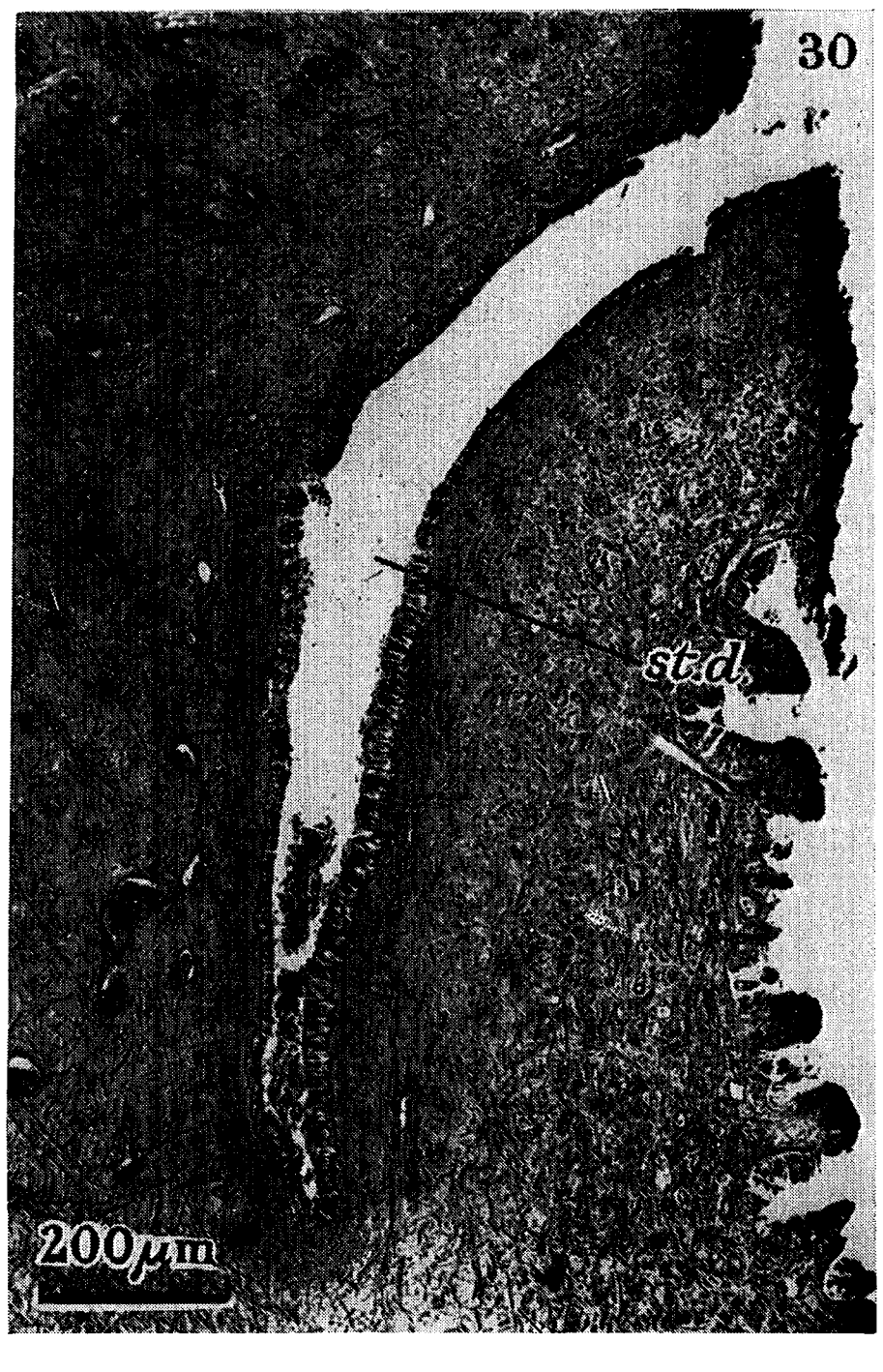
30
st.d.
200μm

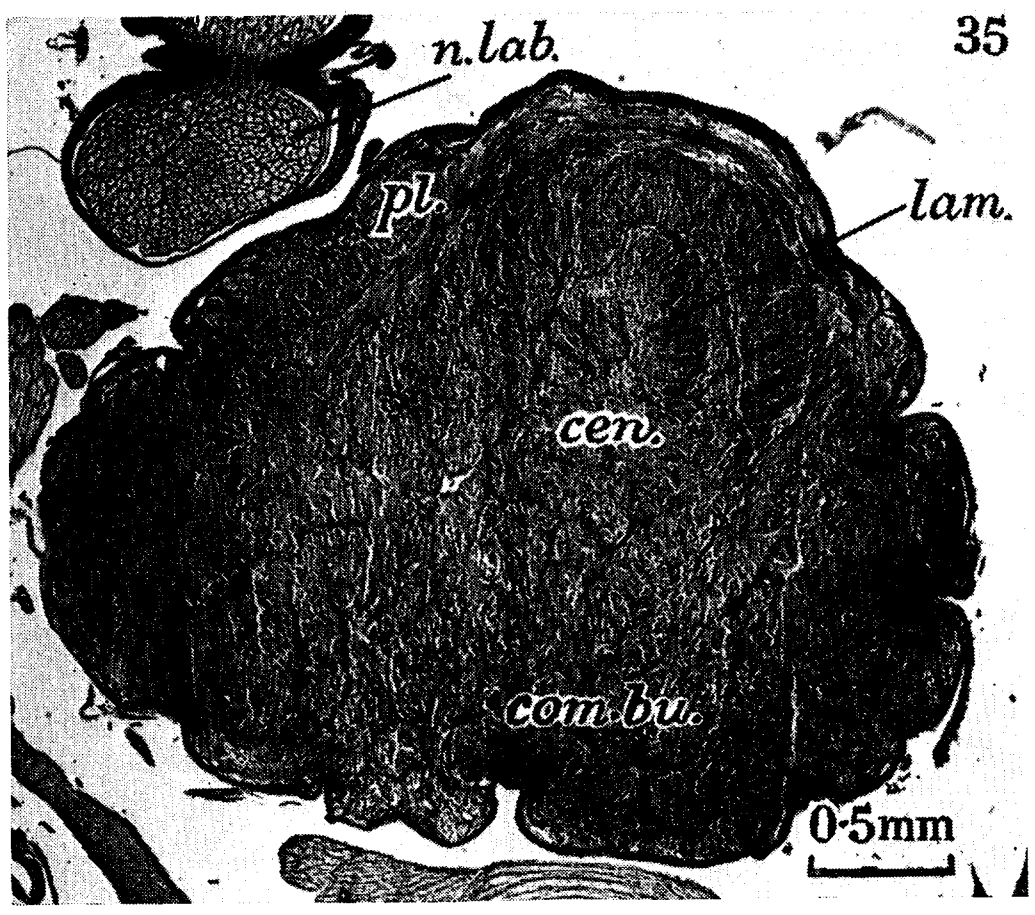
35
n.lab.
pl.
lam.
cen.
com.bu.
0·5mm

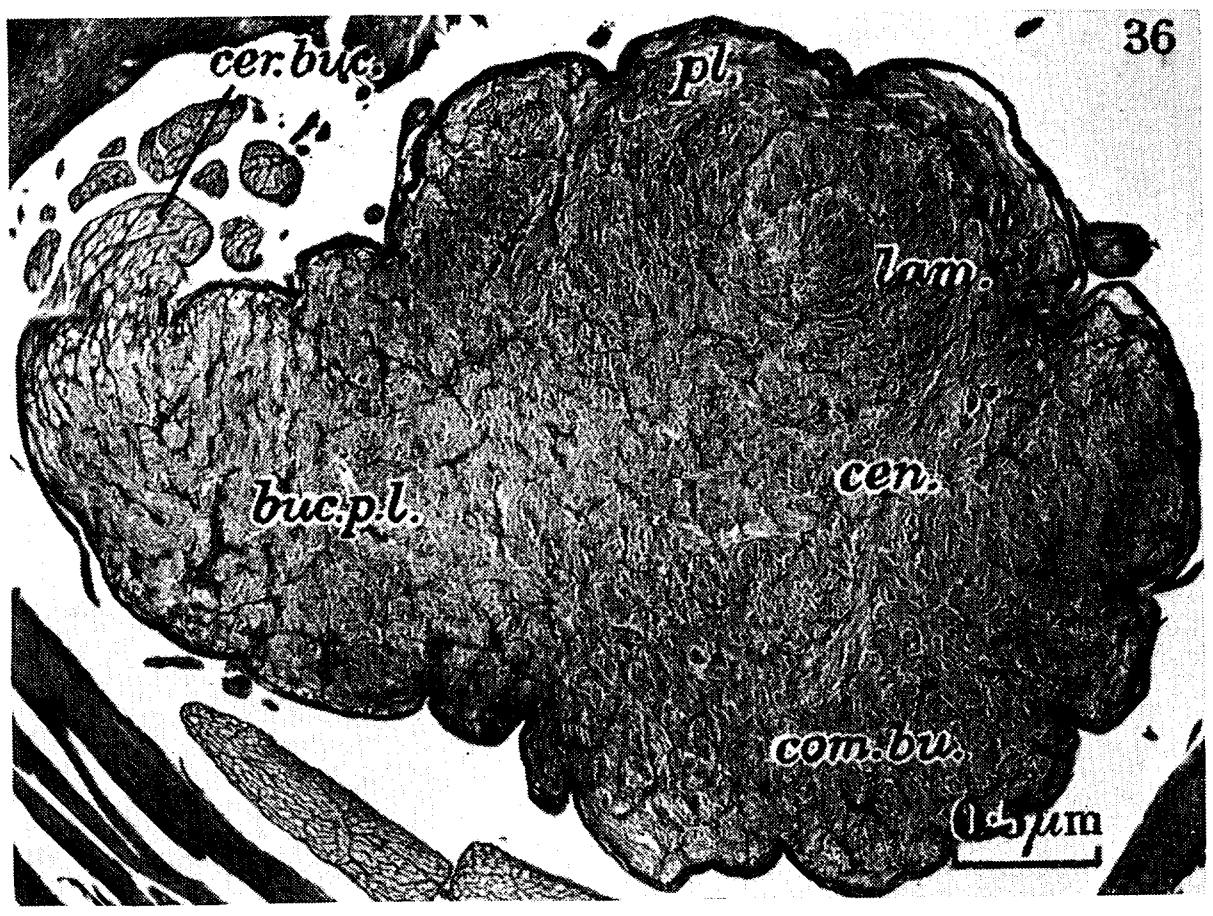
36
cer.buc.
pl.
lam.
buc.p.l.
cen.
com.bu.
0·5μm

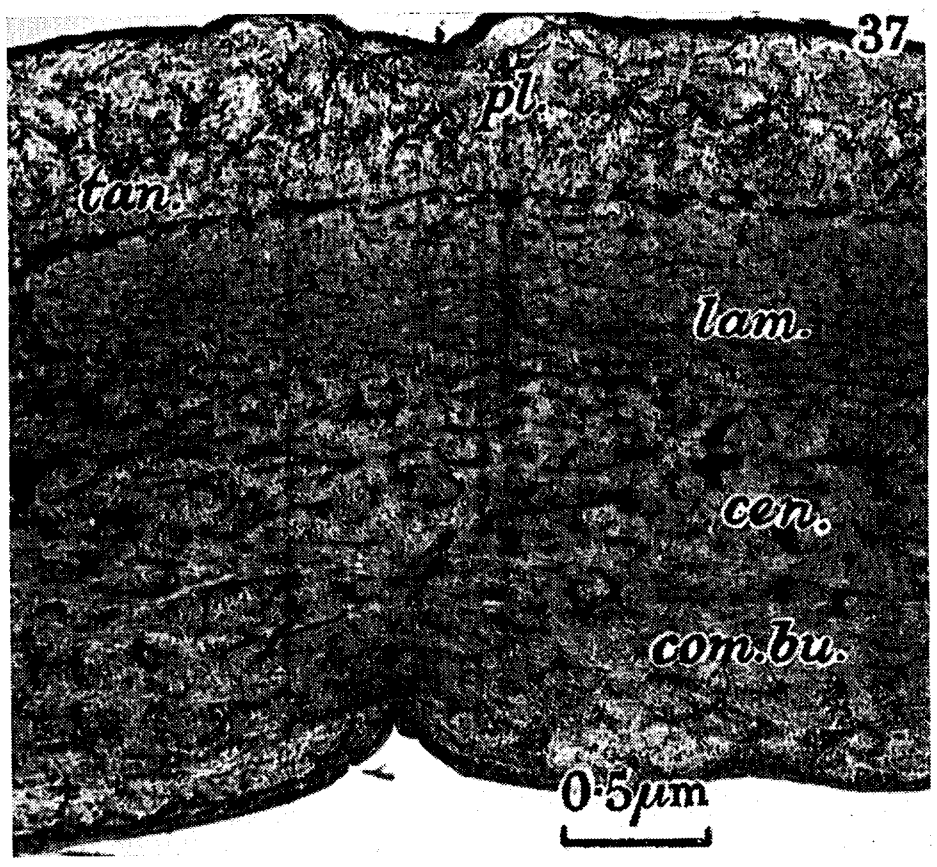
37
pl.
tan.
lam.
cen.
com.bu.
0·5μm


100μm
39


50μm
40

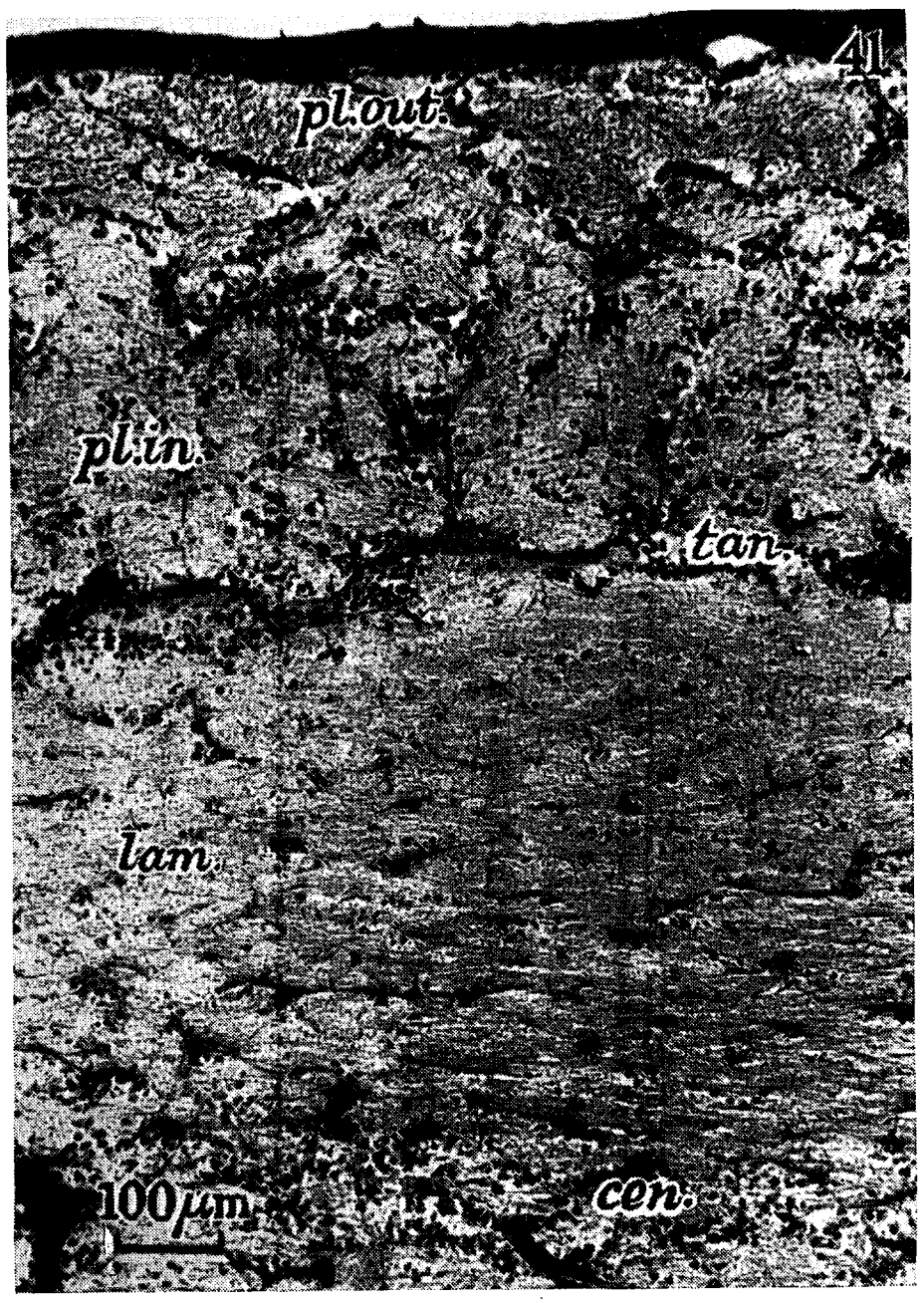
41
pl.out.
pl.in.
tan.
lam.
100μm
cen.

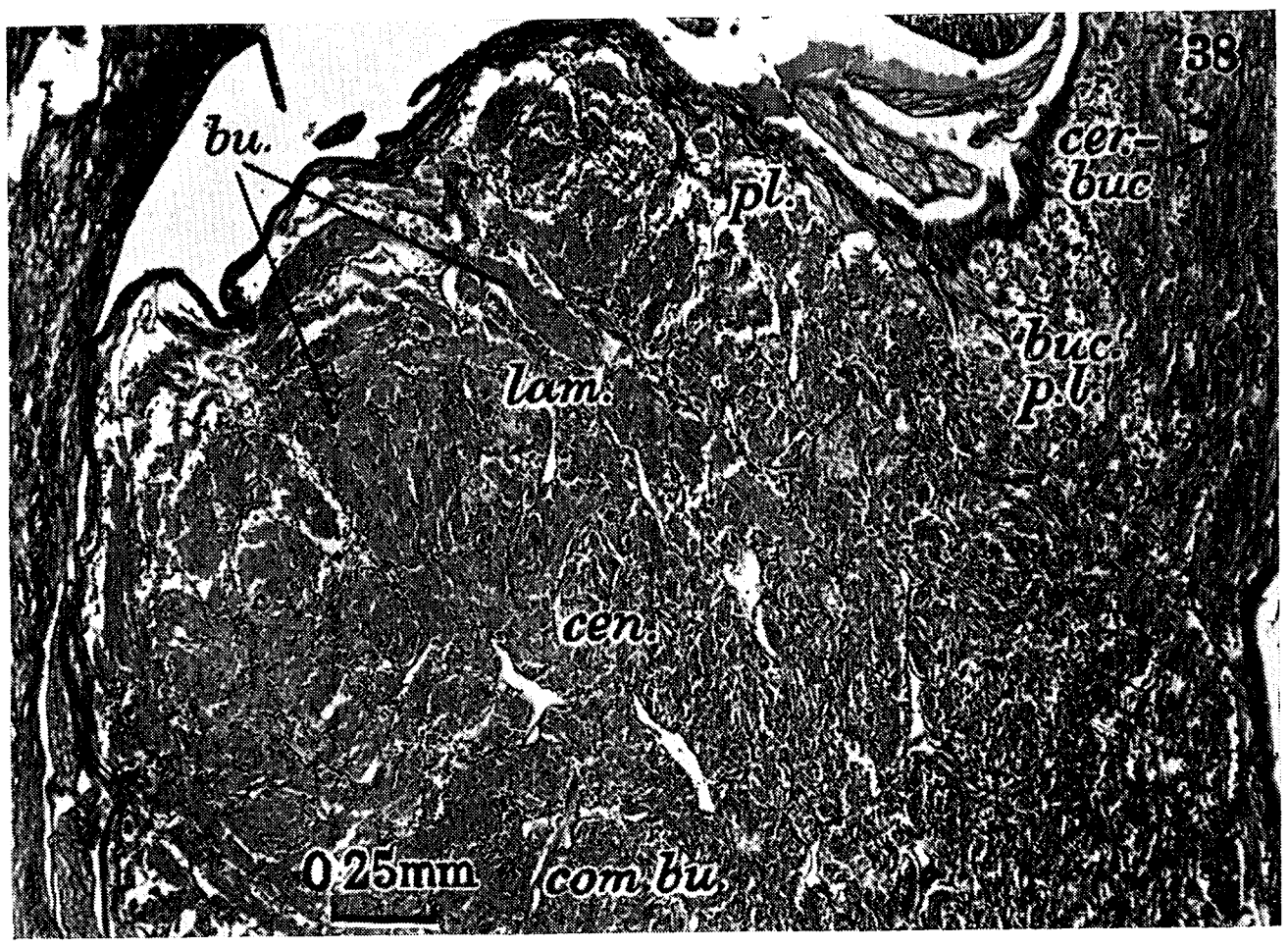
38
bu.
pl.
cer-buc
buc.p.l.
lam.
cen.
0·25mm
com.bu.

PLATE 4

FIGURE 35. Sagittal section of cerebral cord near to mid-line.

FIGURE 36. Sagittal section of cerebral cord laterally showing origin of medial cerebro-buccal connective from the posterior buccal region.

FIGURE 37. Transverse section through the centre of the cerebral cord, showing the four main regions.

FIGURE 38. Sagittal section through lateral part of the cerebral cord, showing the posterior buccal region.

FIGURES 39 AND 40. Sagittal sections showing the arrangement of the cells and the cell composition of the posterior buccal region.

FIGURE 41. Transverse section of the laminated and plexiform zones.

Plate 5

Figure 42. Sagittal section of ventral part of the cerebral cord near the mid-line. Showing bundles of fibres (*bu.*) proceeding from the plexiform zone inwards and downwards.

Figure 43. Sagittal section to show the laminated zone in the ventral region of the cerebral cord.

Figure 44. Sagittal section to show composition of the central zone of the cerebral cord. Islands of neuropil, scattered cells and much connective tissue and blood vessels.

Figure 45. T.S. lateral part of c.n.s. to show the position of the lateral cerebral lobe.

Figure 46. T.S. of lateral cerebral lobe to show fibres reaching it directly from the brachial nerves.

Figure 47. Sagittal section to show interweaving bundles of fibres among the cells of the lateral cerebral lobe.

Figure 48. T.S. lateral cerebral lobe showing bundles of fibres running from it to the plexiform zone of the cerebral cord.

Figure 49. T.S. of extreme hind border of cerebral cord to show the nerves called ophthalmic running behind it.

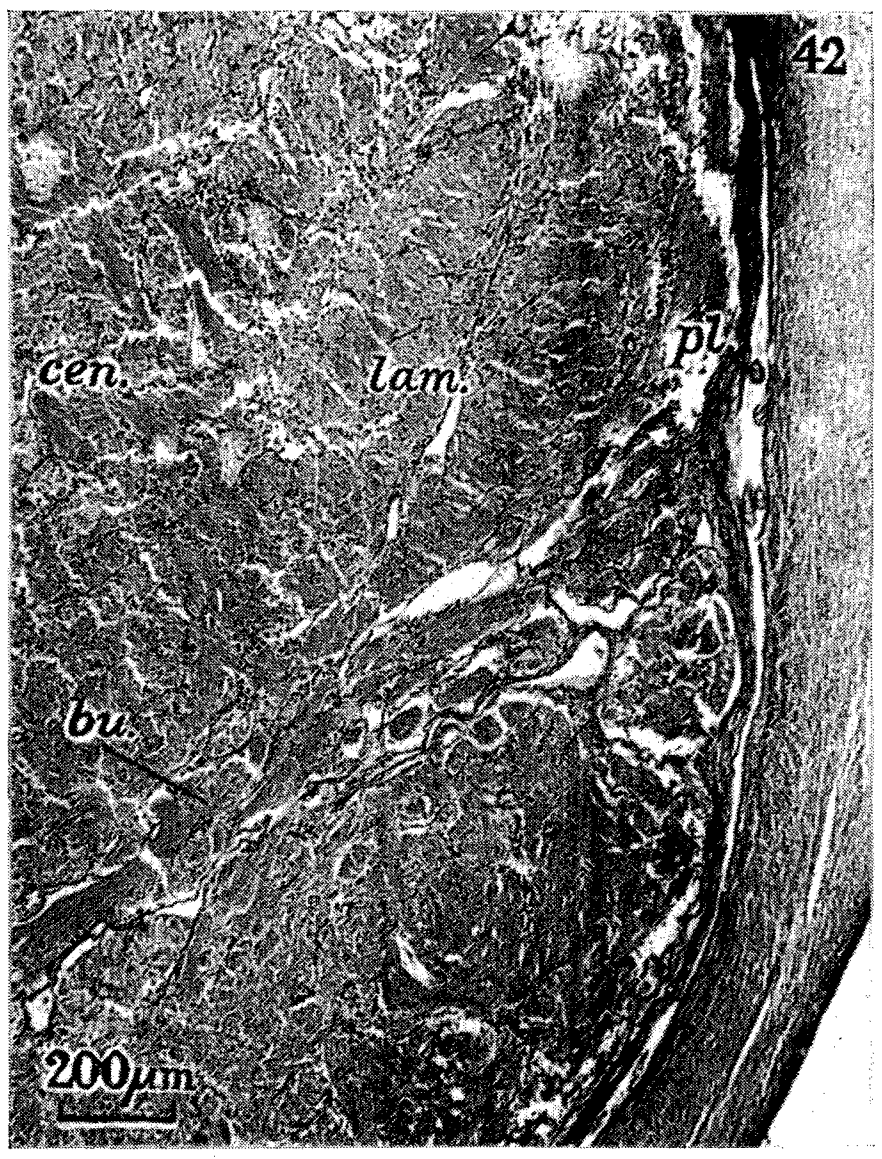
42
cen.
lam.
pl.
bu.
200μm

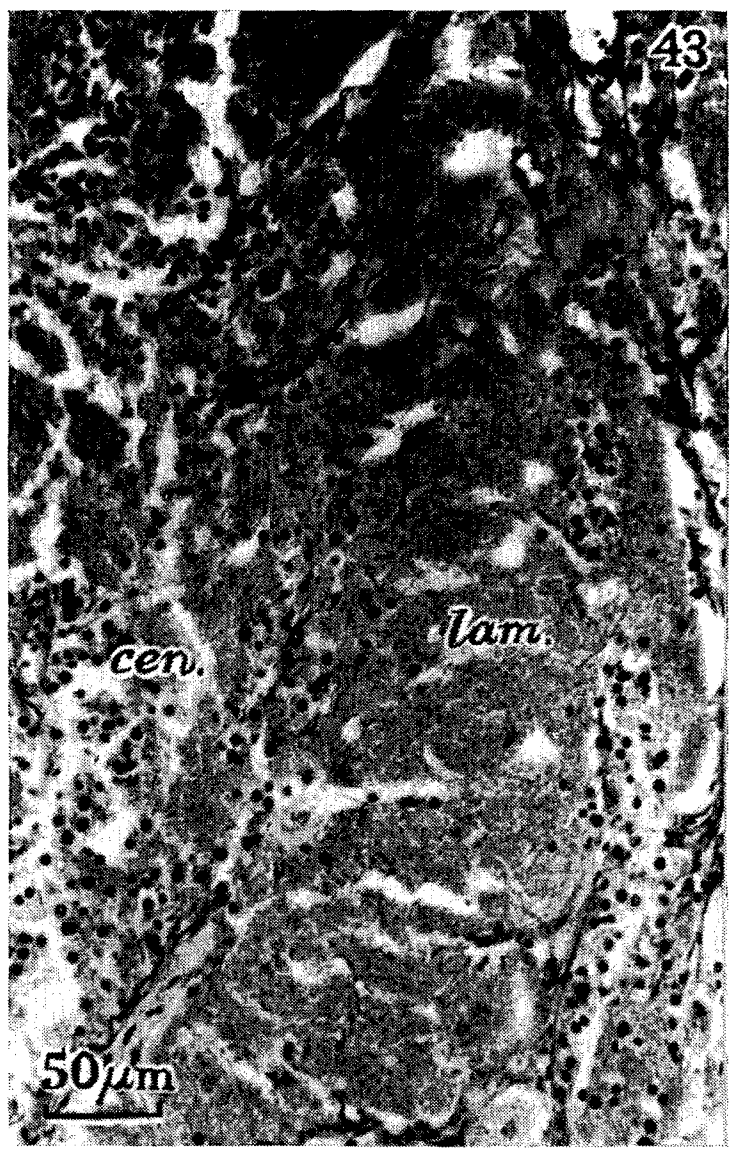
43
cen.
lam.
50μm

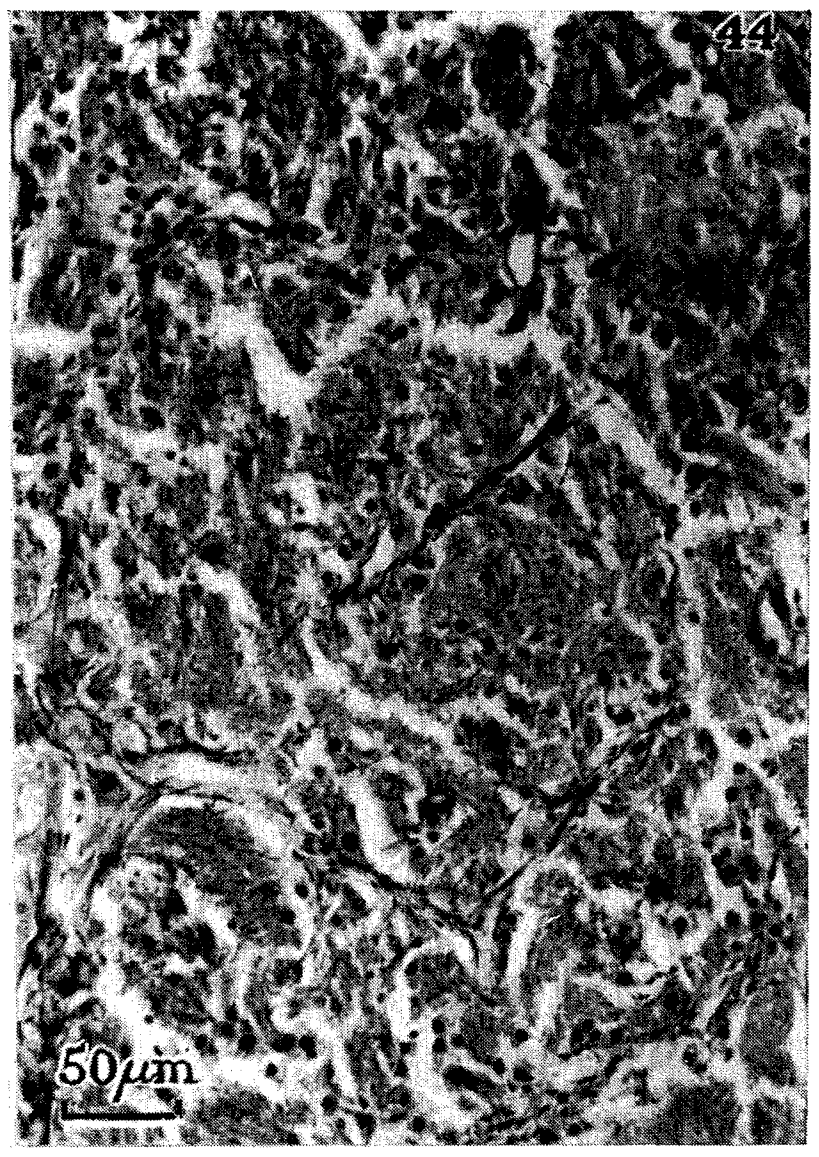
44
50μm

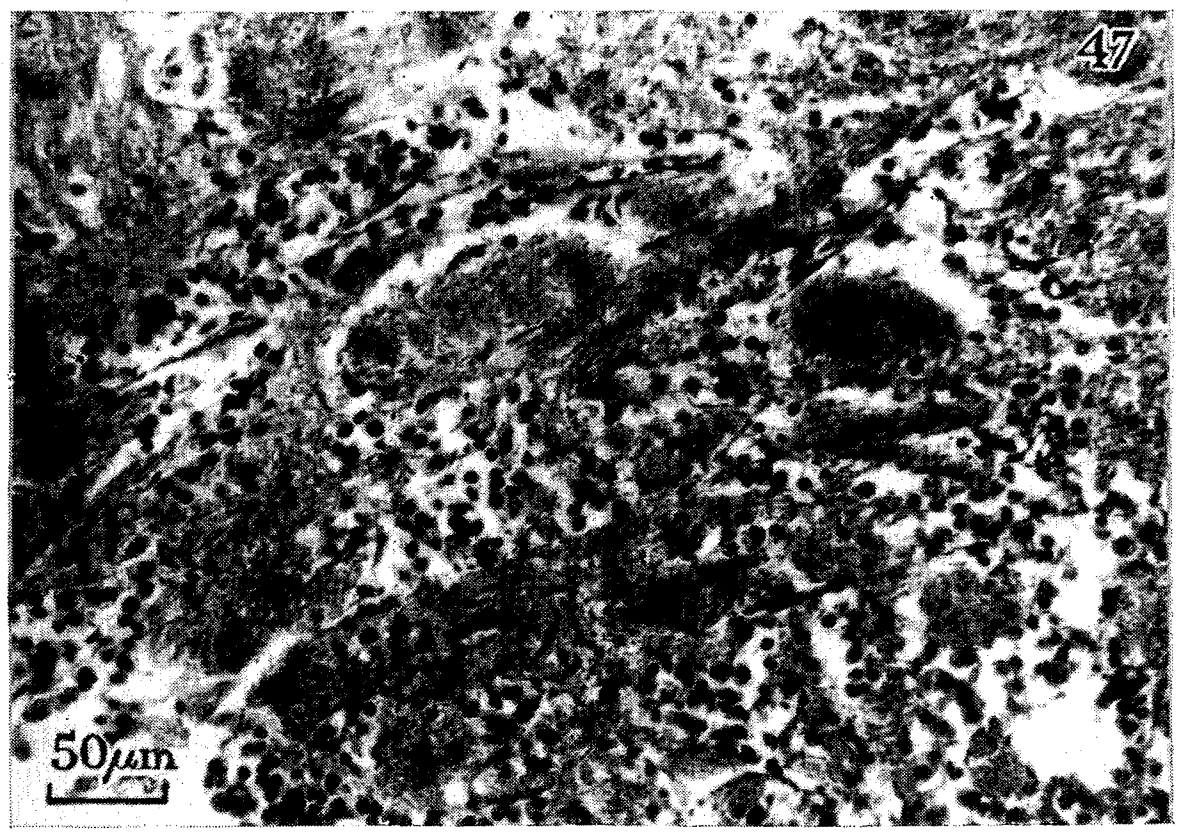
47
50μm

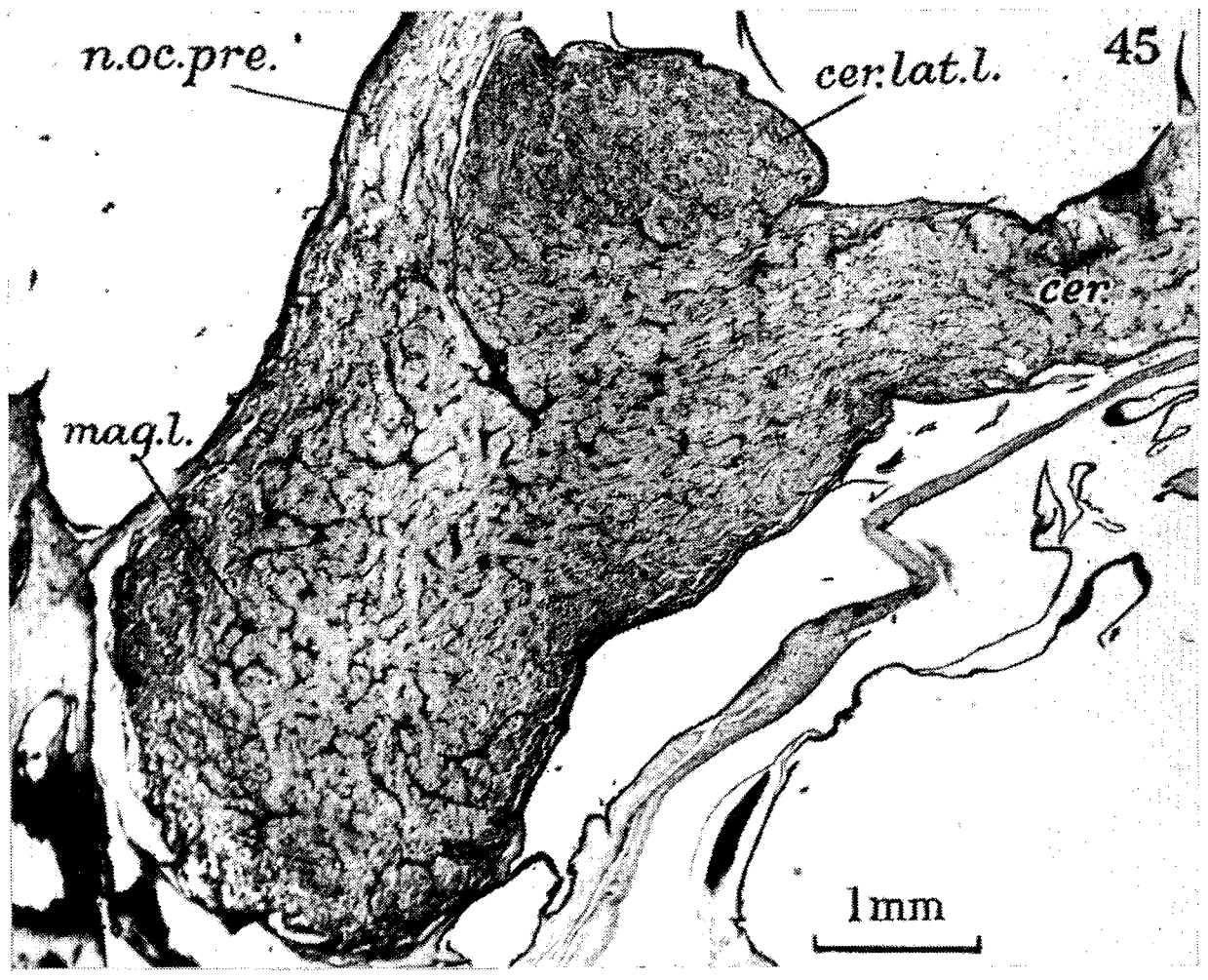
n.oc.pre.
cer.lat.l.
45
cer.
mag.l.
1mm

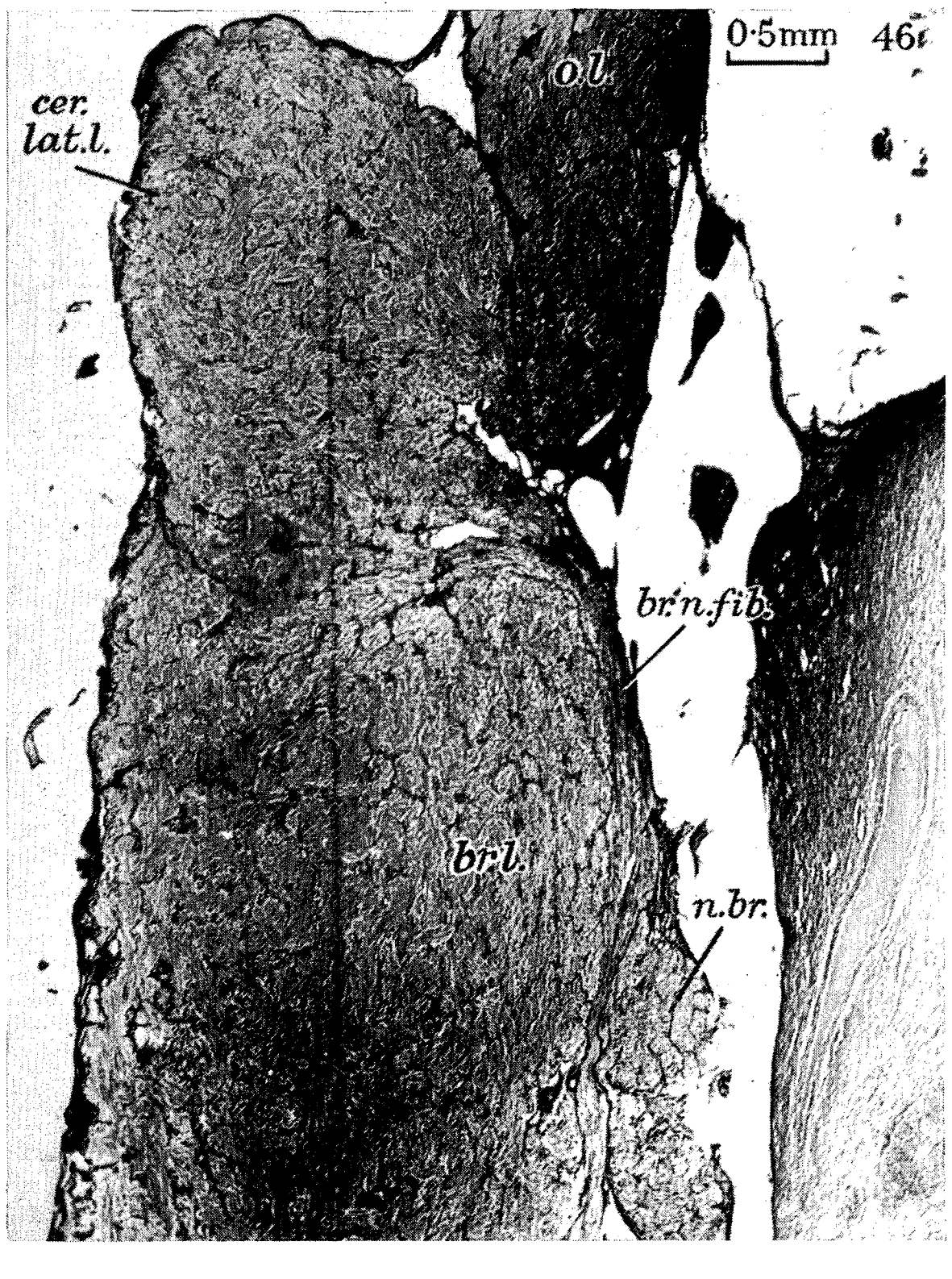
0·5mm
46
cer. lat.l.
o.l.
br.n.fib.
br.l.
n.br.

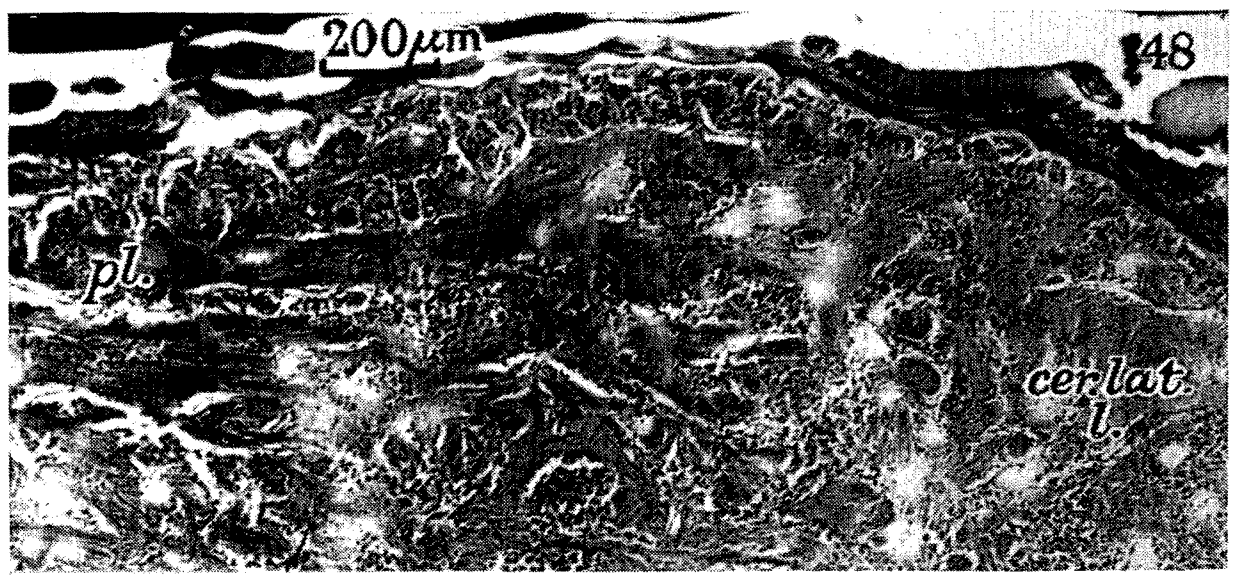
200μm
48
pl.
cer.lat. l.

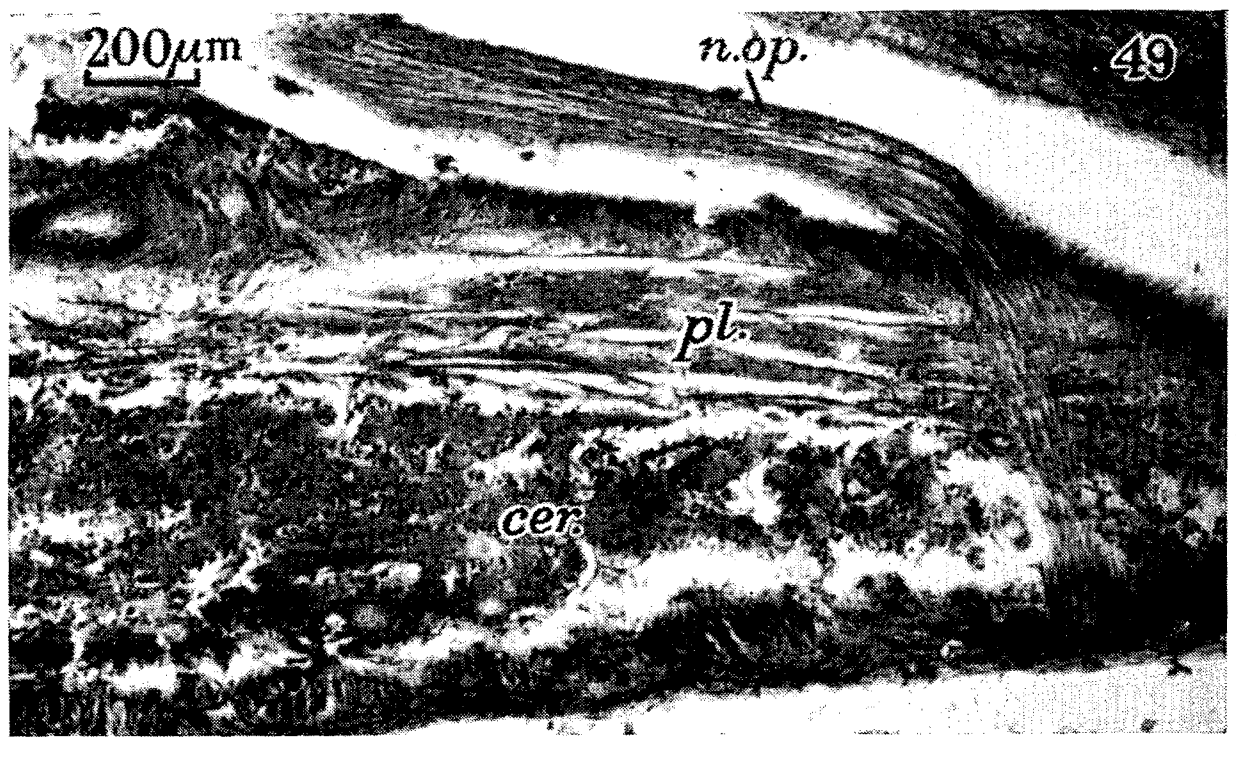
200μm
n.op.
49
pl.
cer.


50
n.o.
ol.
olf.g.
cer.
rh.
olf.l.
n.olf.
1mm

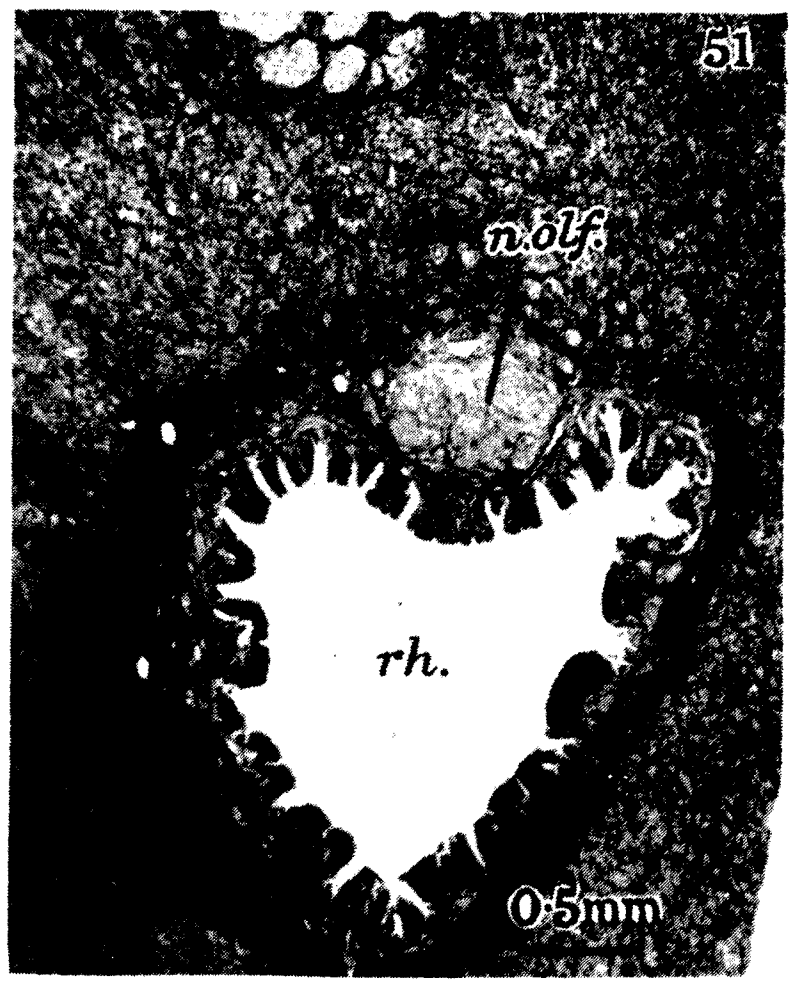
51
n.olf.
rh.
0·5mm


10μm
52
Zc


53
Zc
cil.
10μm


50μm
54
olf.g.

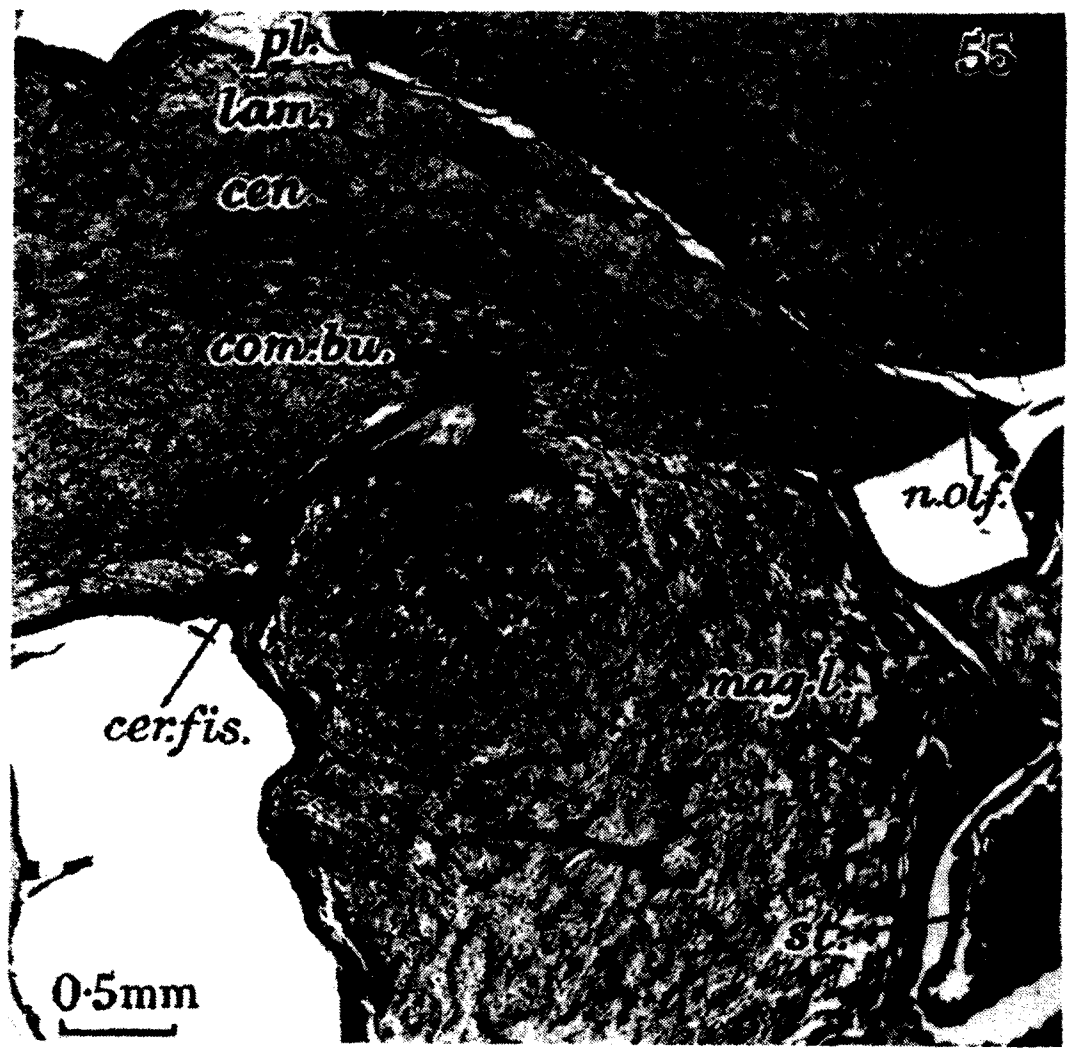
55
pl.
lam.
cen.
com.bu.
n.olf.
cer.fis.
mag.l.
st.
0·5mm


200μm
56
o.gl.?


57
ic.

PLATE 6

FIGURE 50. T.S. showing the cavity of the rhinophore and the olfactory nerve and lobe. Also the optic lobe and optic nerves and the meeting of the olfactory and optic pathways at the sides of the cerebral cord.

FIGURE 51. Sagittal section to show the rhinophore and olfactory nerve.

FIGURES 52 AND 53. Cells of the lining of the rhinophore cavity (sagittal).

FIGURE 54. Lining epithelium of the rhinophore sac with the underlying bundles of olfactory nerve fibres and nerve cells.

FIGURE 55. T.S. olfactory lobe.

FIGURE 56. T.S. showing the region at the median dorsal edge of the optic lobe where there are large cells that may represent the optic gland of later forms.

FIGURE 57. The large 'optic gland' cells.

PLATE 7

FIGURE 58. T.S. optic lobe and optic nerves.

FIGURE 59. T.S. point of union of optic lobe and cerebral cord.

FIGURE 60. Oblique horizontal section to show relation of optic lobe to cerebral cord.

FIGURE 61. T.S. outer part of optic lobe.

FIGURE 62. T.S. plexiform zone and tangential cell layer of optic lobe.

FIGURE 63. T.S. to show fibres running between centre of the optic lobe and plexiform layer of the cerebral cord.

FIGURE 64. T.S. to show fibres running between centre of optic lobe and magnocellular lobe.

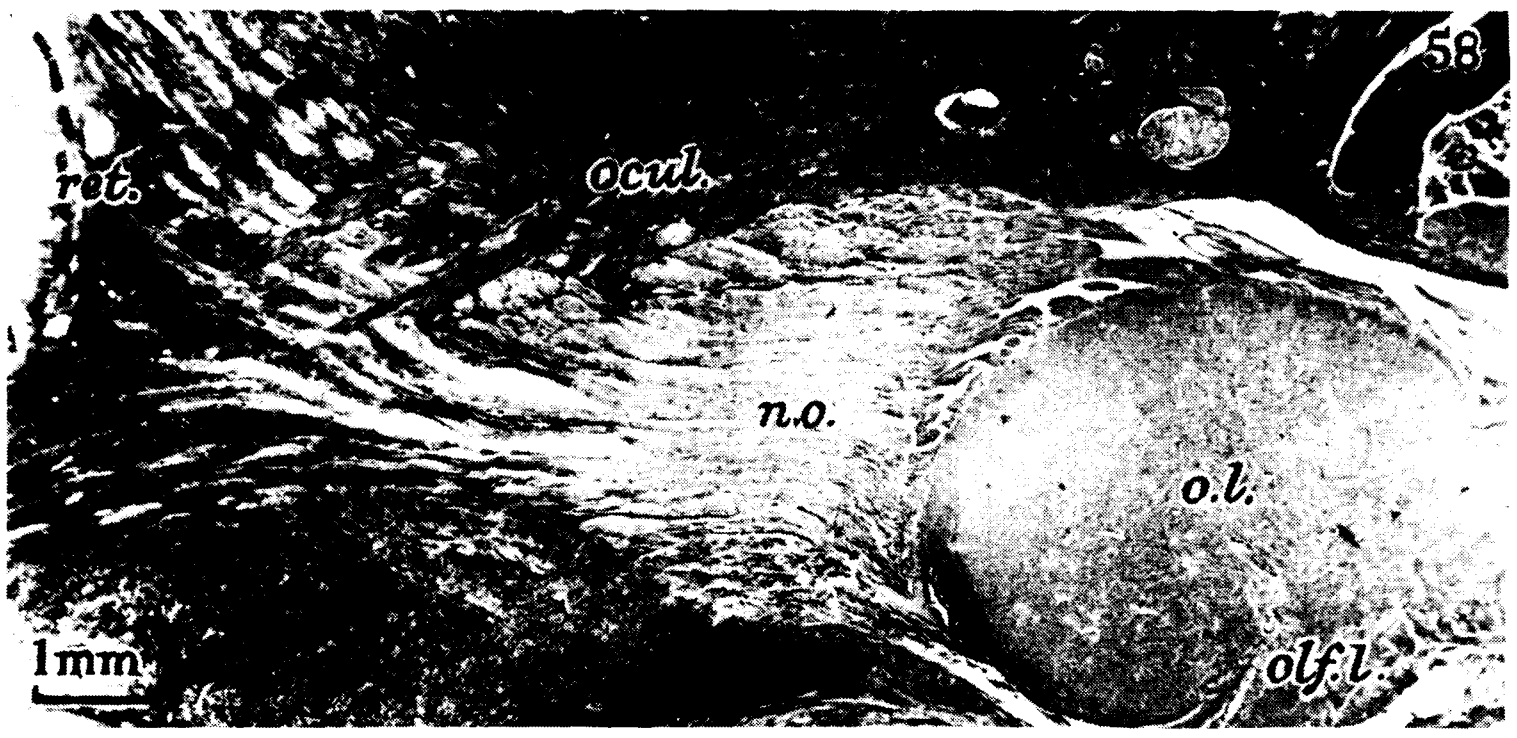
58
ret.
ocul.
n.o.
o.l.
olf.l.
1mm

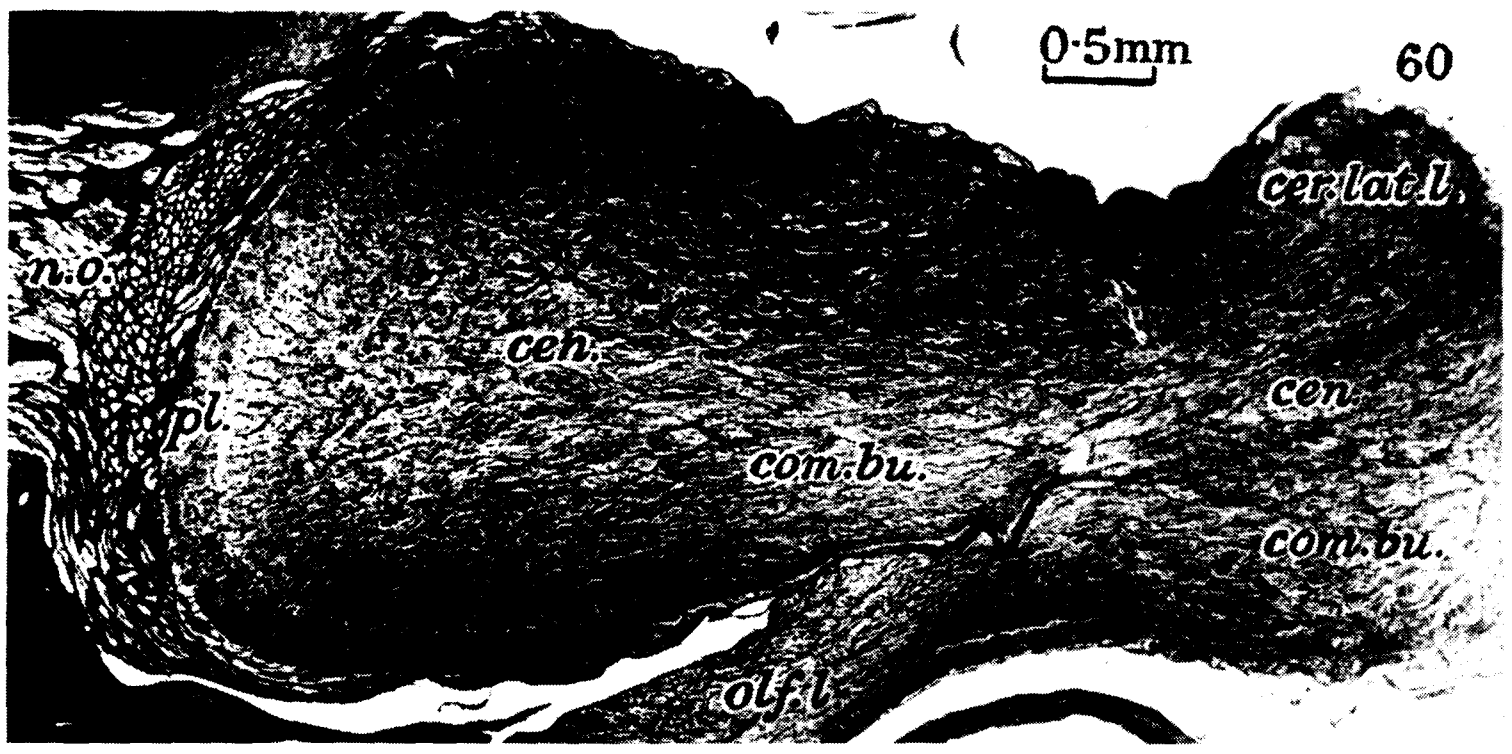
0·5mm
60
cer.lat.l.
n.o.
cen.
pl.
cen.
com.bu.
com.bu.
olf.l.


200µm
59
pl.
tan.
lam.
pl.
cen.
lam.


200µm
63
o.l.
cen.
pl.


61
pl.
tan.
lam.
100µm
cen.


62
n.o.
pl.
tan.
lam.
50µm


64
o.l.
olf.l.
mag.l.
400µm

cells and no nerves arise from it. The nerves to the tentacles all arise from the antero-lateral borders of the main lateral masses. The nerves to the funnel spring from the posterior surface of the ventral edge of the main mass. Sagittal sections show that the part of the mass from which the funnel nerves arise lies behind the part that gives rise to the brachial nerves (figure 5 and figure 15, plate 1; figure 21, plate 2). Though the two parts are contiguous and exchange fibres, the infundibular part is clearly continuous with the magnocellular region. The more anterior, brachial part is continuous with the front part of the supraoesophageal cord (figure 15, plate 1). The boundary between the two parts is not marked by any fibrous septum but is nevertheless usually distinct (figure 19, plate 2). The infundibular and magnocellular parts contain some cells up to 30 μm in diameter, larger than those in the brachial portion. Conversely the latter contains more numerous small cells.

In the lower portion of the anterior suboesophageal mass the cells are mostly arranged as a cortical layer (figure 16, plate 1). Individually the largest of these are similar in size to those of the posterior cord, but the layers of cells are mostly thinner. At this level there are few small cells and few islands of cells at the centre of the cord. More dorsally both the brachial and infundibular parts of the anterior cord come to consist of bundles of fibres running dorso-ventrally, with islands of cells among them but no peripheral layer of large cells (figure 19, plate 2). The infundibular portion thus gives the impression of a motor region of large cells, and the brachial portion seems to consist of islands of large and small nerve cells and neuropil, with interweaving bundles of fibres.

The brachial portion is completely continuous with the antero-lateral portion of the supraoesophageal cord. Some bundles run directly from the brachial nerves to the lateral cerebral (supraoesophageal) lobes, without any break (figure 18, plate 1). These direct pathways from the tentacles to supraoesophageal centres confirm the 'cephalic' nature of the tentacles.

The dorso-lateral region of the brachial portion of the cord gives rise to large nerves that spread out dorsally and innervate the hood (figure 20, plate 2 and figures 2 and 4). These nerves arise from a portion of the tissue that is in no way differentiated from that giving origin to the nerves of the tentacles. Moreover, the outermost two pairs of tentacles actually arise from the tissue of the cephalic shield (figure 1). These tentacles are used in a somewhat different manner from the rest (Bidder 1962). However, their structure is not obviously different from that of the other tentacles and it is difficult not to regard all as a single set. The fact that some of the tentacles arise from the cephalic shield and are innervated with it involves either including the shield as part of the foot or rejecting the 'pedal' nature of the tentacles.

The structure of the upper anterior part of the anterior cord closely resembles that of the lateral cerebral lobe, with which it is continuous (figure 5 and figure 17, plate 1). Over the anterior face there are thin cell layers, containing medium and small cells. The centre of the cord is occupied by bundles of fibres and islands of neuropil and cells, essentially as in the lateral cerebral lobes, except that there is somewhat less interweaving. This structure is quite different from that of the lower motor centres of the palliovisceral and lower part of the anterior suboesophageal cord. This strongly confirms the view that the anterior part of the anterior suboesophageal mass, from which the arm nerves arise, consists of tissue of 'cerebral' nature, extending down in front of the more strictly 'pedal' tissue of the infundibular lobe (figure 21, plate 2).

The paired inferior labial lobes of the female each carries a row of tentacles. They are joined in the mid-line to form a tubular organ, which may be a receptor. This organ is larger in the male (van der Hoeven's organ). Like the more lateral superior labial lobes, and the spadix the inferior labial lobes are innervated from the anterior suboesophageal cord (figure 1).

The nerve to each arm is really a ganglionated cord, containing nerve cells at the periphery (Griffin 1900; Fernandez 1907). These are said to be more numerous opposite each of the adhesive plates of the tentacles. The nerves of the superior and inferior labial lobes also carry ganglia.

MAGNOCELLULAR LOBE

In sagittal sections this lobe is seen immediately lateral to the union of the three main cords. It lies in front of the statocyst and static nerve and receives the upper end of the infundibular part of the anterior suboesophageal lobe (figure 21, plate 2).

The lobe here contains an irregular row of large rounded cells (50 μm diameter, nuclei 10 μm) lying medially in front of the statocyst and static nerves (figure 5, and figure 22, plate 2). The rest of the lobe consists of bundles of fibres and islands of medium and small cells, much as in the upper part of the anterior and posterior suboesophageal cords.

The lobe continues upwards and laterally, between the lateral cerebral lobe in front and the optic lobe behind until it gives off the nerves to the two ocular tentacles (figure 23, plate 2). These nerves, like the brachial nerves, are really ganglionated cords, with nerve cells round their circumference and within them (figure 26, plate 2). The origin of the nerves for the ocular tentacles from the upper end of the pedal lobes is essentially as described by Willey (1902), but this region is now identified as the magnocellular lobe.

In transverse section at its anterior end the magnocellular lobe is not sharply marked off from the brachial portion of the anterior cord. Yet the two have distinct internal composition, the brachial consisting of islands of medium and small cells and the magnocellular mainly of neuropil with an outer posterior wall of large cells.

Behind the level at which the brachial lobe appears in transverse section as a separate cord at the side of the cerebral cord, the magnocellular lobe also appears separately at the side of the cerebral cord (figure 24, plate 2). At its narrowest region, behind the origin of the nerves to the cephalic tentacles, it is completely isolated dorsally by the cerebral fissure (figure 24). Slightly more posteriorly it communicates dorsally with the cerebral cord and ventrally with the palliovisceral cord (figure 25, plate 2). In the narrowest part the magnocellular lobe is expanded laterally into a small extension that receives the static nerves.

THE STATOCYST AND STATIC NERVES

Each statocyst, first described by Macdonald (1855), is a sack with a single undivided cavity, communicating with the exterior by a canal (Kölliker's canal). This seems to be the first demonstration that the canal remains open in the adult *Nautilus*. Macdonald

(1857) refers to the fact that the cavity of the 'subocular process...may be traced downwards...to within about the twentieth of an inch of the auditory capsule.' But the cavity that he refers to is clearly that of the olfactory organ. The cavity of the statocyst is almost completely filled by a calcareous otolith, formed by small particles aggregated into a single mass (Griffin 1897).

Seen in transverse section the statocyst is an oval sack (2 × 1·25 mm in one specimen). The long axis lies at approximately 45° to the horizontal plane of the animal, with the lateral end higher than the medial (figure 23, plate 2). In sagittal section the sack also appears oval and of about the same dimensions (2·5 × 1·5 mm, in another specimen) (figure 15, plate 1 and figure 21, plate 2). The long axis is nearly vertical in this plane, but in some specimens appears at a slight angle, with the upper end more posterior. In some specimens the upper end is narrower than the lower, giving a pear-shape.

The sack is enclosed within the fibrous sheath of the nervous system, which divides around it. The sack cannot therefore move relative to the animal as a whole. Further, the otoliths nearly fill the cavity in sections (figure 28, plate 3), and probably do so completely in life. However, the nature of the otolith mass is obscure. It is composed of discrete particles. They are spindle-shaped with the axes variously orientated and, sometimes stain deeply with haematoxylin (figure 28). In some preparations there is a layer of material near the periphery that is orientated tangentially.

The lining of the cavity contains receptor cells around its entire circumference. These are large cells with their ends projecting towards the lumen and upwards (figures 27 and 28, plate 3). Their bases are prolonged into nerve fibres, which also proceed upwards, round the periphery of the sack. Other cell types are present. No cells identifiable as ganglion cells have been seen but it cannot be altogether concluded that they are absent.

The statocyst thus shows no signs of the differentiation into macula and crista that is so characteristic of coleoids (Young 1960). Any change in the position of the *Nautilus* will presumably alter the distribution of pressure and tension on the receptors.

Kölliker's canal (*st.d.*) proceeds laterally from the hind end of the sack (figure 29, plate 3) and opens at the surface by a small pore at the base of the olfactory tentacle (figure 30, plate 3). The central part of the tube is ciliated and contains spindle-shaped particles similar to those in the main cavity (figure 31, plate 3). The epithelium of the terminal portion is lower than that more centrally and not ciliated.

The static nerves leave as several bundles from the upper surface, towards the hind end (figure 32, plate 3). Where they enter the magnocellular lobe the latter extends laterally as an irregular system of neuropil and large neurons, exactly as in coleoids and especially in decapods (figure 22, plate 2; figure 32, plate 3).

Some of the static nerve fibres turn medially into the magnocellular lobe and from there apparently go to the posterior suboesophageal cord (figure 25; plate 2; figure 33, plate 3). It is not possible to be sure whether they also run to the anterior cord, nor whether there is a static commissure. Other static nerve fibres proceed dorsally in the dorsolateral edge of the magnocellular lobe, between it and the olfactory lobe to enter the central part of the supraoesophageal cord immediately above and behind the cerebral fissure (figure 5, and figure 33, plate 3) (see Griffin 1897).

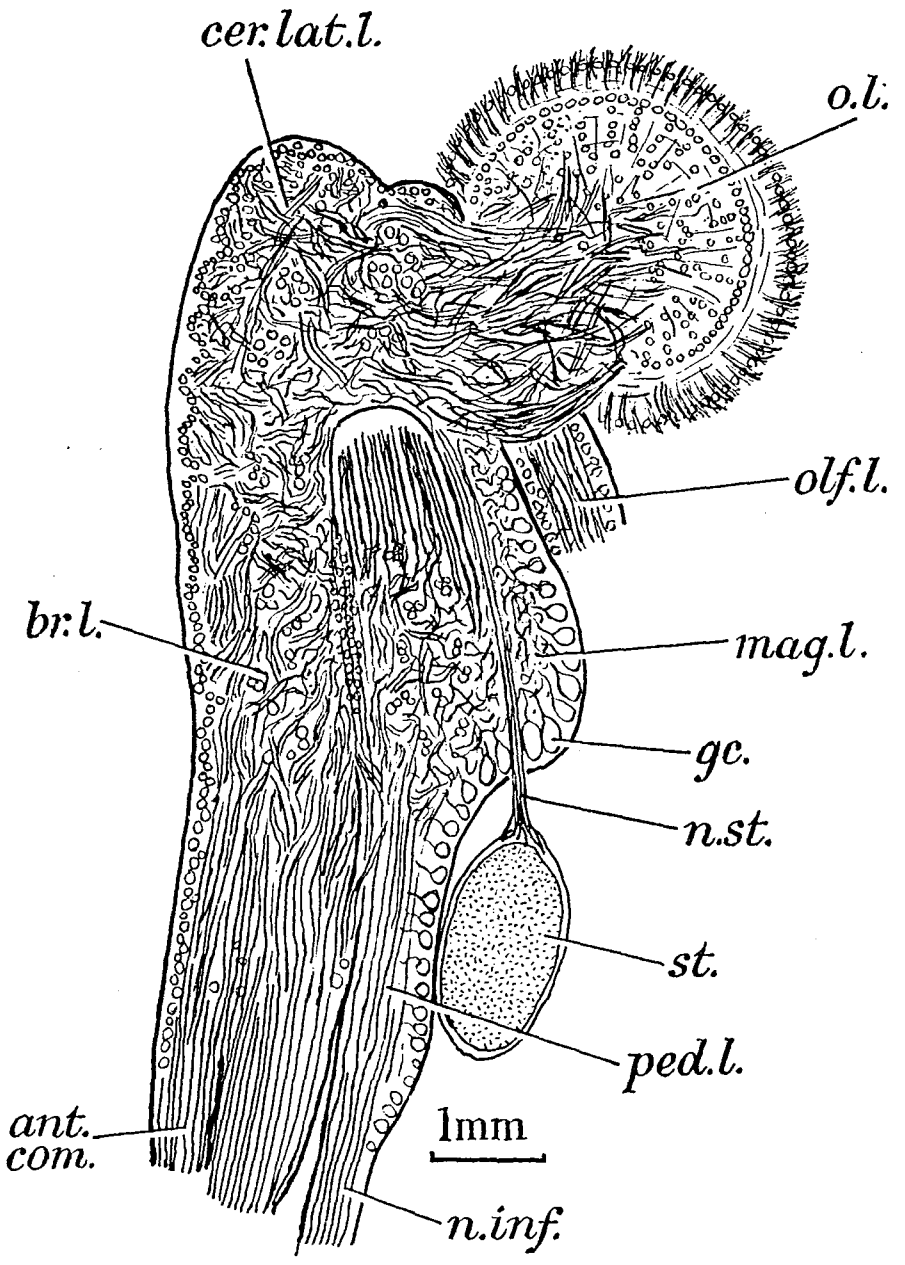

FIGURE 5. Composite drawing of several sagittal sections of lateral portion of central nervous system.

BUCCAL GANGLIA

There are two pairs of large ganglia connected with the buccal mass (figure 1). The superior buccal ganglia (pharyngeal ganglia of Griffin 1900) lie at the sides of the buccal mass. Each receives two cerebro-buccal connectives from the central nervous system. The more lateral of these connectives arises very low down at the side of the supraoesophageal cord (figure 34, plate 3). The more medial connective arises from the main supraoesophageal cord. The two join at the sides of the buccal mass to make a ganglion of irregular star shape (figure 1). From this several nerves run to the powerful muscles that unite the jaws. Large nerves leave the superior buccal ganglia anteriorly for the lower lip. Griffin (1900) called these 'the pharyngeal commissure'. They may contain commissural fibres, but they probably run mainly to the two pairs of prelingual processes in the floor of the mouth and will therefore be called prelingual nerves. It may be that one of the two 'cerebro-buccal' connectives in fact proceeds past the superior buccal ganglion to form these prelingual nerves. If this is so, the apparent double cerebro-buccal connectives would be explained, only the more medial one being a true cerebro-buccal connective. The more lateral, running direct to the lips originated low down on the cerebral cord.

The lower lip consists of an elaborate apparatus with an outer retaining margin and two flat shovel-like plates bearing papillae (the prelingual processes of Griffin (1900)). The nerve sends large branches to these papillae, which are presumably gustatory. It is uncertain whether this nerve also leads to a subradular ganglion. Swellings observed on it perhaps represent this structure. However, these cannot be exactly equivalent to the subradular ganglia of coleoids since the latter innervate the duct of the posterior salivary glands, which are absent from *Nautilus* (Young 1965*a*).

The inter-buccal connectives are short and rather stout bundles running ventrally from the superior to the inferior buccal ganglia. The latter are larger than the superior buccal ganglia and lie at the sides of the oesophagus where it takes origin from the buccal mass (figure 1). Several quite large but rather transparent nerves run from the inferior buccal ganglia to the oesophagus. These are difficult to follow and it remains uncertain whether they run back as 'sympathetic' trunks to a gastric ganglion.

Other nerves run from the inferior buccal ganglion to the median buccal lobe ('tongue' of Griffin (1900)) and to the lateral buccal (salivary) lobes that lie at the sides of them. All these structures are covered with papillae and probably contain gustatory receptors. Note that some confusion can arise with the naming of the buccal structures. The superior, inferior and posterior buccal lobes (the last a division of the cerebral cord) are *nervous structures* whereas the median and lateral buccal lobes are *not* nervous but gustatory. The question of the comparison of the various structures in the buccal cavity of different cephalopods is discussed elsewhere (Young 1965*a*).

The two inferior buccal ganglia are joined by a broad infra-buccal commissure, from which further nerves run forwards to the lateral and medial buccal lobes and probably to the radula. There was no evidence of commissures above the oesophagus connecting either the superior or inferior buccal ganglia, but it is difficult to exclude the possibility that there are fine fibres of this sort.

Cerebral cord

(1) *General organization*

The supraoesophageal (cerebral) cord shows hardly any external signs of division. Near the mid-line it is a strip of tissue about 3·2 mm in diameter antero-posteriorly and rather less dorso-ventrally, 2·5 mm (figure 35, plate 4). It is in communication laterally with the brachial, palliovisceral, magnocelluar, optic and olfactory lobes. Above the union of all these parts it carries a slight swelling, the lateral cerebral lobe. The two pairs of cerebro-buccal connectives arise from the antero-lateral edge of the supraoesophageal cord. At the origins of the more medial of these there are slight swellings which may be called posterior buccal lobes (figure 36, plate 4). Their relations are similar to those of the lobes with this name in coleoids (Young 1965*b*). From the rest of the length of the antero-dorsal face of the cord arise a series of labial nerves (figure 1).

The supraoesophageal cord does not show internal division into the clearly marked lobes that are so characteristic of coleoid cephalopods. However, it is by no means a homogeneous structure. The divisions within it are not sharp, but regions with characteristic differences can be recognized and are of great interest as foreshadowing the differentiation of the brain of higher forms. The parts to be recognized are: (1) the posterior buccal region, (2) a plexiform zone behind this and around the dorsal and posterior parts of the circumference, (3) a laminated zone within this, (4) a central zone in the middle of the cord and (5) a commissural zone antero-ventrally (figures 36 and 37, plate 4). The symmetry of the cord is thus based approximately on a radial plan as seen in sagittal sections, though the arrangement is not regular about a geometrical centre. The plan seems to allow for interweaving and perhaps interaction between fibres from a buccal region in front and from the receptor centres at the sides. This interweaving takes place in the outer part of the cord, the plexiform zone, which occupies the region behind the buccal zone and over the top and back.

Central to the plexiform zone is a laminated zone, easy to recognize in some transverse sections (figure 37). But it lies behind the geometrical centre of the cord and has a curved form in the sagittal plane (figures 35 and 36). It is reasonable to suppose that there are cells here that respond to particular groups of activity in the plexiform zone.

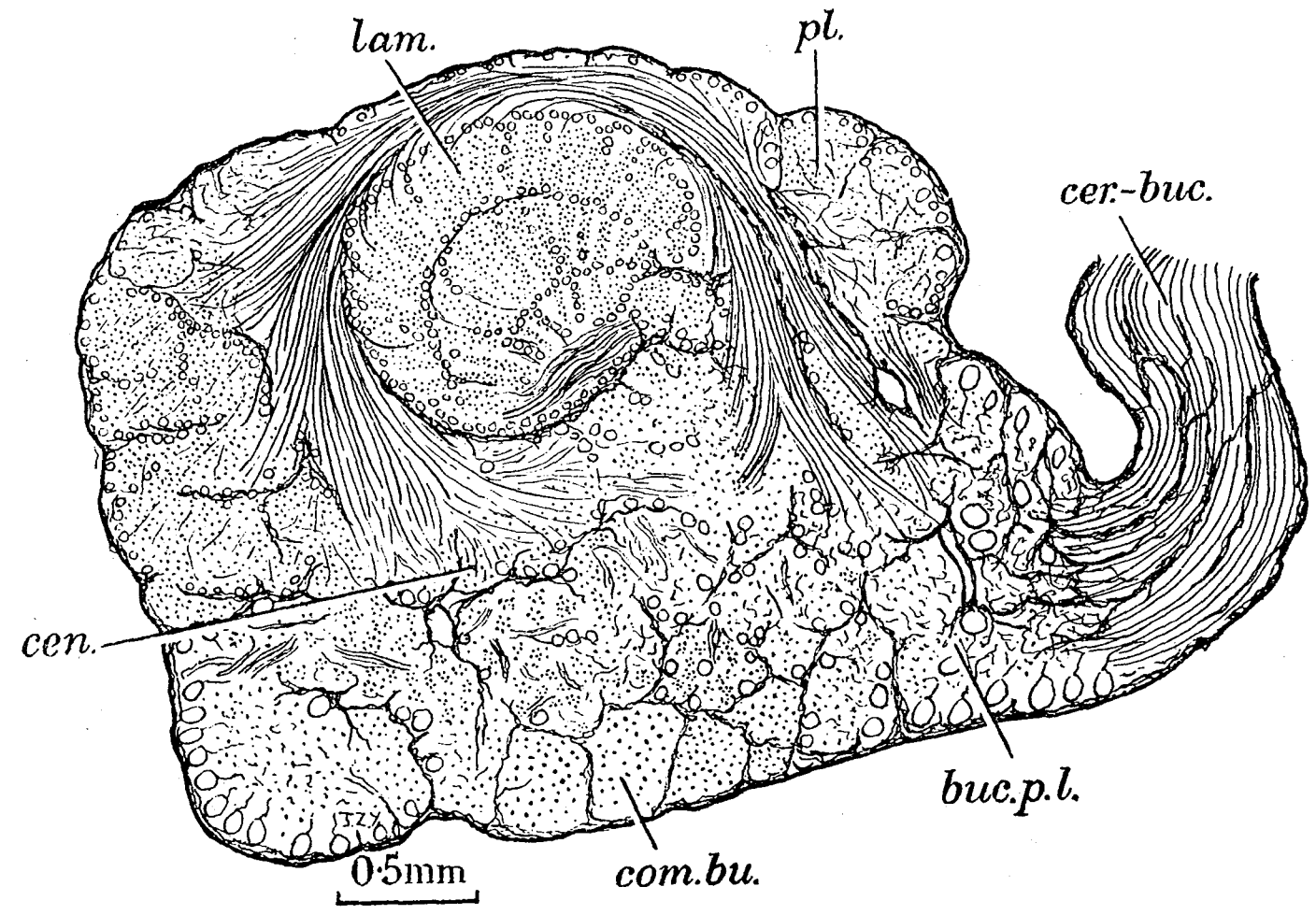

FIGURE 6. Drawing of sagittal section of supraoesophageal cord of *Nautilus*. The cells are all shown larger than they really are.

The central and ventral parts of the cord contain some larger cells and bundles of laterally running fibres. They presumably constitute the output and commissural pathways, leading either back to the receptor centres or down to the suboesophageal or buccal centres. There is obviously a general similarity between this plan and that of the supraoesophageal centres of other cephalopods. A more detailed comparison is made later (p. 22).

It is thus suggested that the cerebral cord constitutes a 'higher centre' allowing the interaction of signals arriving from receptor centres, so that appropriate responses are selected by signals sent to the motor centres. In the absence of experimental evidence it would be most unwise to base the description of the cord on any more precise hypothesis. However, the fact that the only fibres running direct from the cord to the periphery are those that innervate the buccal mass suggests that the specific action of the cerebral cord may be to regulate the processes of eating and the search for food.

Some general hypothesis about the organization is really a necessity for description of this baffling network of fibres, neuropil and neurons. Boundaries are seldom distinct within it and yet several sorts of tissue, with markedly different organization, are present. The terminology used attempts to describe the various types of tissue and their distribution in the different parts of the cerebral cord.

(2) *Buccal region of the cerebral cord*

The anterior part of the cerebral cord contains mainly large cells and here are the roots of the series of nerves that run to the lips and to the superior buccal ganglia (figures 1, 6 and 7; figures 36, 38, plate 4). These nerves probably contain both afferent and efferent fibres and the large cells of this region presumably give rise to motor fibres, controlling the movements of the oral papillae as well as of the buccal mass itself. This may thus be called the posterior buccal region of the supraoesophageal cord. It is particularly well developed at the sides, where the cerebro-buccal connectives arise (p. 12). But it is present over the whole extent of the cord, right to the mid-line.

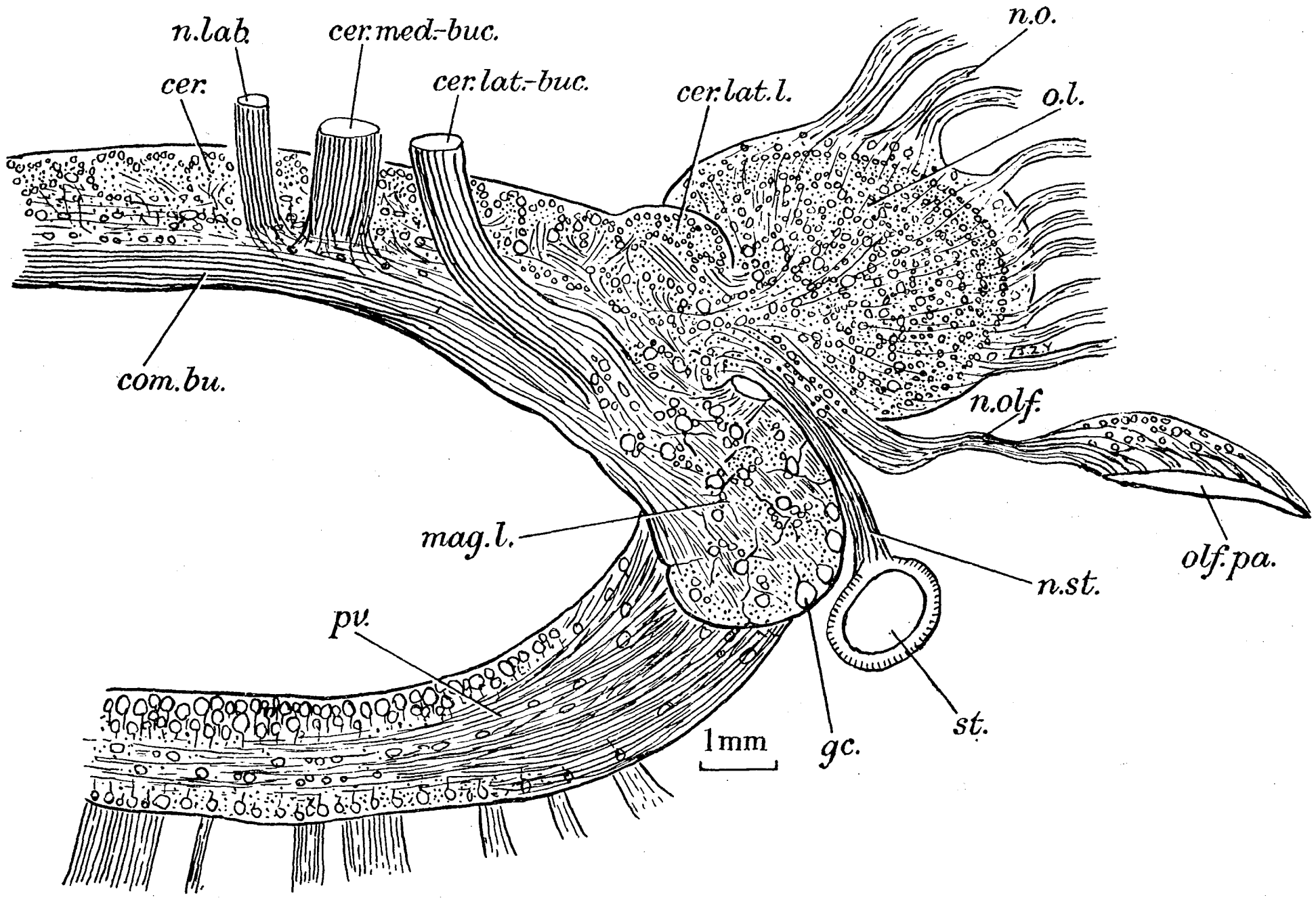

FIGURE 7. Transverse section of the central part of the nervous system of *Nautilus*. Reconstructed by tracing from photographs. The sizes of the nerve cells are shown in correct proportions but are much larger than reality.

The large cells of this buccal region reach up to 30 μm in diameter, nucleus 10 μm (figures 39, 40, plate 4). There are few small cells accompanying these large ones. The cells lie in a moderately regular layer round the edge of the lobe and the neuropil at the centre contains few cell islands. This is therefore a region of 'reflex' or 'motor' type, but its largest cells are smaller than those of the suboesophageal cords.

The large cells extend down the anterior face of the cord in decreasing numbers. Posteriorly this buccal region extends for about one-fifth of the extent of the cord and is then sometimes marked off from the rest by a slight furrow. However, there is no sharp change between the cell character of this and the more posterior region.

At the origin of the cerebro-buccal connectives the posterior buccal region reaches its maximum development and forms a slight swelling (figure 36, plate 4). The wall at this point consists of several layers of rather large (30 μm) and medium (15 μm) cells, but few small ones. Passing further laterally the whole buccal region of large cells then ceases.

(3) *Plexiform zone*

The plexiform zone occupies the region immediately behind the buccal and around the dorsal and posterior surfaces of the cord (figures 35 to 38, plate 4). The outer part consists of bundles running from other centres. Deep to these bundles lies an inner plexiform zone of islands of neuropil surrounded by layers of mainly small cells (figure 41, plate 4). The bundles run very irregular courses and interweave. Many of the bundles run round the circumference from front to back (or vice versa) and presumably arise (or end) in the buccal region (figure 6, and figure 35, plate 4). But others run transversely, especially laterally where they enter this zone from the optic and olfactory lobes (figures 48, plate 5; 59 and 63, plate 7). The details of the endings of these bundles remain uncertain, but it is likely that they allow for the intermingling of fibres from the buccal region with those from optic, olfactory, gustatory, tactile and other sources.

From the interweaving fibres at the surface some large bundles run in towards the centre of the cord especially at the back (figures 38, plate 4; 42, plate 5). Possibly some of these are fibres running ventro-dorsally, from the commissural bundles to the dorsal plexiform zone.

The cells of the plexiform zone are mostly about 7 μm in diameter (nucleus 4 μm). Among these are some medium ones, up to 15 μm (nucleus 6 μm). The inner part of the plexiform zone differs from the outer in containing fewer fibre bundles and more cells, and these are arranged in more definite layers (figure 41, plate 4). In some places this inner part of the plexiform layer is sharply marked off from the more fibrous outer part by a layer of cells.

(4) *Tangential cell layer and laminated zone*

The inner margin of the plexiform zone is marked in a major part of its extent by a conspicuous sheet of closely packed cells, running tangentially (figure 41, plate 4). The cells are mainly small and are often grouped around blood vessels, which are abundant. Deep to this tangential layer is a zone of neuropil, the laminated zone, about 500 μm wide, with few cells. In transverse sections this neuropil seems to consist of layers of fine fibres, running transversely (figure 41). For this reason it is called the laminated zone and it perhaps corresponds to the region lying central to the plexiform zone of the optic lobes (though the latter has more cells).

In sagittal section this neuropil appears as an area of oval shape with its long axis running dorso-ventrally (figures 35, 36, 42, plates 4 and 5). The limiting tangential cell layer can be seen extending down its anterior and posterior faces (figure 43, plate 5), but is not so clearly marked as is the upper part (as seen in transverse sections, such as figure 41, plate 4).

This neuropil of the laminated zone is a very clearly differentiated region of the cord. The bundles of the plexiform layer converge on it from in front, above and behind. Its output presumably passes ventrally to the central part of the cord. There are no preparations available to show what type of fibres make up the neuropil or even where their cell bodies lie. The laminated layer ends rather sharply below with the beginning of the cells of the region that will be called the central zone (figure 41, plate 4).

The tangential zone is most conspicuous in the portion of the cord near the mid-line. In the lateral parts it becomes reduced, or at least has more complex and irregular forms, so that the organization is even more difficult to discern in any one section. The hinder portion of the cerebral region of this lateral part of the cord consists of abundant outer plexiform bundles, extending anteriorly as well as posteriorly and below. From these bundles fibres turn in and run through a 'laminated' zone, in which the individual layers cannot be followed for long distances.

(5) *Central and commissural zones*

Ventral to the laminated zone is a thick layer of bundles and cell islands with fibres running in general in a transverse direction. The distinction between this central zone and the laminated zone is moderately sharp in a suitable transverse section (figure 37, plate 4), but is not easy to recognize in sagittal section. The central region differs from the more dorsal part of the cord in having larger neurons (up to 25 μm diameter, nucleus 10 μm) and a greater proportion of these than smaller ones (figure 44, plate 5). The region is not richly populated with nerve cells and consists largely of laterally running fibres. A characteristic of the central region is the presence of large vascular spaces and much connective tissue. In the median part of the cord the cells become fewer and fewer proceeding ventrally and the central region passes imperceptibly into the commissural region. More laterally the cells are more numerous in the ventral region and the distinction between central and commissural regions, never very sharp, becomes even more difficult.

The central zone is probably the output region of the cord (in addition to the buccal region, which may perhaps be considered as an anterior extension of the central zone). It is continuous laterally with the magnocellular lobe and posterior suboesophageal cord and with the centre of the optic lobe (figure 60, plate 7). More anteriorly it is continuous with the brachial part of the anterior suboesophageal cord, although the latter is more broadly continuous with the plexiform zone and lateral cerebral lobes.

The direction of conduction in these broad connexions is of course unknown but it is probably safe to assume that they are at least partly efferent channels from the cerebral cord, perhaps concerned in directing the search for food.

(6) *Lateral cerebral lobes*

The lateral cerebral lobes are especially developed regions of the plexiform zone, lying at the sides, above the brachial portion of the anterior suboesophageal cord, with which they are continuous (figures 45, 46, plate 5). The lobes thus lie in front of the points of attachment of the optic and olfactory lobes to the cerebral cord. They are placed as it were on top of the region where all the inputs to the nervous system meet and from which the outputs originate.

The lobes contain masses of small islands of neuropil and interweaving bundles of fibres (figure 47, plate 5). The cells are medium-small (15 μm diameter, nucleus 8 μm) and small (6 μm, nucleus 4 to 5 μm). They are much more closely packed than in the less differentiated islands of the plexiform zone of the cerebral cord.

The lobes exchange bundles of fibres with, probably, all the lobes in the neighbourhood. Many run medially to the plexiform zone of the cerebral cord (figure 48, plate 5). The connexions with the brachial lobes already mentioned (p. 9) are very large. Bundles run up directly and separately from each brachial nerve into the lateral cerebral lobe (figure 46, plate 5). Other connexions are with the olfactory, optic, magnocellular and buccal regions. Unfortunately there is no way of determining the direction of conduction in these tracts and the mode of functioning of the lobes remains uncertain (see p. 22).

OPHTHALMIC NERVES

A series of small nerves appear to leave from the postero-lateral border of the cerebral cord (figure 1). These are not however truly cerebral nerves. They run down the back of the cerebral cord (figure 49, plate 5) but do not enter it. Their true origin is from the extreme dorsal margin of the palliovisceral lobe (figure 13, plate 1). They may innervate the skin around the eyes.

THE OLFACTORY ORGAN AND OLFACTORY LOBES

The rhinophore is a short hollow tentacle, with expanded upper and lower lips, lying immediately below the eye (Willey 1902; Fernandez 1907 (figure 24, plate 2, and 50, plate 6). Its cavity is lined by a tall ciliated epithelium, very much folded and highly vascular (figure 52, plate 6). Three cell types can be seen. The largest of them (Zernoff's cells) contain conspicuous ovoid masses of clear material (12 × 15 μm) on the side of the nucleus towards the lumen, sometimes with a second mass proximal to the nucleus (figure 52) (Zernoff 1869). These masses lie at some distance from the surface and the cells have narrow tips proceeding distally. They are also drawn out basally and may have processes that are axons. However, it is not certain that these are the receptor cells as Watkinson (1909) supposed in other cephalopods. They may be secretory (Fernandez 1907) and various appearances are seen suggesting that they discharge their contents and shrink to become the second type of cell that is seen. These have long, thin cell bodies, reaching to the lumen and a small nucleus at the base (figure 52, 53, plate 6). Their cytoplasm is strongly basophilic.

The third cell type is shaped like a narrow vase, carrying numerous cilia distally and with a long, thin ovoid nucleus (figure 53, plate 6). It cannot be excluded that this third type tapers to an axon though perhaps as Watkinson (1909) says this is unlikely. We are therefore left with the probability, but not certainty, that the Zernoff's cells with large inclusions are the receptors.

No ganglion cells have been seen immediately below the epithelium but they occur along the course of the nerves leading away from it (figure 54, plate 6).

The nerve fibres collect to form a set of bundles at the dorsal border of the canal (figure 51, plate 6). Here there are further nerve cells mixed with the fibres and the whole may be called the olfactory ganglion. The cells of this ganglion are scattered and many of them are rather large. The smaller nuclei may belong mainly to glia. Medial to the end of the canal the cells become fewer, leaving the olfactory nerve as a strand lying below the optic lobe (figure 50, plate 6).

The nerve leads to the olfactory lobe, which is essentially a lateral extension of the cerebral cord, arising behind the optic stalk and then passing ventrally and backwards to receive the olfactory nerve. The lobe thus roofs the lateral part of the cerebral fissure (figure 55, plate 6), and then lies dorsal and lateral to the magnocellular lobe.

The layers characteristic of the cerebral cord can be recognized in the olfactory lobe (figure 55). The dorsal and lateral parts consist of cords of neuropil, fibres and small cells running transversely and continuous with the plexiform layer of the cerebral cord. Below this is a laminated zone, then bands of fibres that are continuous with the central and ventral parts of the cord. Larger cells are present in these more ventral regions. The olfactory nerve fibres enter the lobe as a series of bundles some of which become distributed in the plexiform zone. Others probably run directly to the laminated and central portions.

In its more lateral and ventral parts the olfactory lobe is fully continuous with the underside of the optic lobe and many bundles of fibres run between the two (figure 50, plate 6).

Analysis of the connexions of the olfactory lobe are, as with other lobes, complicated by ignorance of the direction of the fibres. Connexions have been traced to the optic, cerebral, lateral cerebral, magnocellular, infundibular and palliovisceral regions. Presumably most of these consist of bundles running *from* the olfactory organ, but there may well be some going the other way.

OPTIC GLAND TISSUE

Tissue that possibly corresponds to the optic glands of coleoids is seen at the margin of the junction of the olfactory and optic lobes (figure 56, plate 6). The cells have abundant cytoplasm, and nuclei relatively smaller and more darkly staining than those of the nearby neurons. In each cell there is a rod, intensely stained by the silver method (figure 57, plate 6). This may perhaps be Golgi material and it is not impossible that these are secretory cells. However, they probably also have fibrous prolongations and it is not unlikely that they are neurosecretory cells, perhaps concerned with the regulation of reproduction as are the optic glands of *Octopus vulgaris* (Wells & Wells 1959) which lie in a similar position upon the optic tract.

OPTIC LOBES

These are lateral extensions of the supraoesophageal lobes. Dorsally they are separated from the main cerebral cord only by slight depressions (figure 60, plate 7). Ventrally they are continuous with the magnocellular lobes. The olfactory lobes, which are also extensions of the cerebral cord, are attached to their lower and posterior surfaces (figure 64, plate 7).

In transverse sections each lobe presents about three quarters of a rather irregular circle. The optic nerve fibres enter all over its lateral surface. The longest optic nerve fibres are 10 mm or more. They pass from the retina to the optic lobe without forming a dorso-ventral chiasma such as is present in coleoids (figure 58, plate 7; figure 8). This fact further complicates the problems posed by this chiasma (Young 1962). The pin hole aperture presumably produces an inverted image. If some form of re-inversion is necessary in higher cephalopods why is it absent in *Nautilus*? Griffin (1900) commented that as the optic nerves are distributed between the retina and the optic lobes they 'twist slightly about the axis of the nerve'. His figure suggests that this might possibly have the effect of connecting the dorsal part of the retina with the ventral part of the lobe. Such dissections as I have made have not, however, shown clear signs of this spiral arrangement. It is not easy to obtain decisive evidence on the point from sections. Figure 58 shows that there is no striking spiral arrangement at least of the central fibres of the retina. There may perhaps be some twisting of the outer ones, but this can hardly be enough to produce inversion.

The substance of the optic lobe is divided into layers, continuous with the comparable regions of hind part of the cerebral cord (figures 59, 60, plate 7). However, the plexiform layer of the cord receives fibres from the centre of the optic lobe, rather than from its plexiform layer (figure 63, plate 7). There is no clearly distinct commissural layer, but fibres from the centre of the optic lobe proceed ventrally and probably cross to the other side.

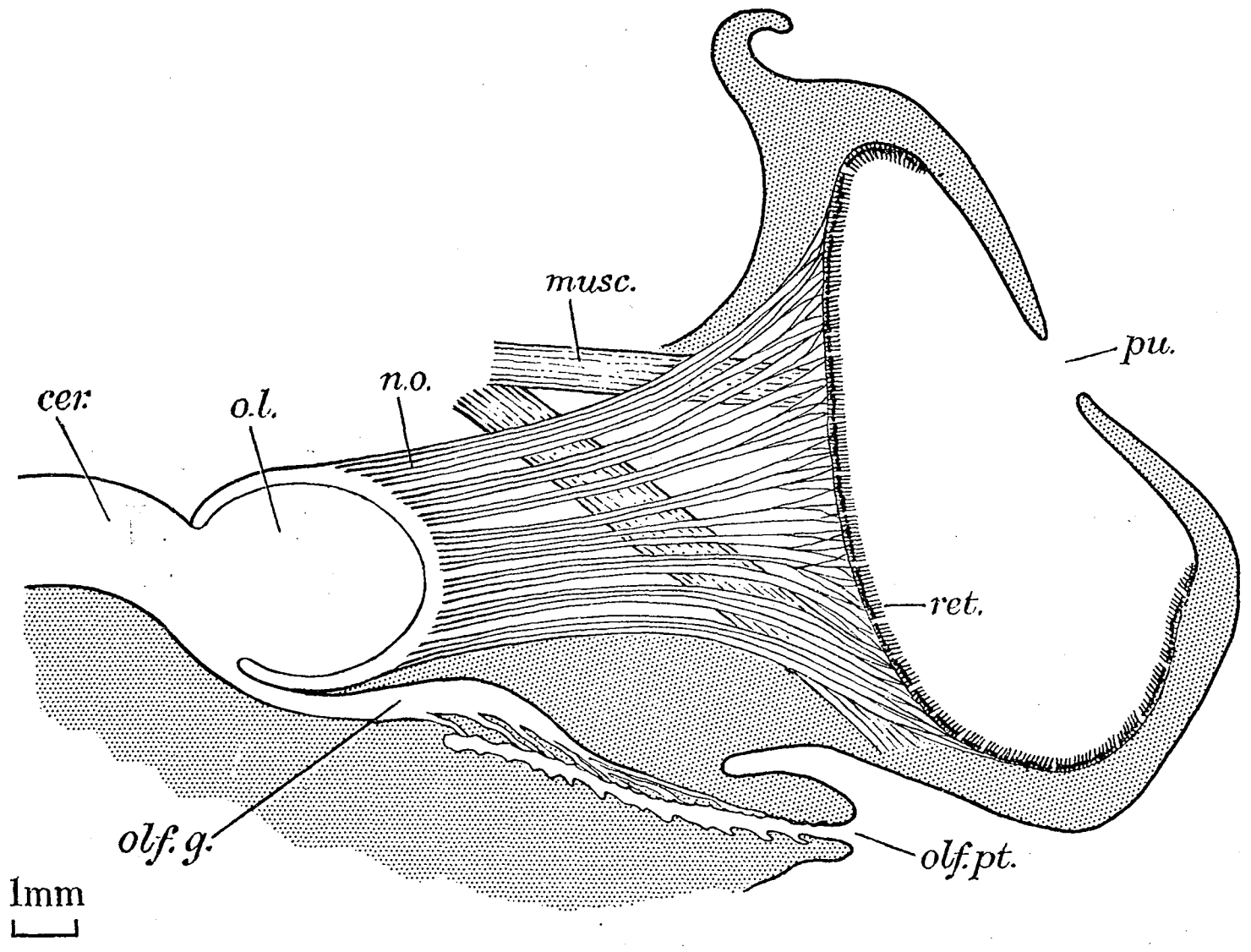

FIGURE 8. Transverse section of *Nautilus* to show the pin-hole eye, retina and optic nerves without chiasma.

The plexiform layer, up to 400 μm thick, receives the optic nerve fibres. There is no regular outer granular cell layer but the whole plexiform layer contains scattered cells of various sizes up to 14 μm diameter (nucleus 8 μm) and down to less than 5 μm (nuclei 3 to 4 μm) (figures 61, 62, plate 7).

Immediately inside the plexiform zone lies a well-defined tangential layer of cells and within this are rather less regular tangential layers of cells, constituting the laminated zone (figure 61). The lamination is a series of layers of cells and of neuropil as seen in these preparations in which mainly nuclei are stained. However, there are no doubt numerous fibres and bundles running radially and signs of this appear in the arrangement of the blood vessels and glia.

The layers become progressively less regular proceeding inwards, so that the inner members form cell islands similar to those of coleoid cephalopods. The cells of the outermost tangential layer reach the same maximum size as those in the plexiform layer. The remaining laminae are composed mainly of rather smaller cells.

The laminated region occupies about 1 mm and merges gradually into the central region of the lobe. The cells become few and larger and less regularly arranged. Fibre bundles interweaving irregularly become more frequent. The cells in the islands near the centre of the lobe reach up to 40 μm in diameter (nucleus 12 μm).

There is no clear division between this central zone of the optic lobe and that of the supraoesophageal cord (figure 60, plate 7) and the two interchange many fibres. These bundles run between all parts of the optic lobes and all levels of the cerebral cord. Some end in the plexiform zone (figure 63, plate 7), others in the laminated zone and throughout the central and ventral (commissural) parts of the cord.

Fibre bundles from the central region, besides those running to the cerebral cord, turn sharply into the magnocellular lobe (figure 64, plate 7). From here they may reach the infundibular and palliovisceral lobes. In the ventral hinder part of the centre of the optic lobe are many bundles accompanied by few cells and from here there may be commissural fibres, running in the ventral part of the cerebral cord.

Discussion

In what senses can the nervous system of *Nautilus* be considered to be 'primitive'? Perhaps a scientifically more valuable question is to ask 'What can be learned from this particular stage of evolution about the design principles and operation of cephalopods and of nervous systems in general?'.

Nautilus already has a nervous system composed of a great number of channels. This is obviously not an animal with relatively few and large neurons like a gasteropod or a lamellibranch. In this sense *Nautilus* is already far from being 'primitive'. On the other hand it has no regions containing vast numbers of minute cells like the vertical or subfrontal lobes of octopods.

The parts of the brain are anatomically more spread out than in coleoids, but all the major parts are already present. Their dispersal may be a specialization in the sense that it allows large and hard particles to pass down the oesophagus. The very strong beak enables *Nautilus* to bite up such prey and indeed it may need to do this to kill, as it lacks differentiated posterior salivary glands for poisoning.

(1) *Tentacles*

If the interpretation given on p. 8 is correct the tentacles and hood are essentially of cephalic origin, innervated from the supraoesophageal region by a down-growth of tissue that joins the true pedal (infundibular) lobe to make the anterior suboesophageal cord. It is perhaps not profitable to re-open the controversy between the 'pedal' and 'cephalic' theories of the origin of the cephalopod tentacles (see Willey 1902 for summary to that date). The present evidence seems to support the cephalic theory. Whichever point of view proves correct we can say that the development of receptor and prehensile organs on the head is another of the characteristic cephalopod characters that is already developed in *Nautilus*. However, the tentacles are very different from those of coleoids and we have no means of knowing whether they are a specialized side-line or represent an ancestral condition.

The pre- and post-ocular tentacles that are still so well preserved in *Nautilus* may be the remains of an earlier condition, which has disappeared in higher forms as the 'new' cephalic tentacles became more developed.

(2) *Receptors*

In the general plan of its receptors *Nautilus* is probably macrosmatic, with poor visual powers. The great size of the rhinophore and olfactory lobe is one of its most interesting features. Unfortunately it is not known whether the rhinophore functions as a distance receptor. The eye with its rather large 'pin hole' can hardly serve for detailed form discrimination, which in any case would often be difficult for lack of light in the depths of the sea. Nevertheless, the number and density of rhabdomes are much greater than in any non-cephalopod molluscs. The optic lobes can clearly be seen to be lateral extensions of the cerebral cord. They are relatively small and lack the outer granular layer, the small cells of which, in coleoids, perhaps serve to sharpen contours for discrimination of patterns. There is also no sign of the differentiation of a peduncle lobe on the output pathway of the optic lobe, a difference that may help in establishing the function of that lobe (see Messenger 1965).

The gravity receptor system probably also provides a relatively simple pattern of signals. The sack, filled with an otolith, presumably serves to record the orientation of the body and could also respond to angular acceleration but there is no sign of the division into the macula and crista of higher forms, capable of resolving this information.

(3) *Cerebral centres*

The condition of the cerebral centres is of outstanding interest. They are better developed than in any mollusc outside the cephalopods. The distribution of functions within the cord follows the pattern found in coleoids but the cord is not divided into distinct lobes. Probably the basic function of the cerebral system is the control of feeding and the search for food. In *Nautilus* the whole cord still constitutes a single undivided centre. Mechanisms for response to combinations of inputs and perhaps for recording in a memory system are only beginning to differentiate within the basic system for controlling the operations of search and capture of prey and of eating. The front part of the cord is occupied by relatively large cells from which arise the fibres that control the buccal mass. Fibres from the lips end here, and probably also others from the buccal mass, perhaps concerned with 'hunger' and 'taste'. Signals in such fibres would serve to activate the search for food ('motivation') and to indicate that it had been found (signals of 'reward'). This region is thus similar to the posterior buccal system of *Octopus*, which performs similar activities (Young 1965*b*).

A further function of such taste signals in higher forms is to instruct the memory systems associated with distance receptors as to the results that follow when particular patterns occur at the receptors. There are indications that *Nautilus* possesses such a system. The plexiform zone of the cerebral cord receives fibres probably from all the receptor systems. The plexiform zone has some similarity with the interlacing webs of fibres that are found in the inferior and superior frontal lobes of *Octopus*. Indeed the lateral cerebral lobe of *Nautilus*, a specialized region of the plexiform zone, is comparable with the inferior frontal system of *Octopus* as a region receiving the incoming fibres from the arms. Presumably these interlacing systems somehow allow for the interaction between inputs that makes the system able to respond to particular simultaneous combinations of signals rather than to simple point stimuli or successive events. They may also serve to 'mix' with these combinations the signals of results (taste and pain).

Central to the plexiform zones lie the tangential layers and laminated zones, which are regions of small cells and specialized neuropil. They are comparable with the vertical lobes of coleoids in position (approximately) and in receiving their input through the plexiform layers, but their internal organization, so far as it is apparent, resembles that of the optic lobes. Further information about their cells should be most interesting.

The central and ventral (commissural) regions of the cerebral cord contain larger cells than the dorsal parts and appear to provide the output pathways to other parts of the central nervous system. In this respect they resemble the comparable basal regions of the coleoid brain, which are there divided into distinct anterior, posterior and lateral basal lobes.

The cerebral system of *Nautilus* thus seems to be so arranged as to be capable of assisting in the search for food. It cannot of course be excluded that it is involved in other behaviour, for example, sexual display. One further respect in which *Nautilus* seems less differentiated than the coleoids is the absence of a compact optic gland for the control of the rate of maturation and sexual maturity. Cells possibly with an endocrine function are, however, present (p. 19).

The plan of the *Nautilus* cerebral cord thus constitutes as it were a general sketch of the various more finished products that are found in coleoids. In this sense it truly presents a 'primitive' condition. It seems likely that the higher centres serve to allow the nautili to respond to patterns of afferent impulses within and between sensory modalities. They probably serve for at least limited storage of representations of past situations. The developments of higher cephalopods have come about by further emphasis on the eyes as distance receptors in place of smell and in improvement of the motor apparatus for swimming and manipulation of food objects. The rather undifferentiated higher centres of *Nautilus* presumably allow sufficient channels for combinatorial and storage functions, granted the low resolution and limited range of the receptors, and the relatively undifferentiated motor system. Yet the pattern of both receptors and effectors is already quite complicated (Bidder 1962). In higher cephalopods the increasing use of the eyes as distance receptors in place of the rhinophore, and improvement of the motor apparatus for swimming, catching and handling prey have been accompanied by the differentiation of the cerebral cord into its numerous distinct lobes.

The interesting parallelism in the transition from macrosmatic to visual animals in cephalopods and in vertebrates is another of the pronounced similarities between these groups, parallels that transcend the great differences in basic organization. The demands made by the development of an elaborate nervous system and behaviour pattern produce not only similar organizations within the receptors and brain but even dictate similar patterns of evolution.

I am grateful to Dr A. Bidder and Professor D. Barker for their assistance in obtaining material. Also to Miss P. Stephens for preparing the long series of large sections, and to Miss T. Hogan for help with photography. Mrs J. Astafiev prepared figures 1 to 4. Mr V. Barber gave most valuable help in the preparation of the MS.

REFERENCES

Bidder, A. M. 1962 Use of the tentacles, swimming and buoyancy control in the Pearly Nautilus. *Nature, Lond.* **196**, 451–454.

Boycott, B. B. & Young, J. Z. 1950 The comparative study of learning. I. The comparative method in study of the higher nervous activities. *Symp. Soc. exp. Biol.* **4**, 432–453.

Boycott, B. B. & Young, J. Z. 1965 The brain of *Octopus vulgaris*. (In preparation.)

Fernandez, M. 1907 Zur Histologie der Tentakel und des Rhinophors des *Nautilus pompilius*. *Z. wiss. Zool.* **88**, 187–211.

Griffin, L. F. 1897 Notes on the anatomy of *Nautilus pompilius*. *Zool. Bull.* **1**, 147–161.

Griffin, L. E. 1900 The anatomy of *Nautilus pompilius*. *Mem. Acad. Sci. Wash.* **8**, 103–230.

Hensen, V. 1865 Ueber das Auge einiger Cephalopoden. *Z. wiss. Zool.* **15**, 155–242.

Huxley, T. 1859 On some points on the anatomy of *Nautilus pompilius*. *J. Linn. Soc.* (*Zool.*), **3**, 36–44.

Jhering, H. von 1877 *Vergleichende Anatomie des Nervensystem und Phylogenie der Mollusken*. Leipzig.

Keferstein, W. 1866 'Cephalopods' in Bronn's *Klassen und Ordnungen*. Heidelberg.

Kerr, J. G. 1895 On some points in the anatomy of *Nautilus pompilius*. *Proc. Zool. Soc.* **38**, 664–686.

Macdonald, J. D. 1855 On the anatomy of *Nautilus umbilicatus* compared with that of *Nautilus pompilius*. *Phil. Trans.* **145**, 277–288.

Macdonald, J. D. 1857 Observations on the anatomy and physiology of *Nautilus*. *Proc. Roy. Soc.* **8**, 380–382.

Merton, H. 1905 Über die Retina von *Nautilus* und einigen dibranchiaten Cephalopoden. *Z. wiss. Zool.* **79**, 325–396.

Messenger, J. 1965 (In preparation.)

Owen, R. 1832 *Memoir on the Pearly Nautilus* (Nautilus pompilius *Linn*). London: Richard Taylor.

Thore, S. 1939 Beiträge zur Kenntnis der vergleichenden Anatomie des zentralen Nervensystems der dibranchiaten Cephalopoden. *Pubbl. staz. zool. Napoli*, **17**, 313–506.

Vayssière, A. 1896 Etude sur l'organisation du Nautile (caractères zoologiques dimorphisme sexual, tentacules et spadice). *Ann. Sci. Nat.* (Ser. VIII), **2**, 137–186.

Watkinson, Grace B. 1909 Untersuchungen über die sogenannten Geruchsorgane der Cephalopoden. *Jena Z. Naturw.* **44**, 353–414.

Wells, M. J. & Wells, J. 1959 Hormonal control of sexual maturity in *Octopus*. *J. exp. Biol.* **36**, 1–33.

Willey, A. 1897*a* The pre-ocular and post-ocular tentacles and osphradia of *Nautilus*. *Quart. J. micr. Sci.* **40**, 197–201.

Willey, A. 1897*b* The adhesive tentacles of *Nautilus* with some notes on its pericardium and spermatophores. *Quart. J. micr. Sci.* **40**, 207–209.

Willey, A. 1902 Contributions to the natural history of the Pearly Nautilus. *Zoological Results*, pt. **6**, 736–830.

Young, J. Z. 1939 Fused neurons and synaptic contact in the giant nerve fibres of cephalopods. *Phil. Trans.* B, **229**, 465–503.

Young, J. Z. 1960 The statocysts of *Octopus vulgaris*. *Proc. Roy. Soc.* B, **152**, 3–29.

Young, J. Z. 1961 Learning and discrimination in the *Octopus*. *Biol. Rev.* **36**, 32–96.

Young, J. Z. 1962 'Why do we have two brains?' from *Conference on Cerebral Dominance. John Hopkins University School of Medicine, Maryland*, 23–25 April 1961, pp. 7–24.

Young, J. Z. 1965*a* The buccal nervous system of *Octopus*. *Phil. Trans.* B, **249**, 27.

Young, J. Z. 1965*b* The centres for touch discrimination in *Octopus vulgaris*. *Phil. Trans.* B, **249**, 45.

Zernoff, D. 1869 Über das Geruchorgan der Cephalopoden. *Bull. Soc. Imp. Nat. Moscou*, **42**, 71–90.

Abbreviations used on plates and diagrams

ant.com.	anterior suboesophageal commissure
ant.sub.	anterior suboesophageal mass
b.	beak
br.l.	brachial lobe of anterior suboesophageal mass
br.n.fib.	brachial nerve fibres running direct to lateral cerebral lobe
bu.	bundles of fibres running from the plexiform zone to the centre of the cerebral cord
bucc.	muscles of buccal mass
buc.i.g.	inferior buccal ganglion
buc. lat.l.	lateral buccal lobe
buc.med.l.	median buccal lobe
buc.p.l.	posterior buccal lobe
buc.sup.g.	superior buccal ganglion
cen.	central zone of cerebral cord or optic lobe
cer.	cerebral (supraoesophageal) cord
cer.–buc.	cerebro–buccal connective
cer.fis.	cerebral fissure
cer.lat.–buc.	lateral cerebral–buccal tract
cer.lat.l.	lateral cerebral lobe
cer.med.–buc.	median cerebral–buccal tract
cil.	ciliated cell
com.bu.	commissural bundles (of pallioviscerai or cerebral cords)
cr.	crop
dig.	digital tentacles
e.	eye
f.	funnel
gc.	giant cell
h.	hood
ic.	inclusion
inf.l.	infundibular (funnel) lobe of anterior suboesophageal mass
lab.i.l.	inferior labial lobe
lab.sup.	inner tentacles of superior labial lobe
lab.sup.l.	superior labial lobe
lam.	laminated zone of cerebral cord
li.	lips
mag.l.	magnocellular lobe
musc.	muscle
n.br.	brachial nerve
n.h.	hood nerve
n.inf.	infundibular (funnel) nerve
n.lab.	labial nerves
n.o.	optic nerves
n.oc.p.	nerve of posterior ocular tentacle
n.oc.pre.	nerve of pre-ocular tentacle
n.olf.	olfactory nerve
n.op.	ophthalmic nerve
n.pal.	palatine nerve
n.prel.	prelingual nerve
n.st.	static nerve
n.v.	visceral nerves
oc.po.	post-ocular tentacle
oc.pre.	pre-ocular tentacle
ocul.	oculomotor muscles
o.gl.?	possible optic gland tissue?
o.l.	optic lobe
olf.g.	olfactory ganglion
olf.l.	olfactory lobe
olf.pa.	olfactory palp
olf.pt.	olfactory pit
o.tr.	optic tract
p.sub.	posterior suboesophageal mass
ped.l.	pedal lobe
pl.	plexiform zone of cerebral cord or optic lobe
pl.in.	inner plexiform zone
pl.out.	outer plexiform zone
prel.pr.	prelingual processes
pu.	pupil
pv.	palliovisceral cord
rad.	radula
ret.	retina
retr.	retractor muscles
rh.	rhinophore
sin.	vascular spaces in rhinophore
st.	statocyst
st.d.	duct of statocyst (Kölliker's canal)
tan.	tangential layer of cerebral cord
Zc^1 Zc^2	Zernoff's cells of rhinophore

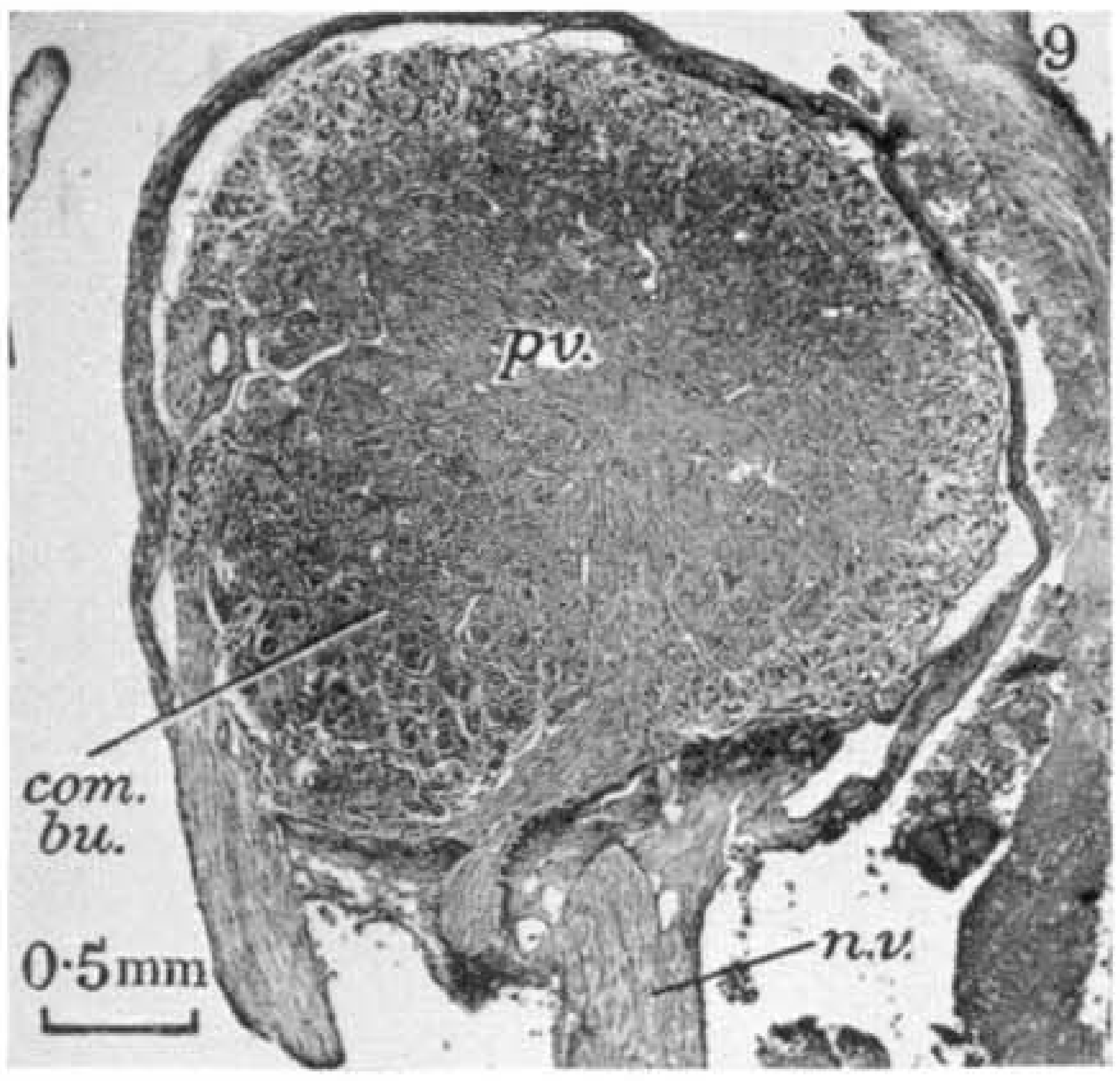
9
pv.
com.
bu.
n.v.
0·5mm

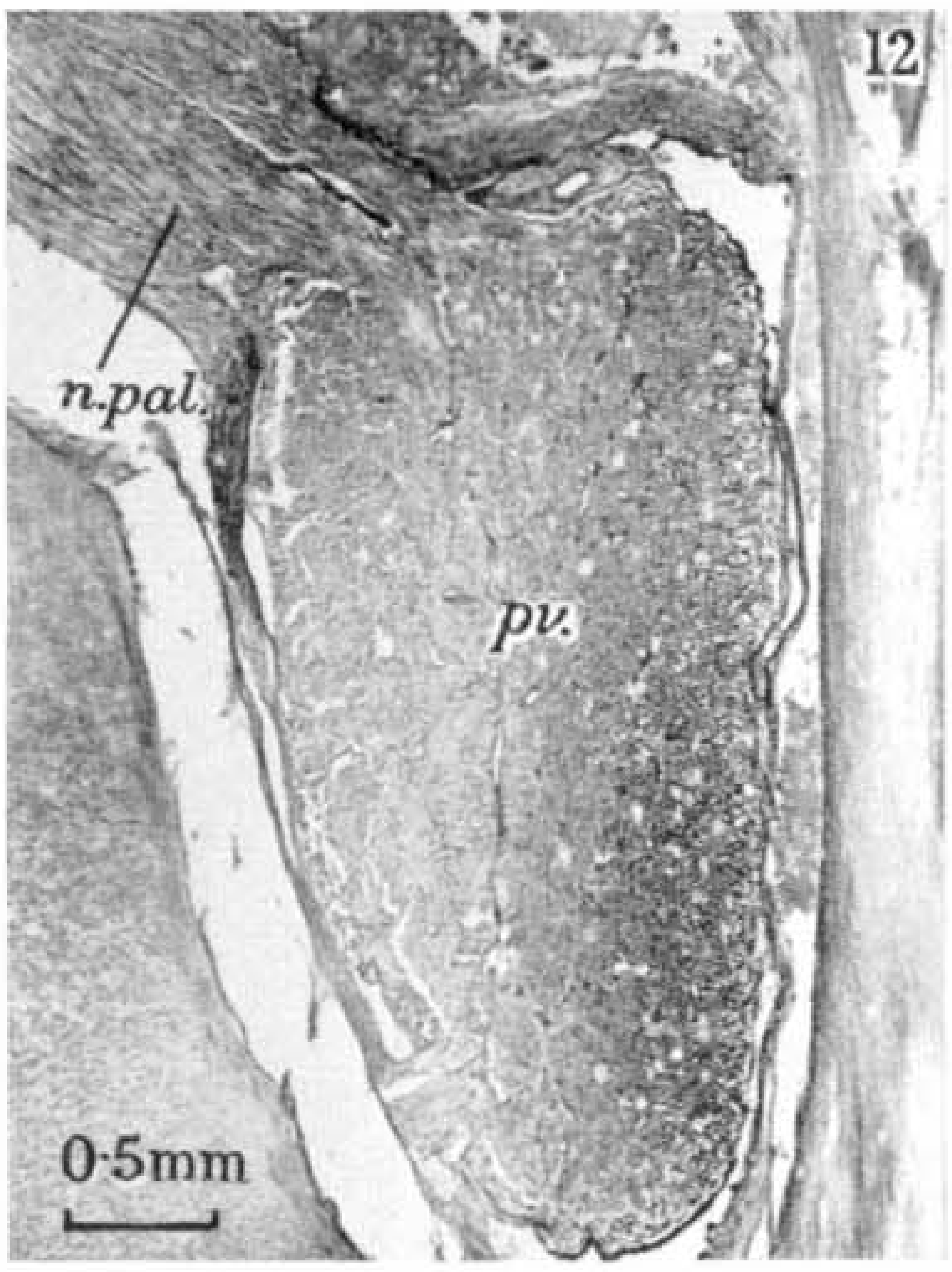
12
n.pal.
pv.
0·5mm


11
100μm

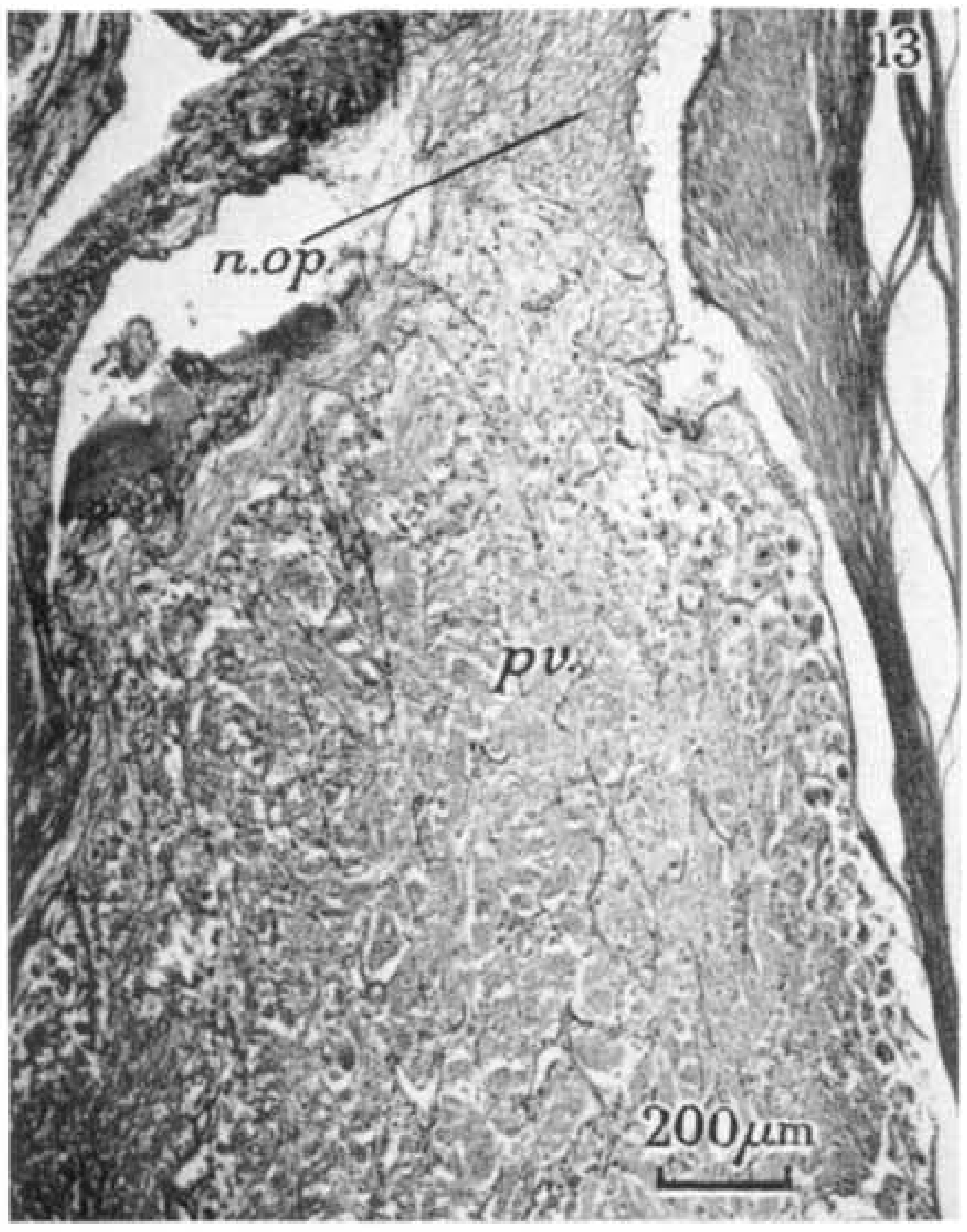
13
n.op.
pv.
200μm


16
200μm

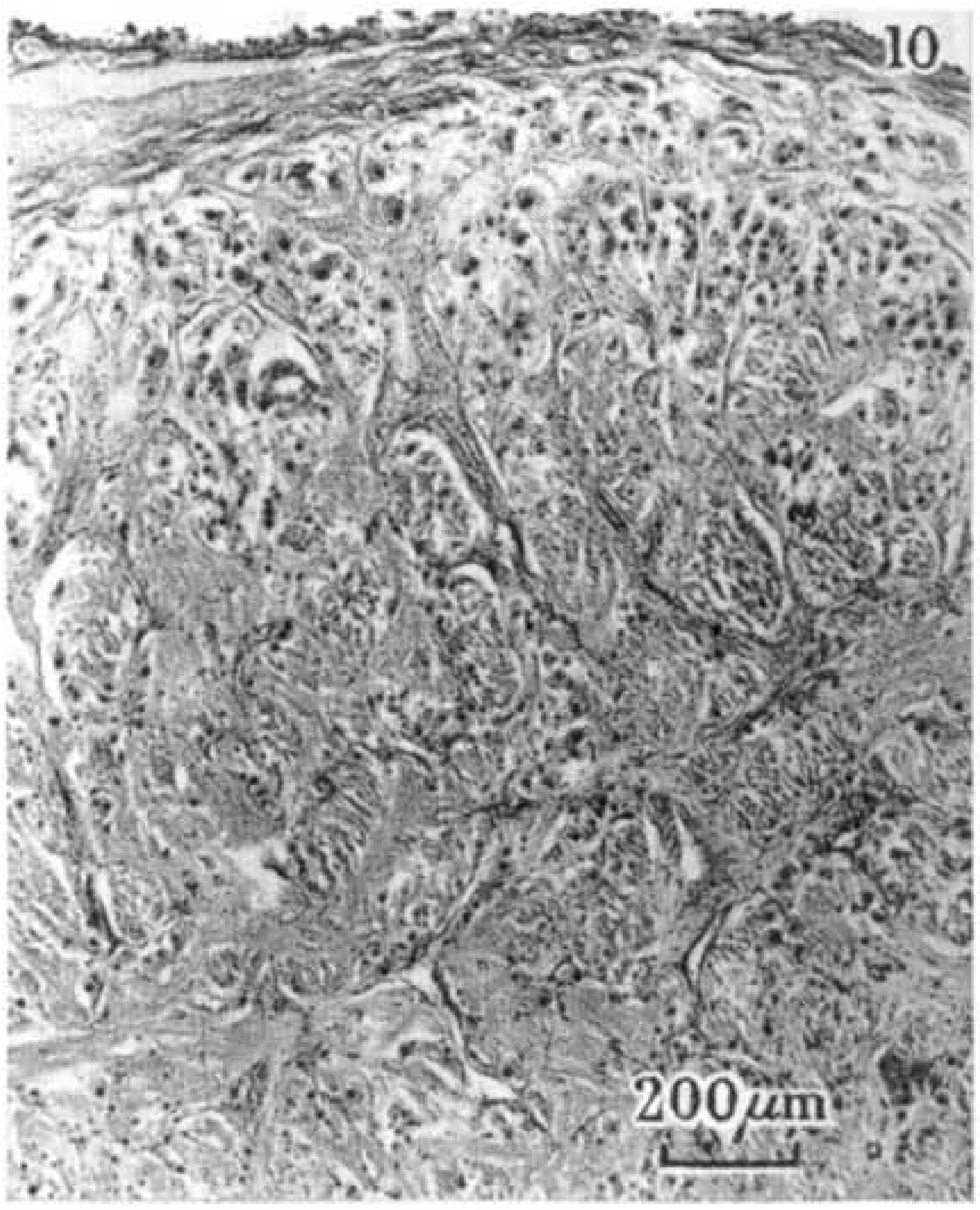
10
200μm


17
cer.
br.l.
200μm

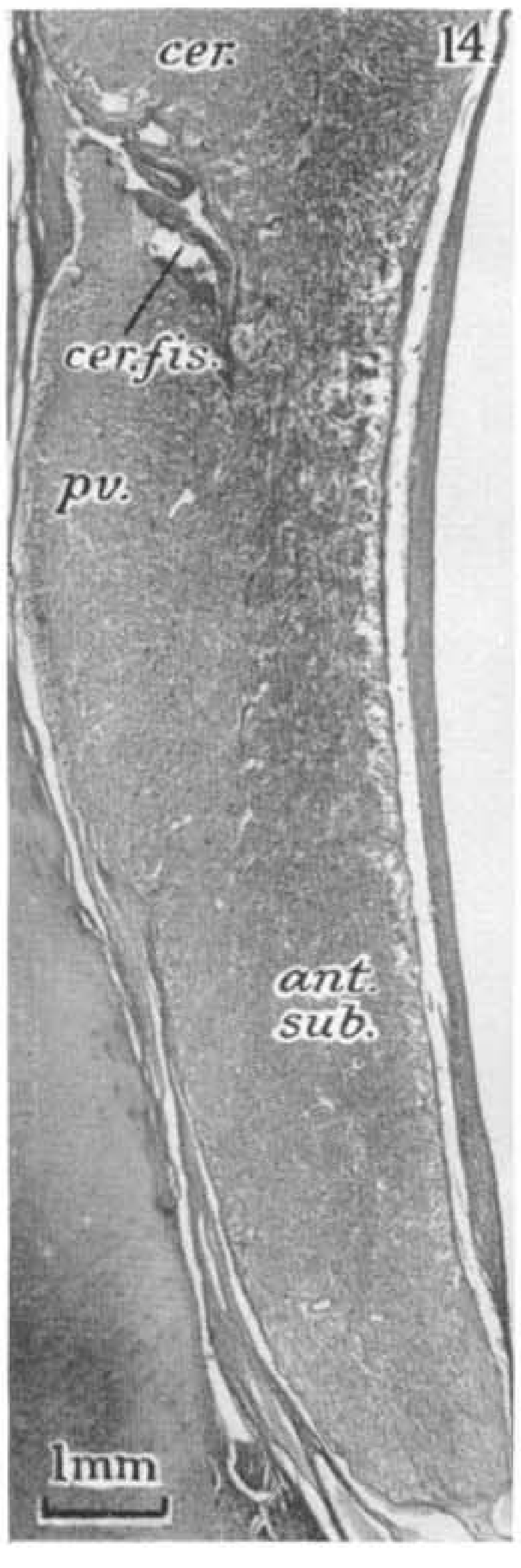
14
cer.
cer.fis.
pv.
ant.
sub.
1mm

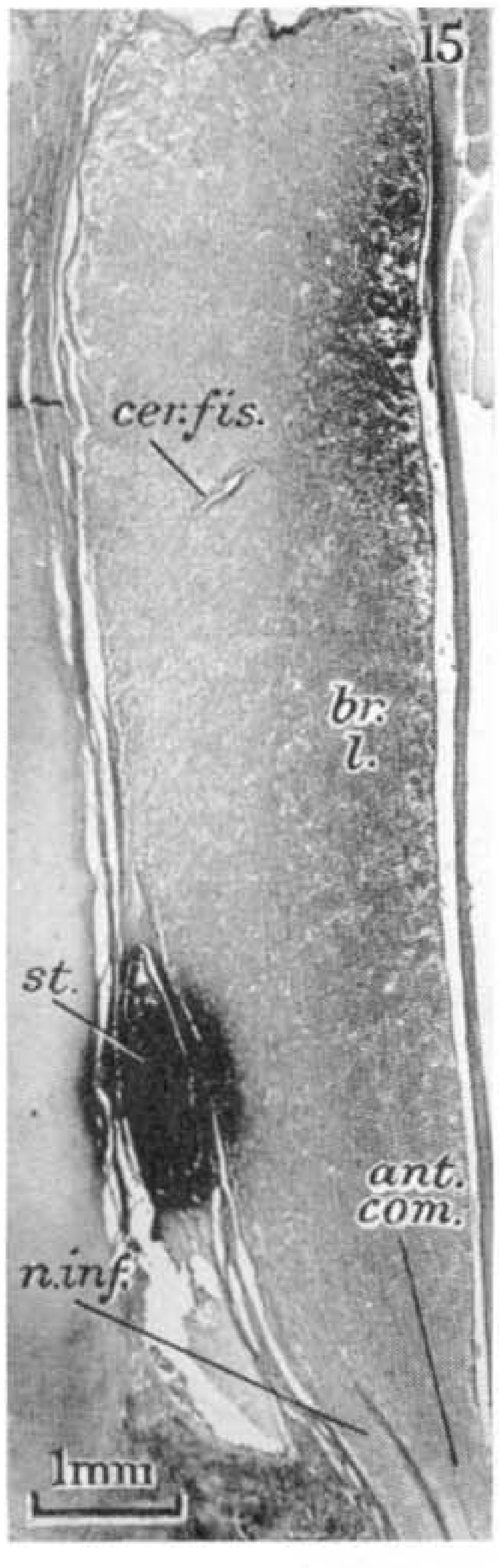
15
cer.fis.
br.
l.
st.
ant.
com.
n.inf.
1mm

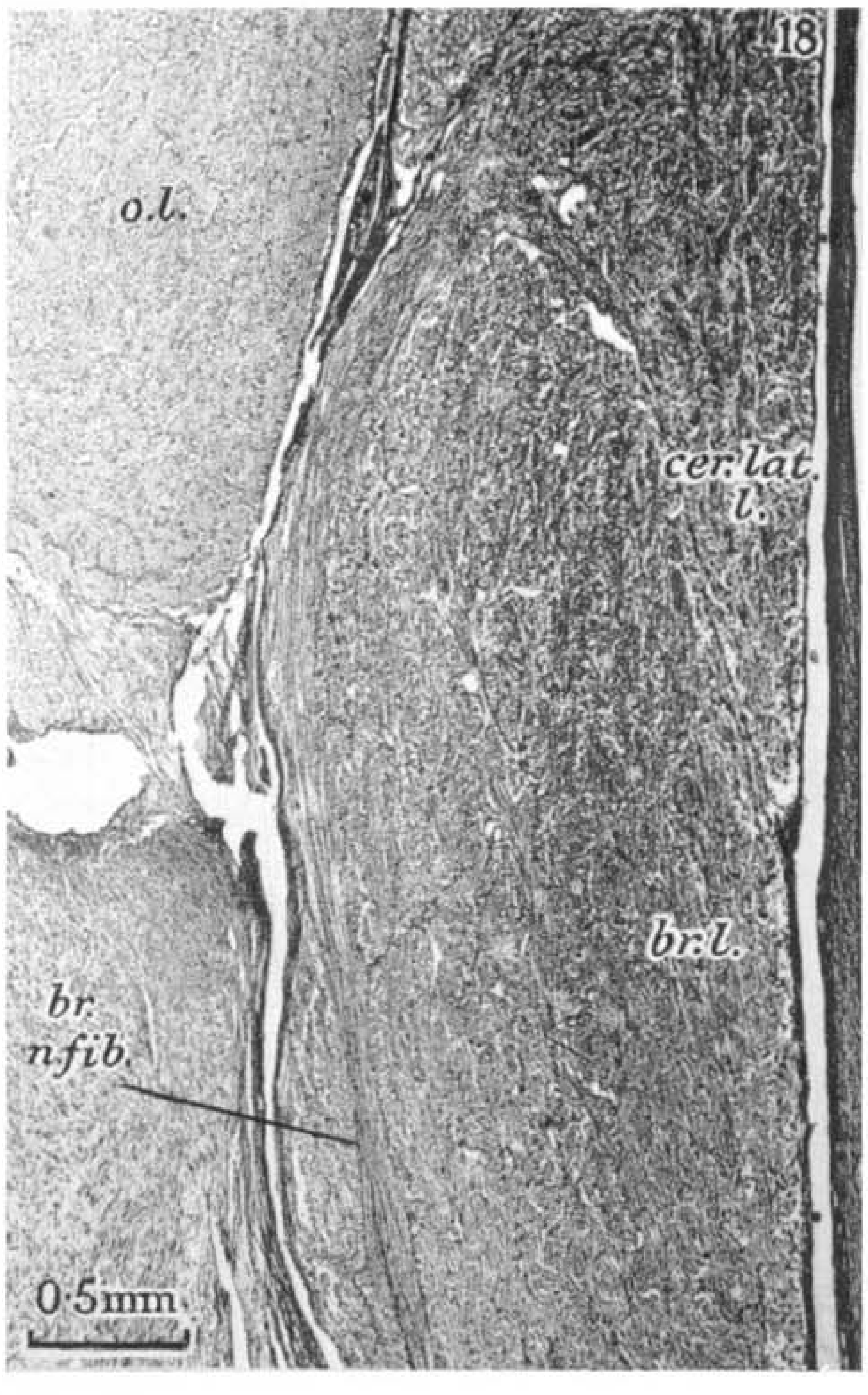
18
o.l.
cer.lat.
l.
br.l.
br.
n.fib.
0·5mm

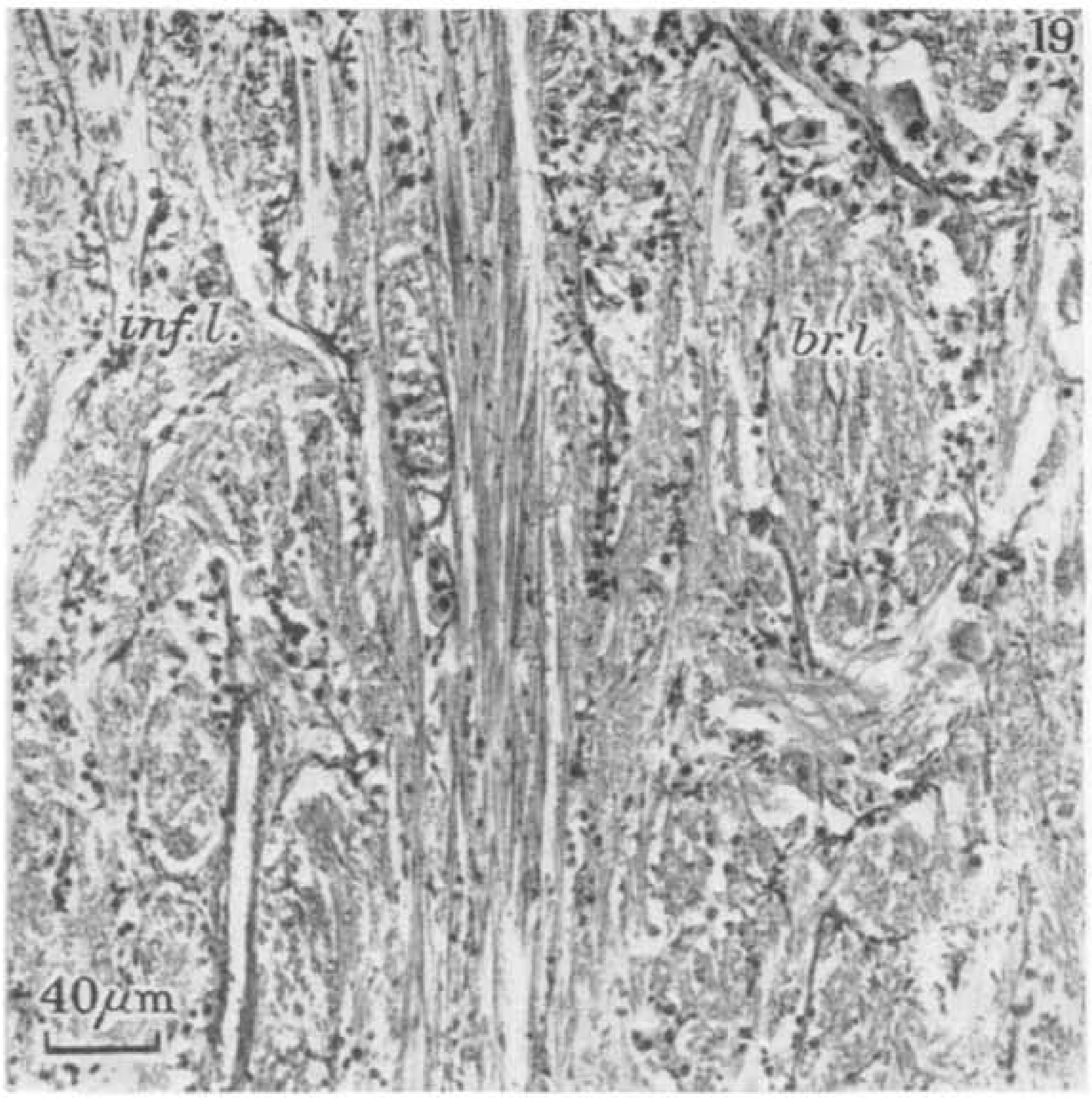
19
inf.l.
br.l.
40 μm

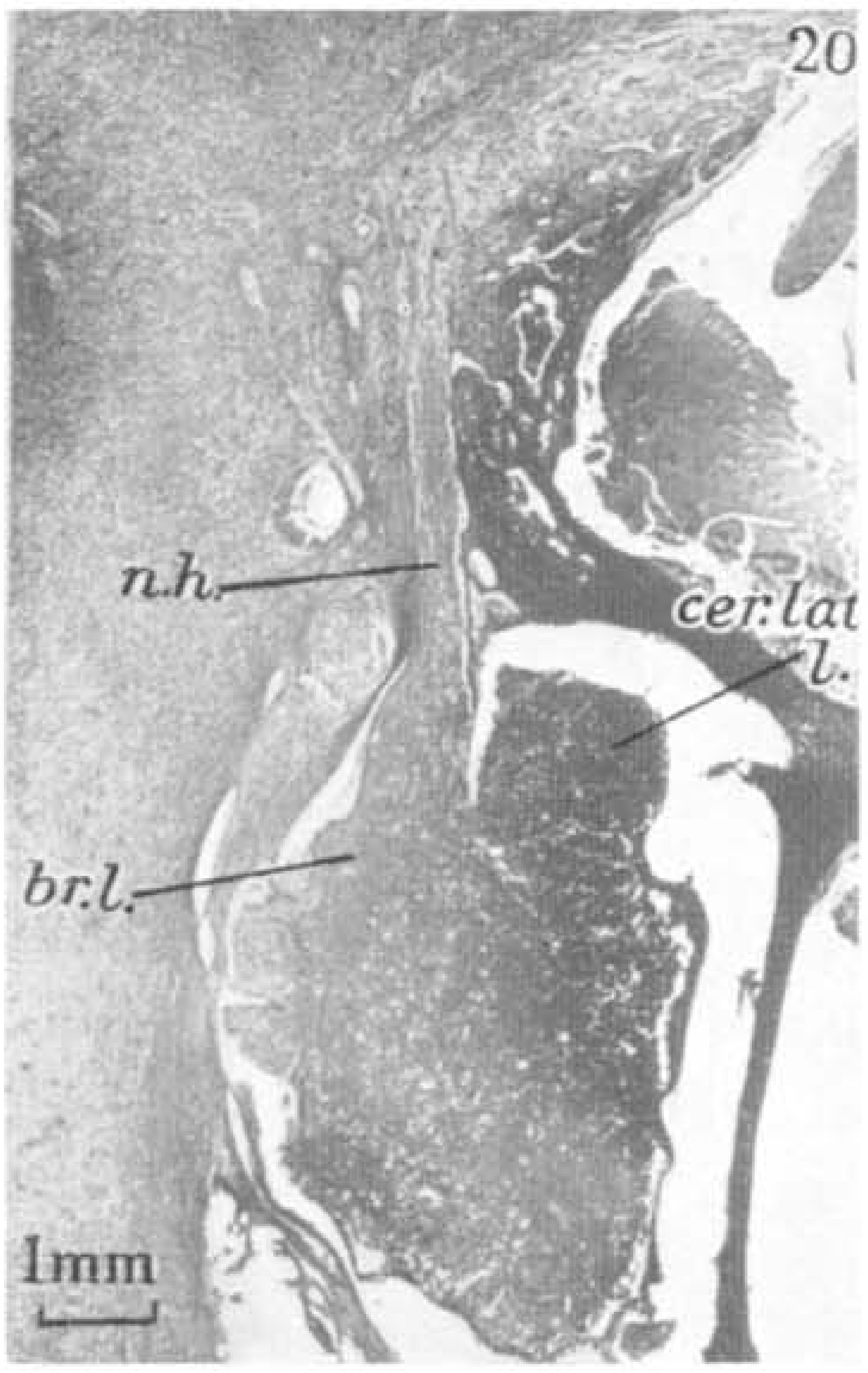
20
n.h.
cer.lat
l.
br.l.
1mm

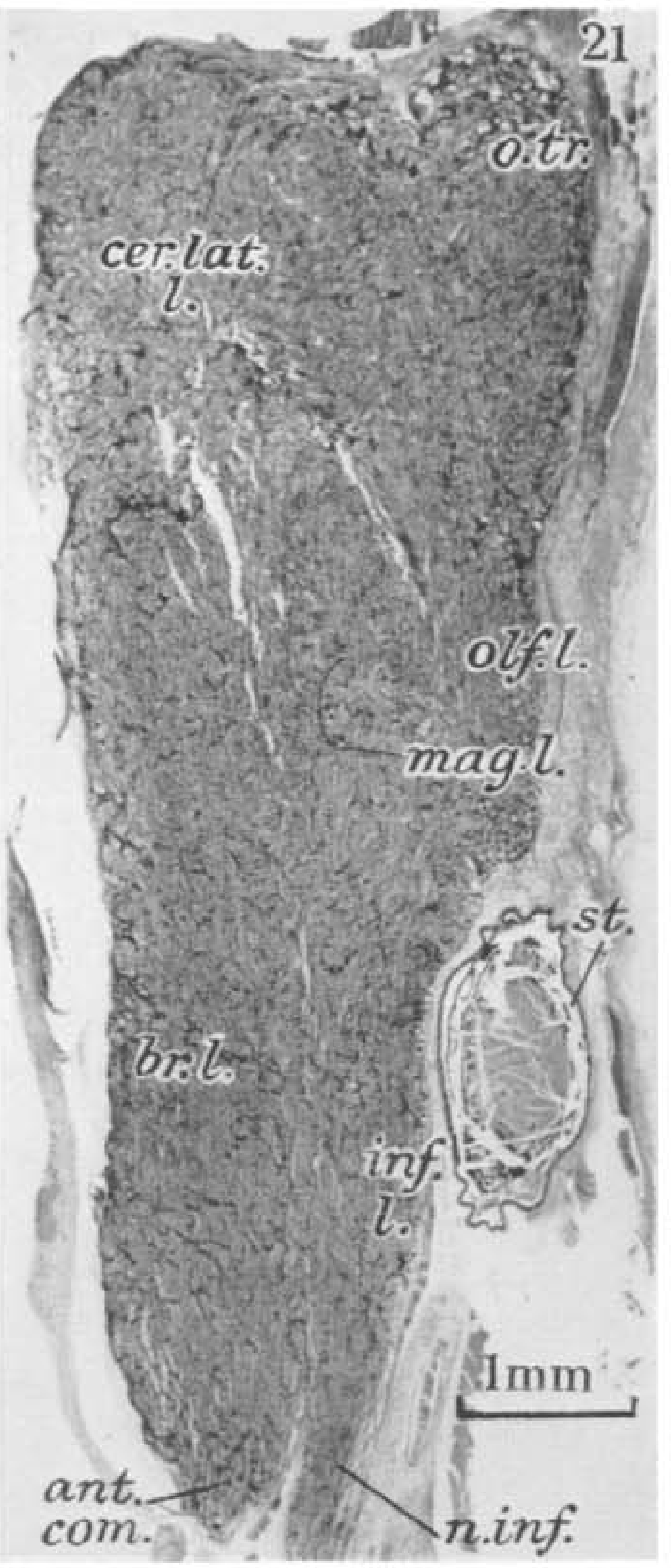
21
o.tr.
cer.lat.
l.
olf.l.
mag.l.
st.
br.l.
inf.
l.
1mm
ant.
com.
n.inf.

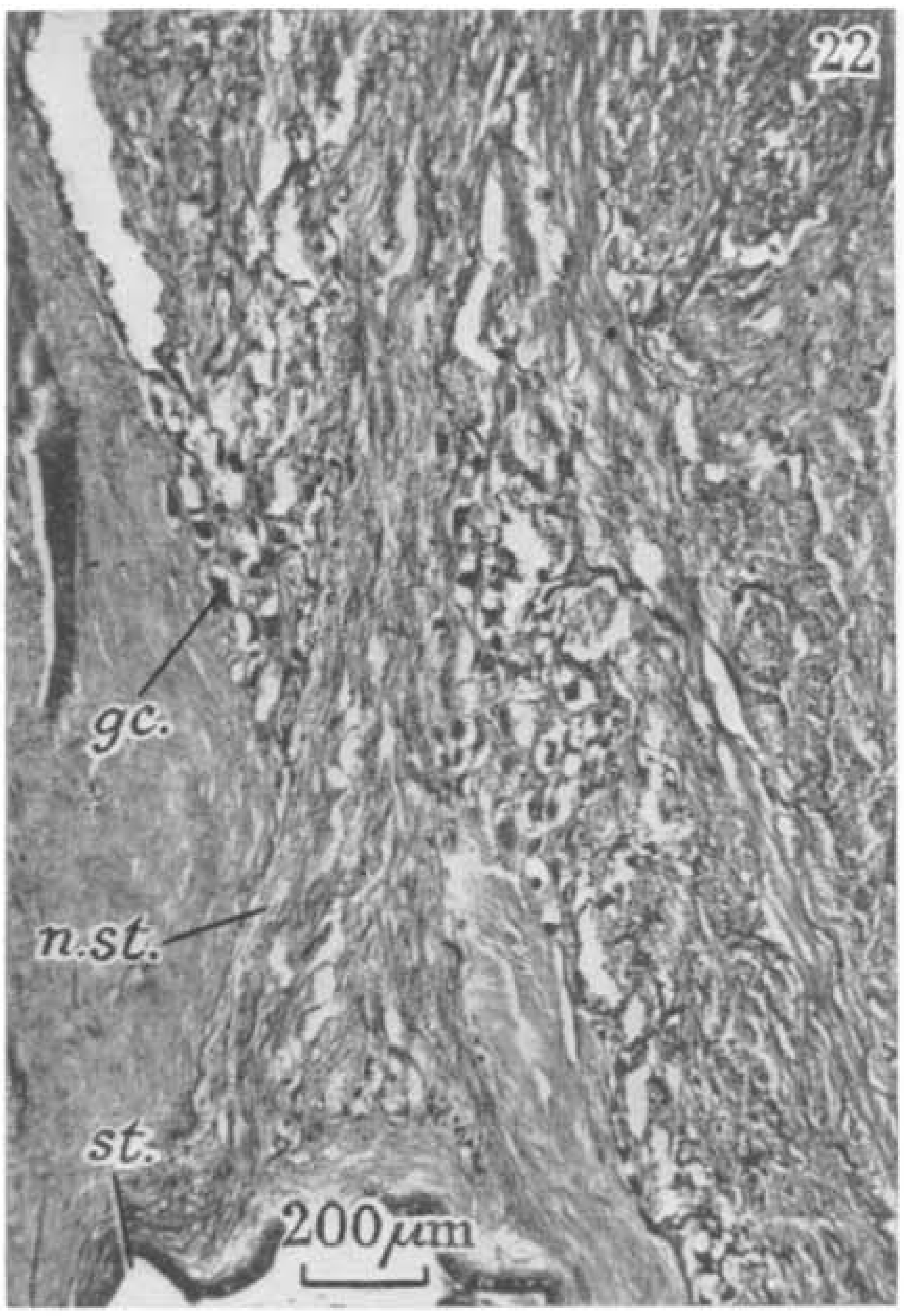
22
gc.
n.st.
st.
200 μm

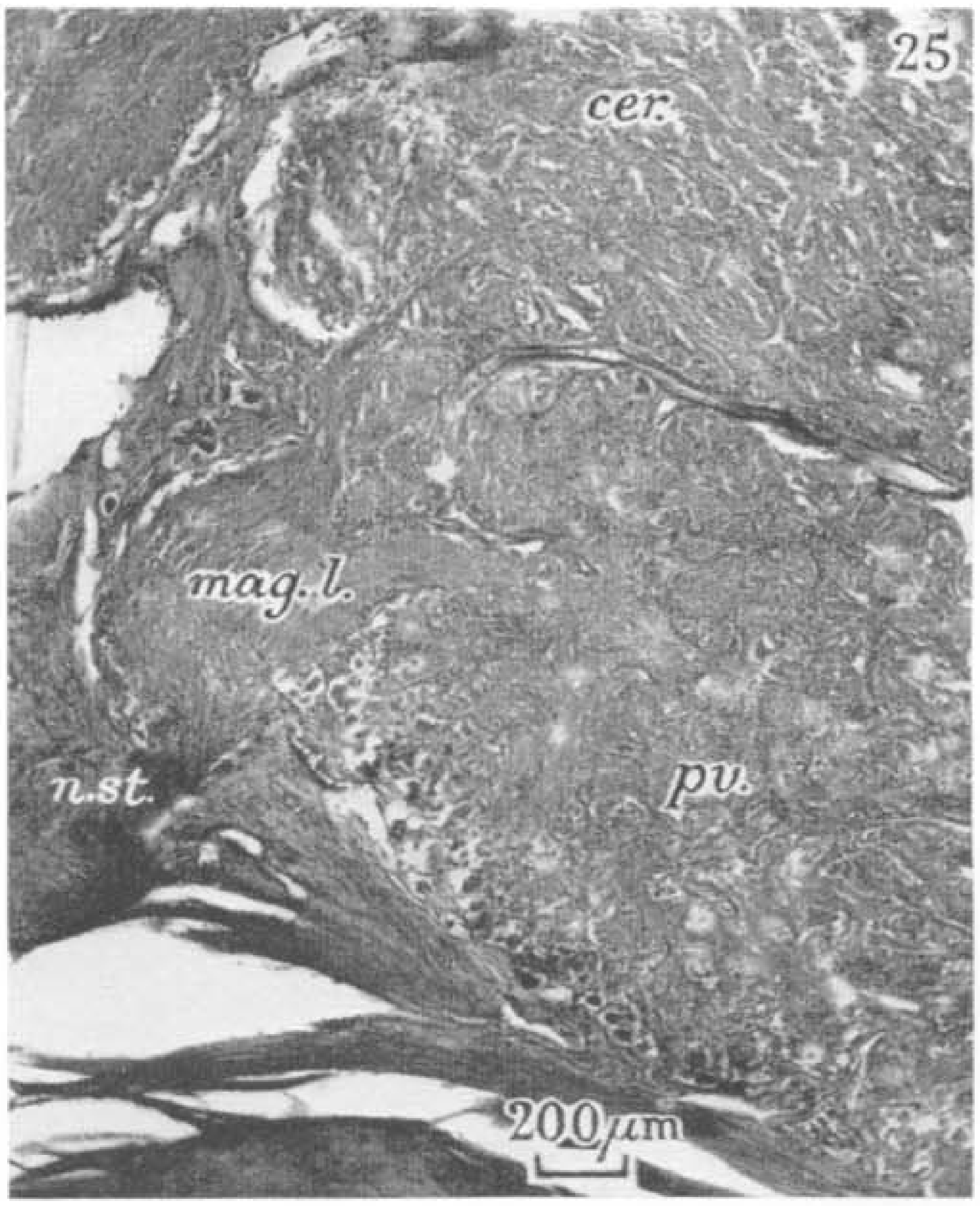
25
cer.
mag.l.
n.st.
pv.
200 μm

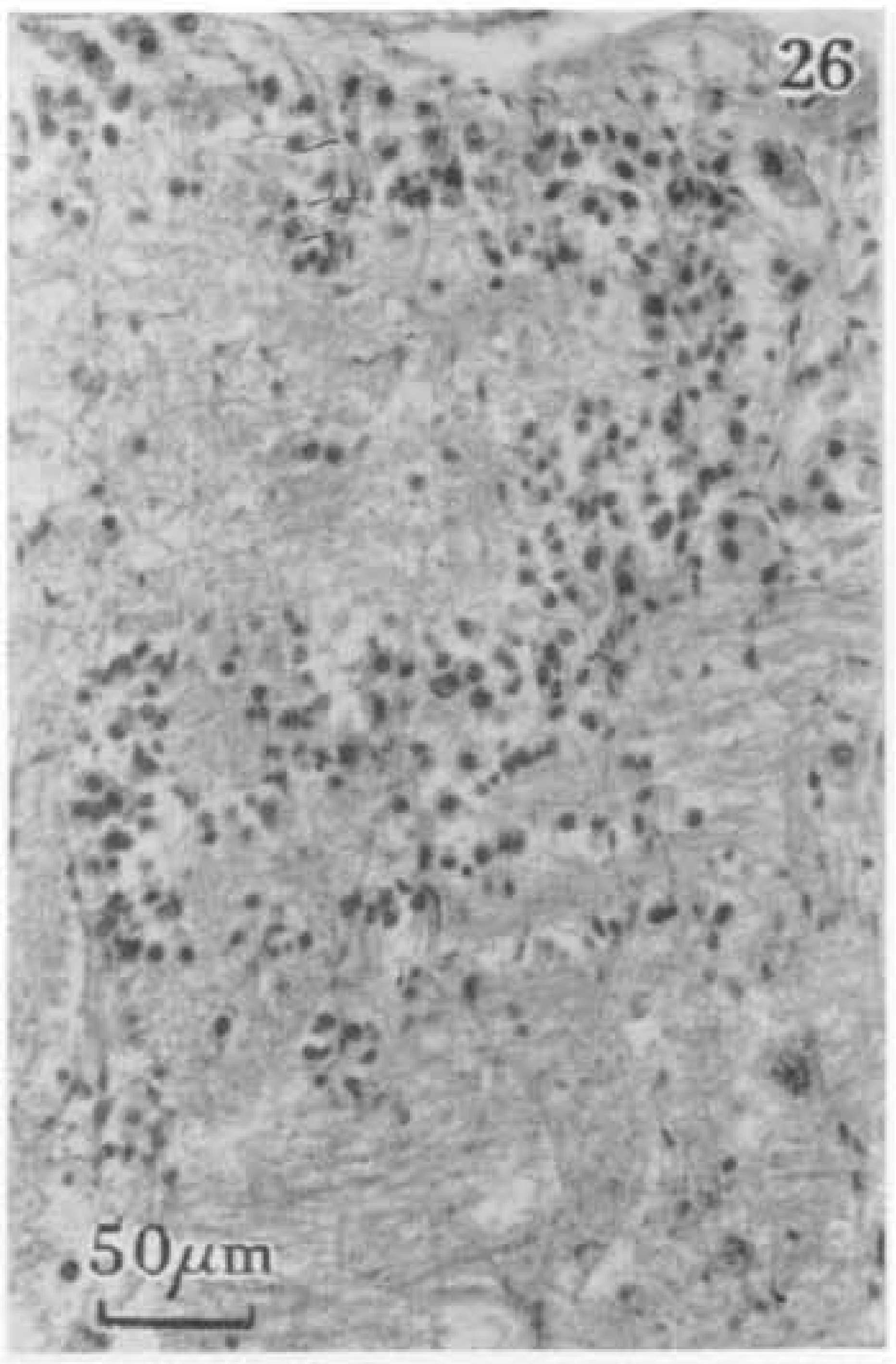
26
50 μm

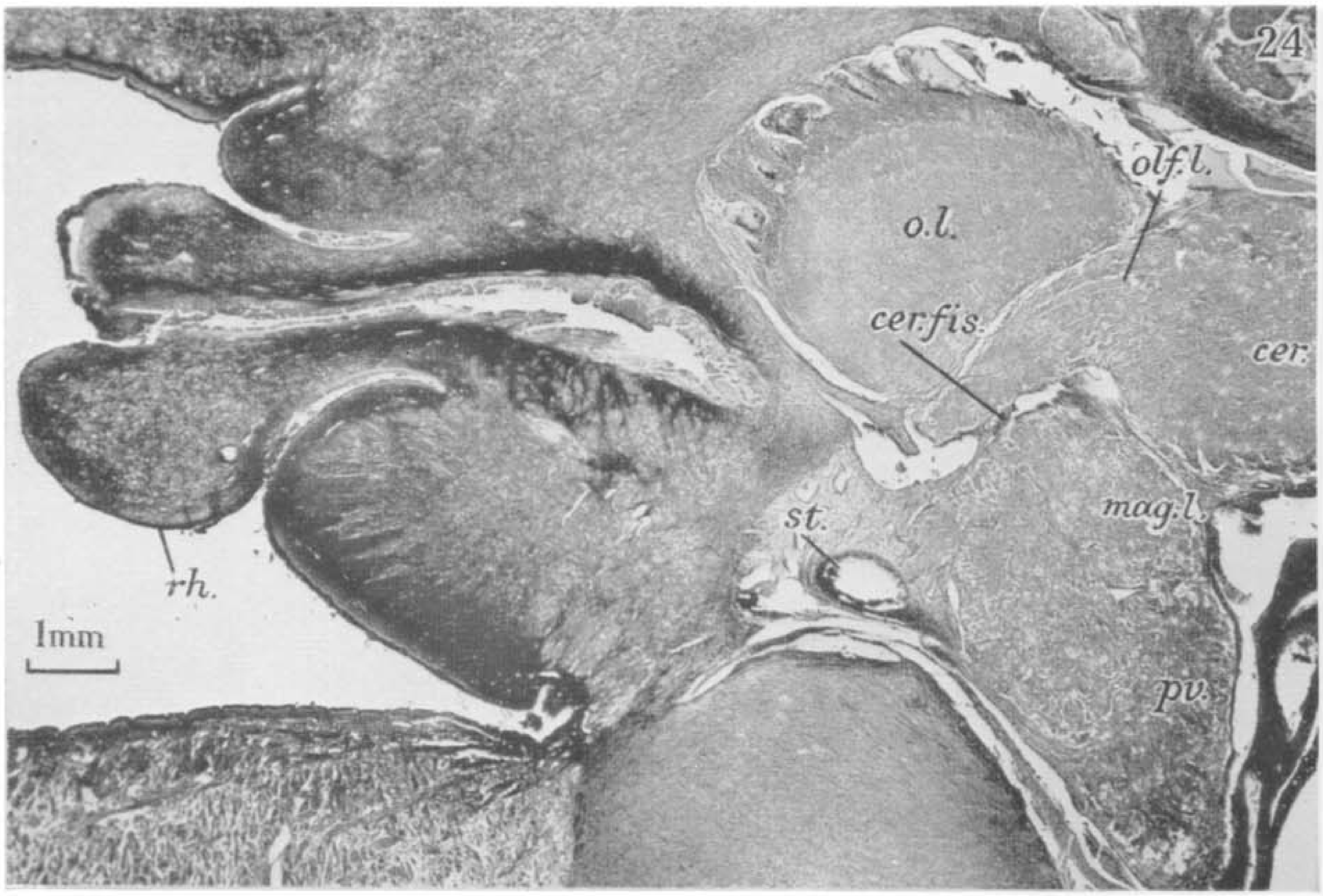
24
olf.l.
o.l.
cer.fis.
cer.
mag.l.
st.
rh.
1mm
pv.

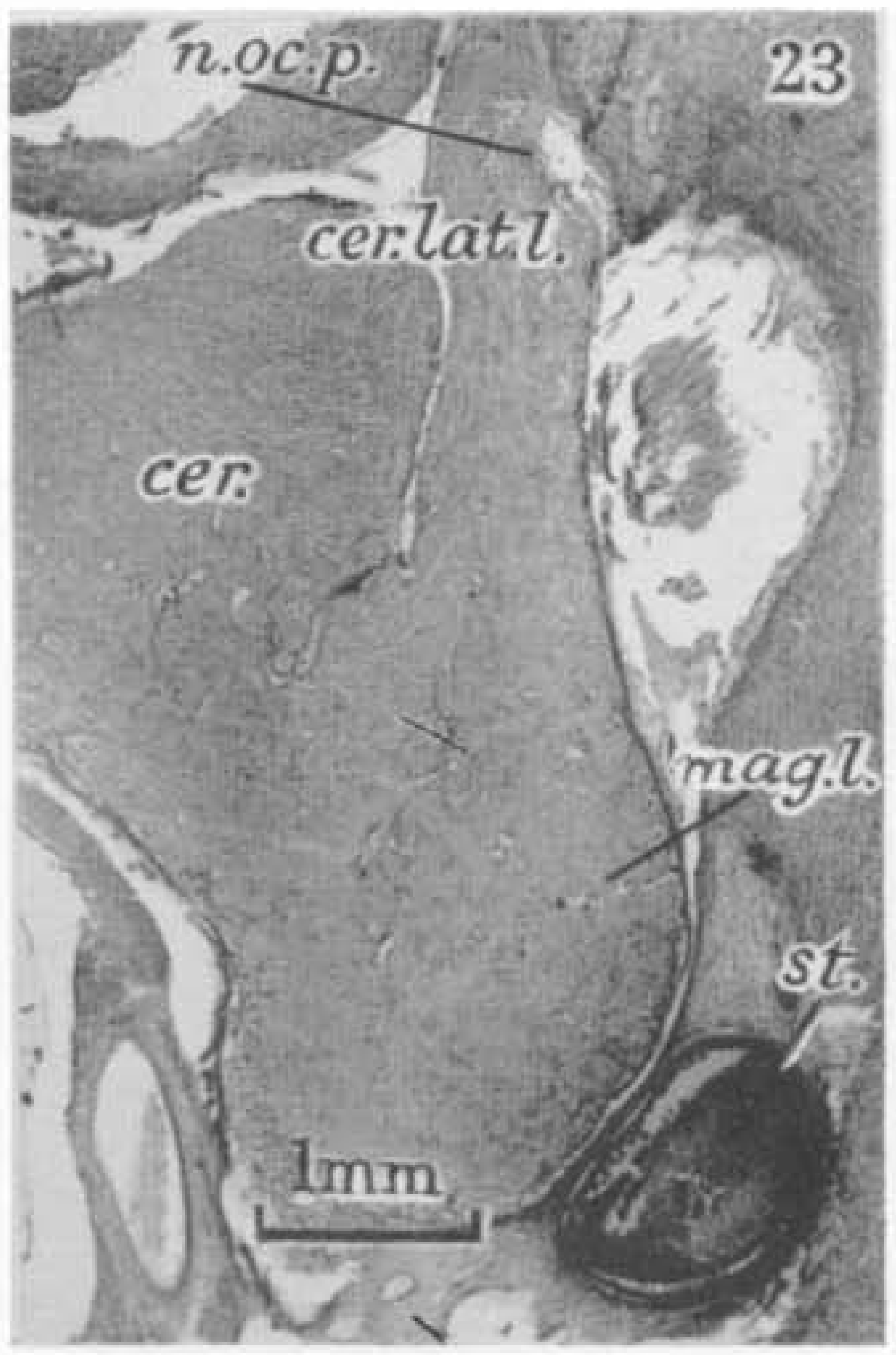
23
n.oc.p.
cer.lat.l.
cer.
mag.l.
st.
1mm


27
5μm

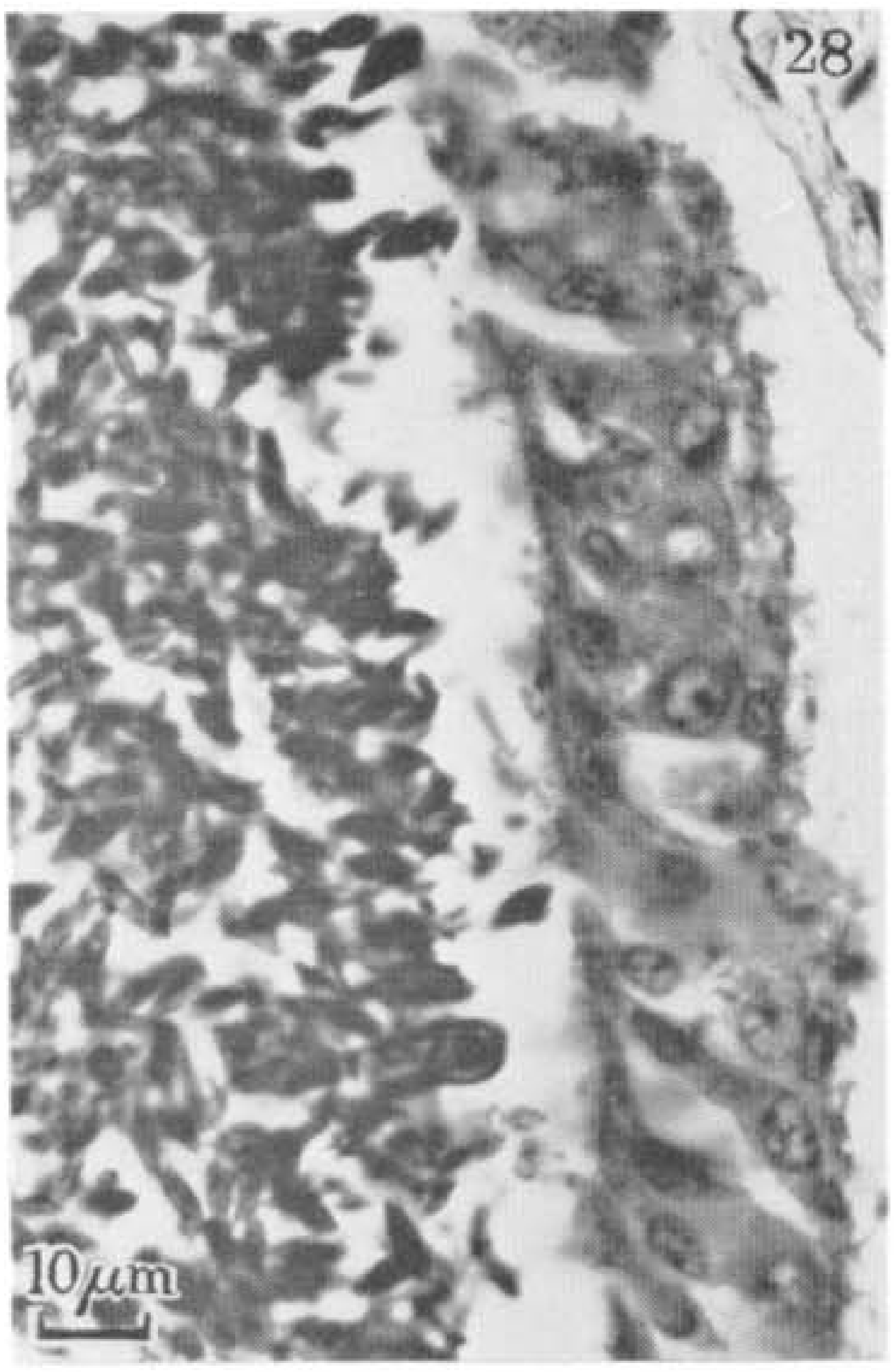
28
10μm


32
n.st.
mag.l.
st.
200μm

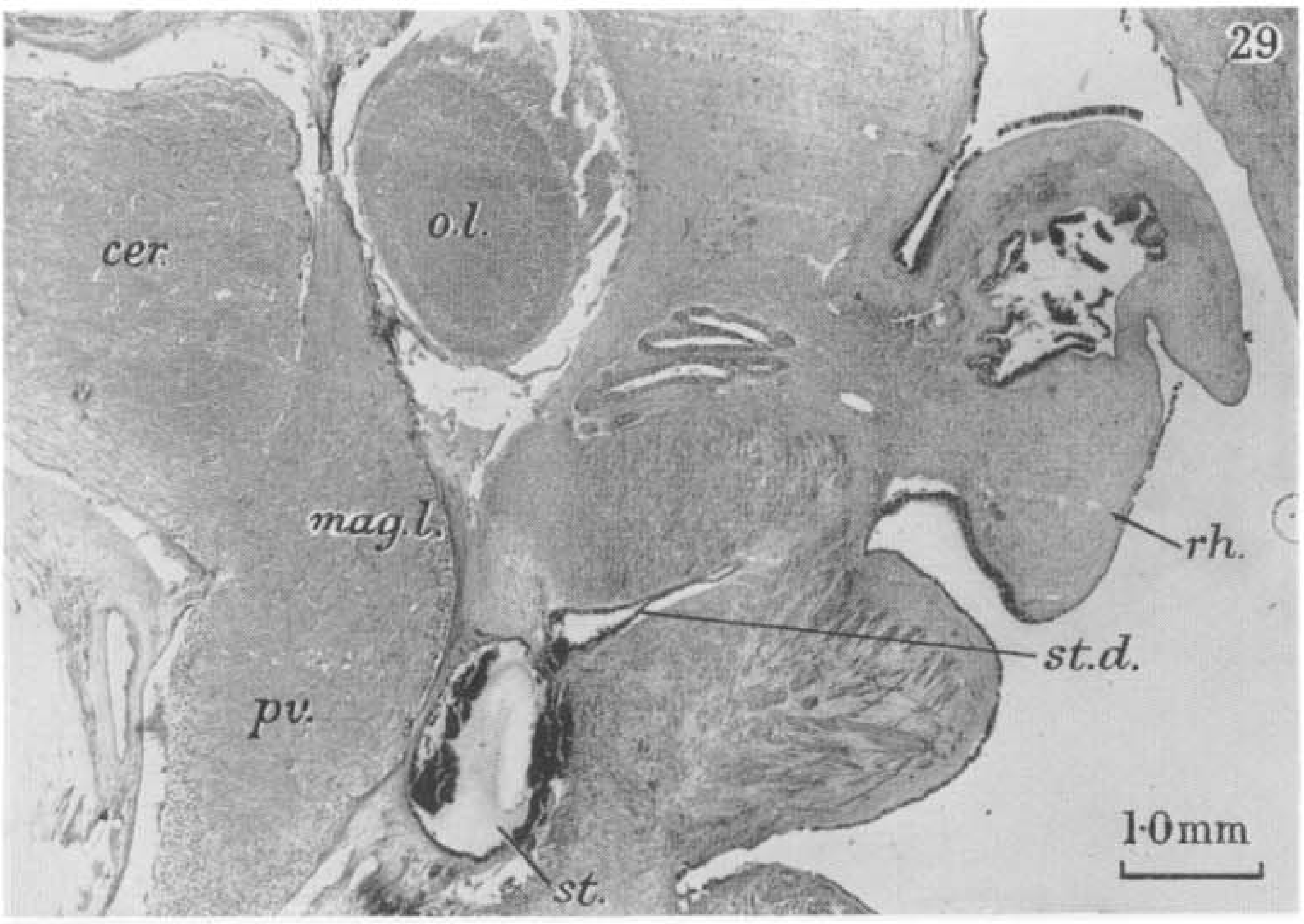
29
cer.
o.l.
mag.l.
rh.
st.d.
pv.
st.
1·0mm

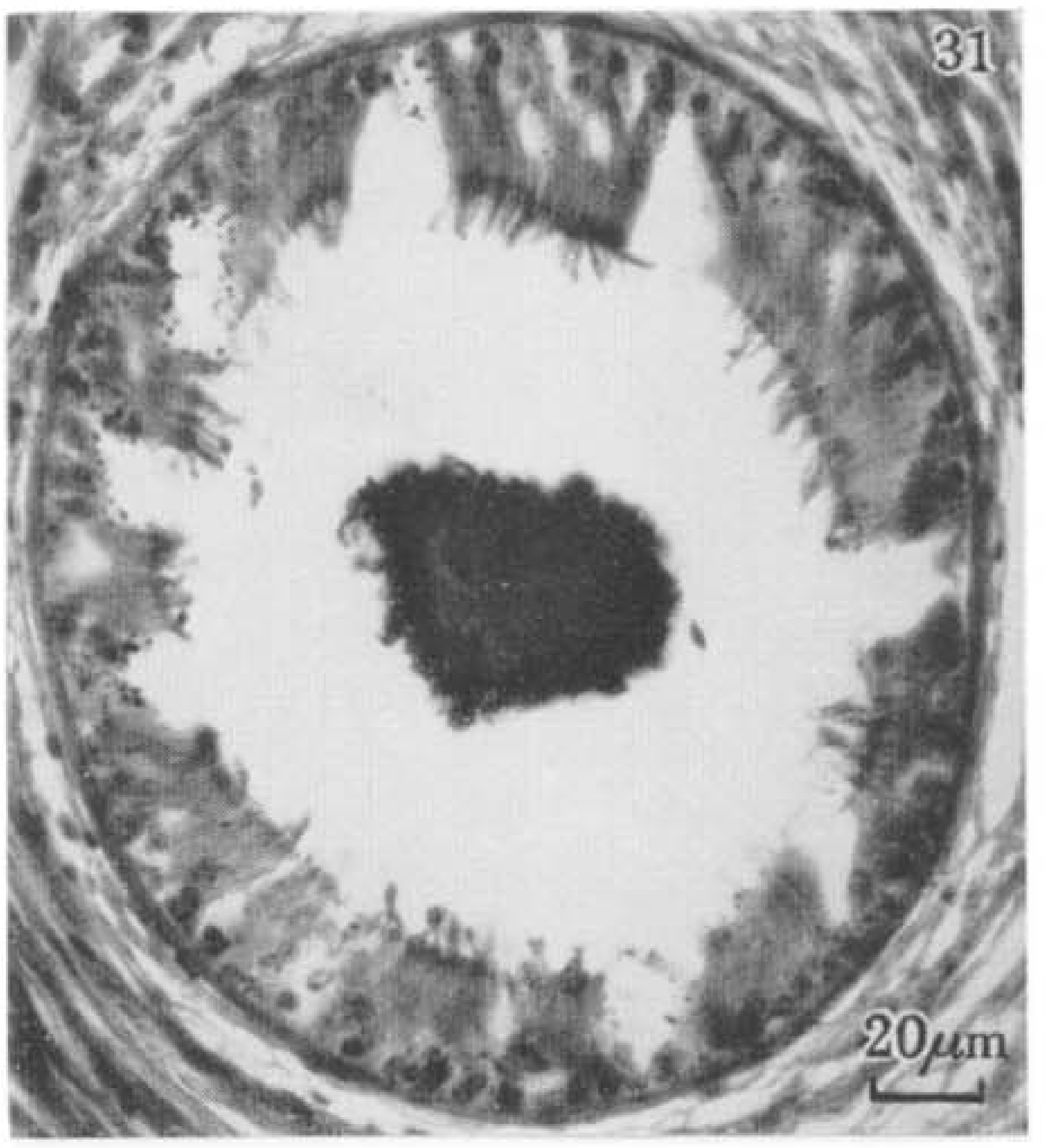
31
20μm

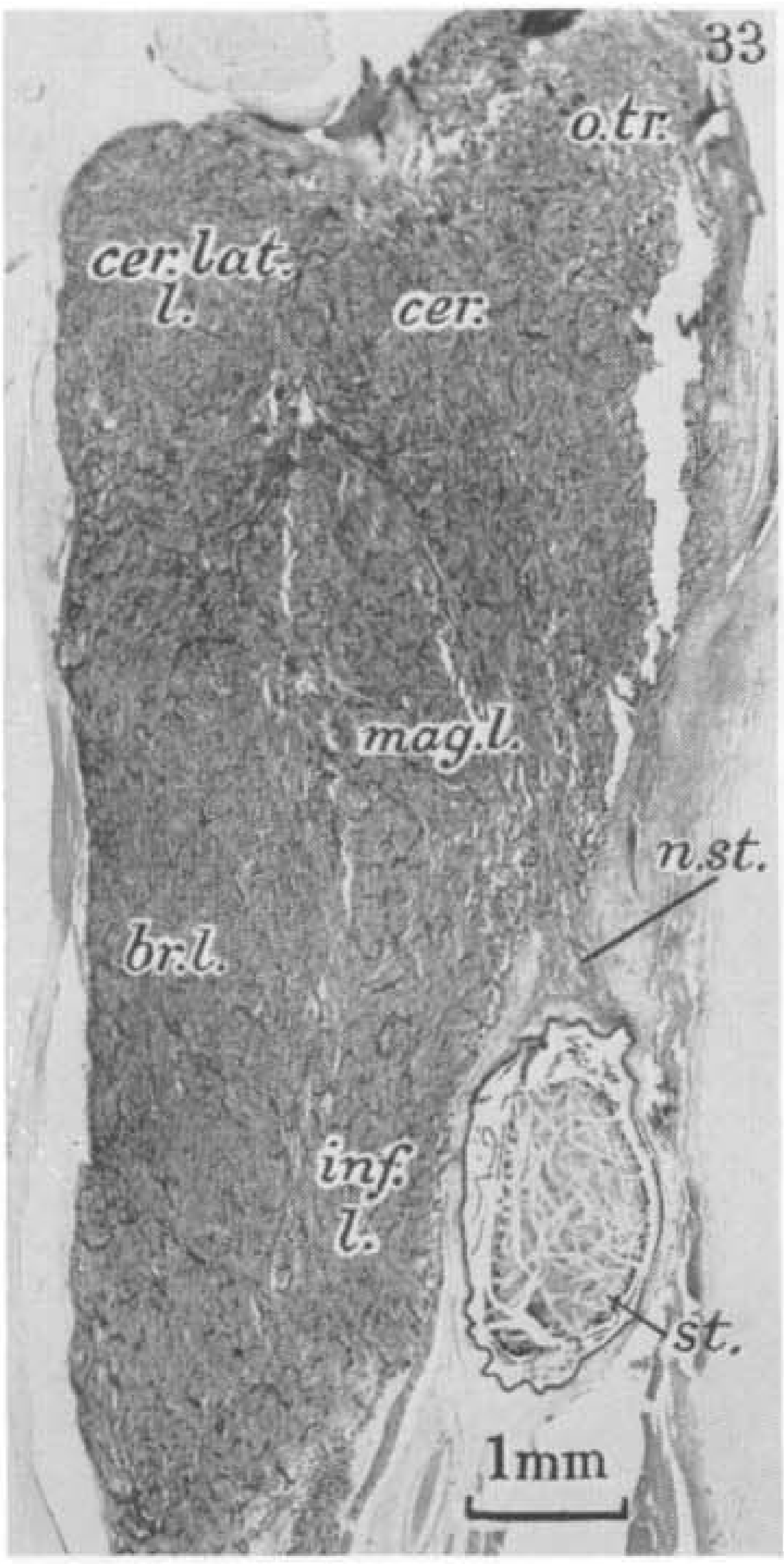
33
o.tr.
cer.lat.
l.
cer.
mag.l.
n.st.
br.l.
inf.
l.
st.
1mm

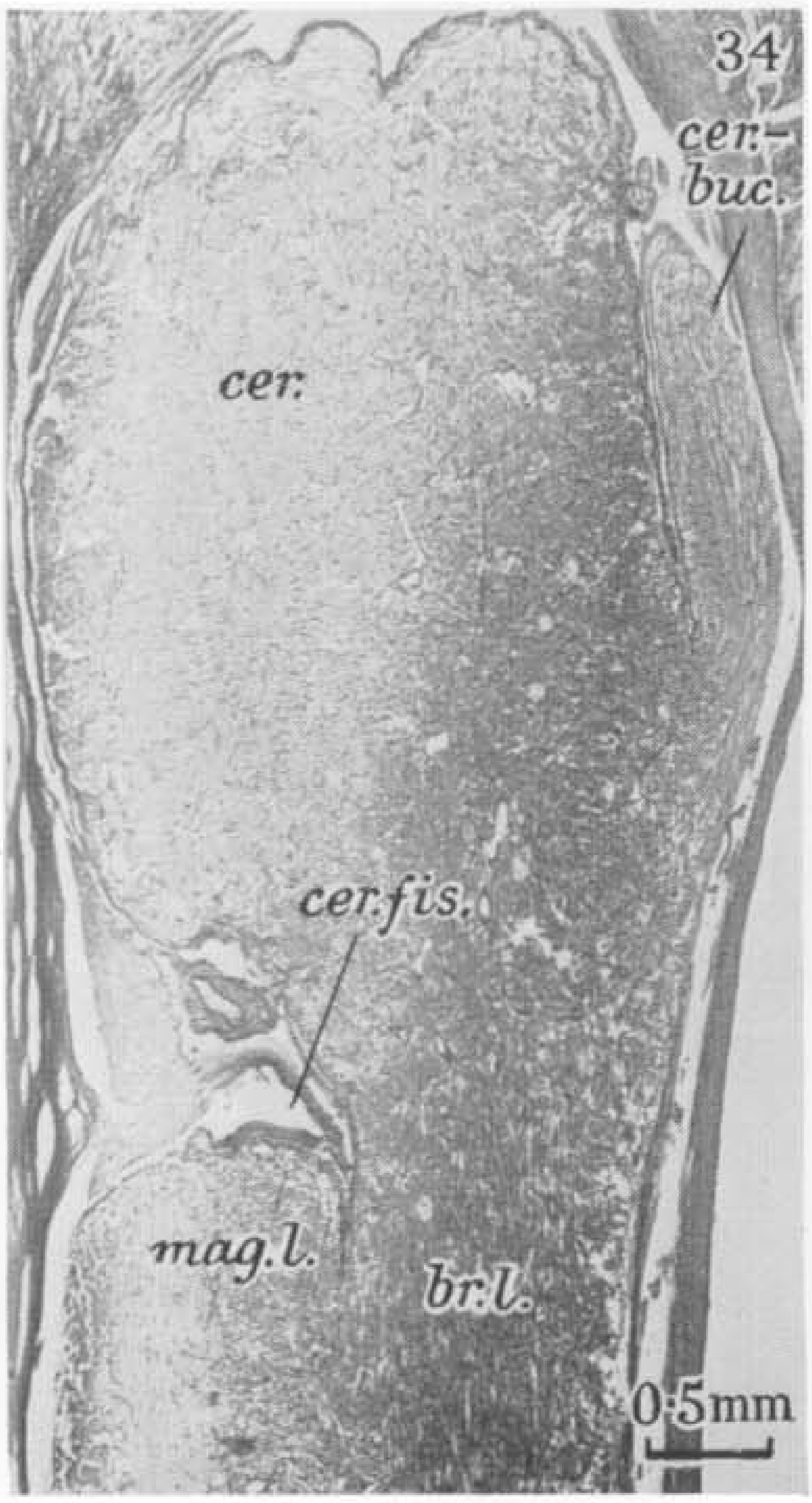
34
cer.-
buc.
cer.
cer.fis.
mag.l.
br.l.
0·5mm


30
st.d.
200μm

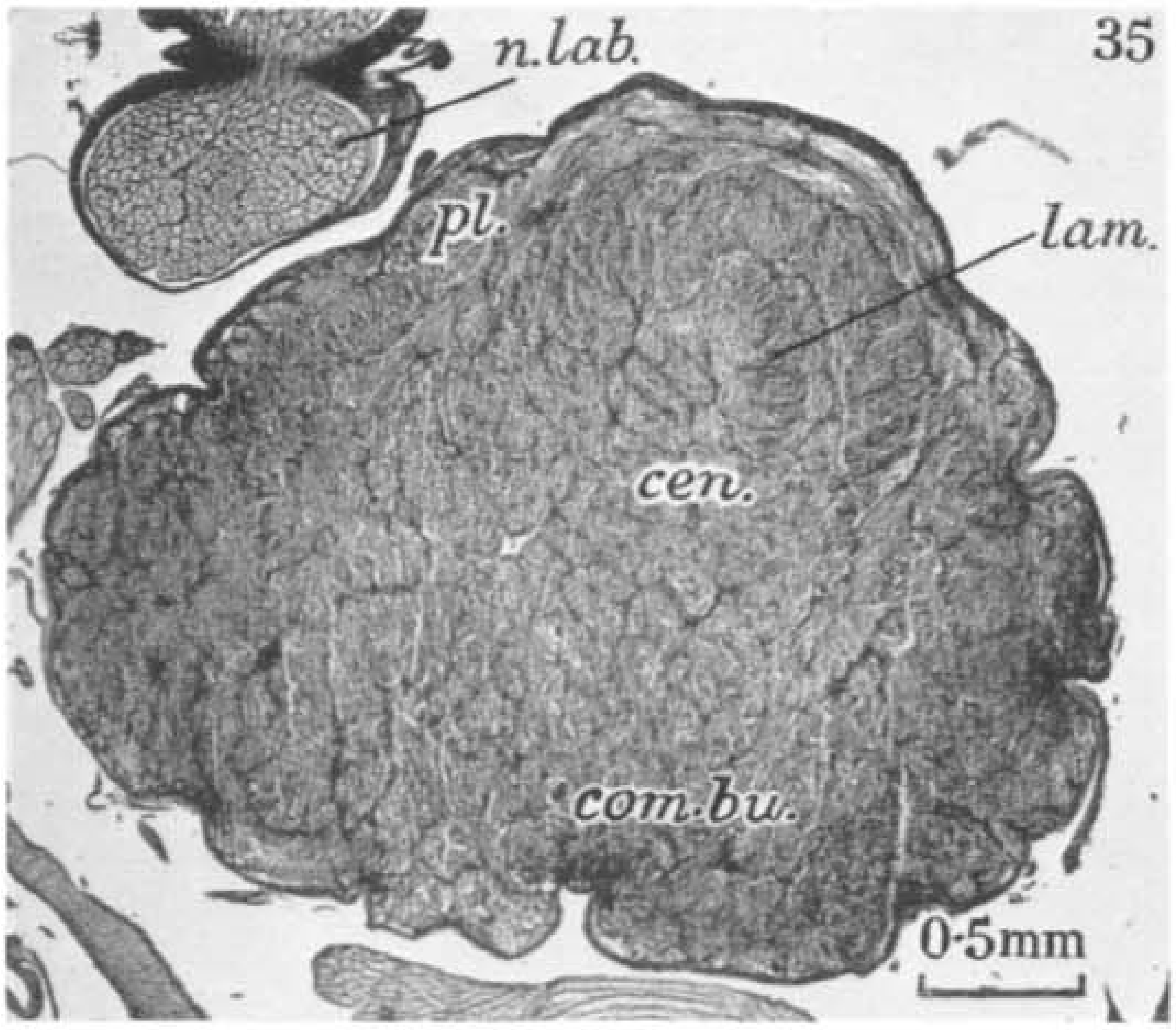
35
n.lab.
pl.
lam.
cen.
com.bu.
0·5mm

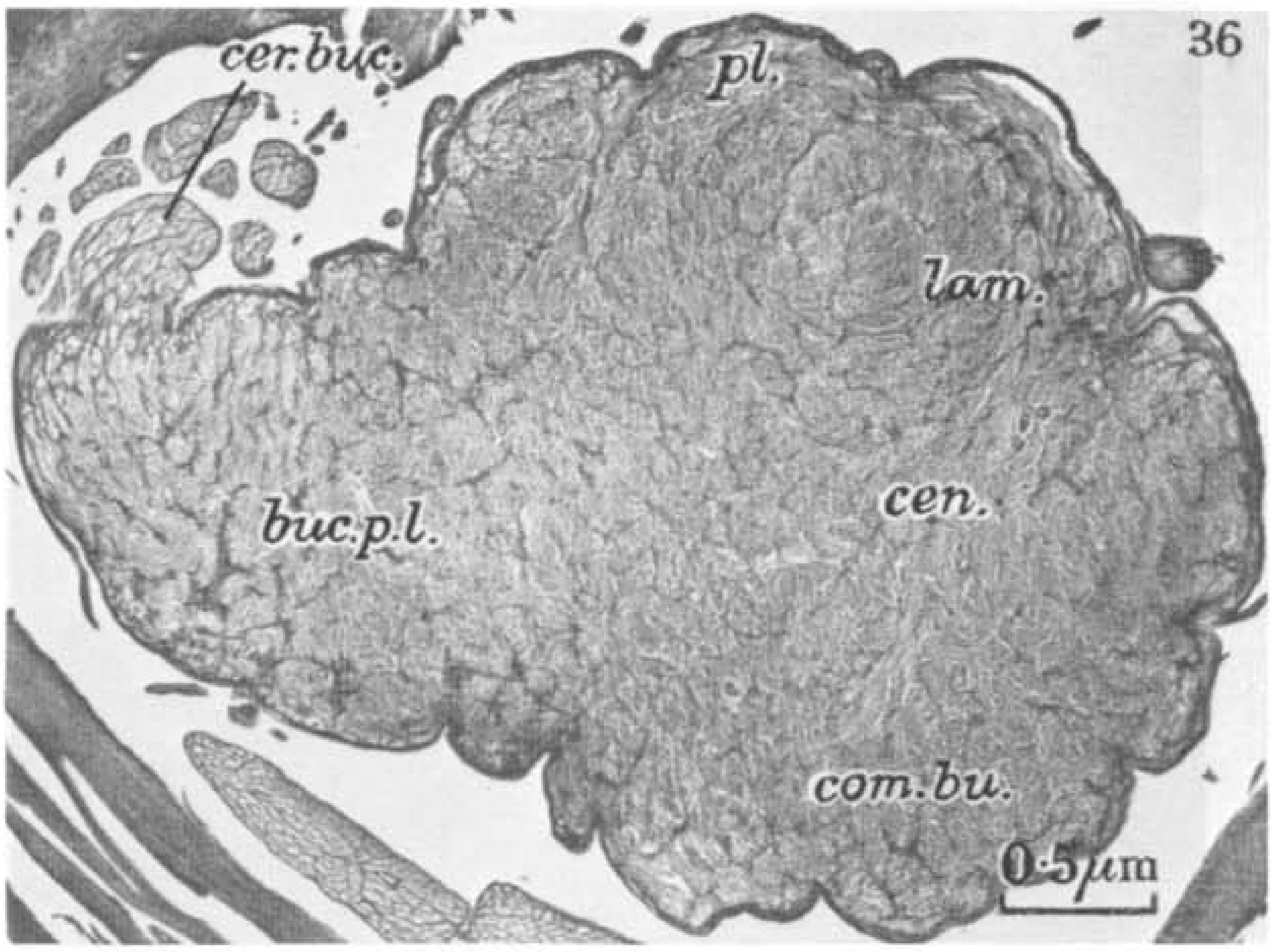
36
cer.buc.
pl.
lam.
buc.p.l.
cen.
com.bu.
0·5μm

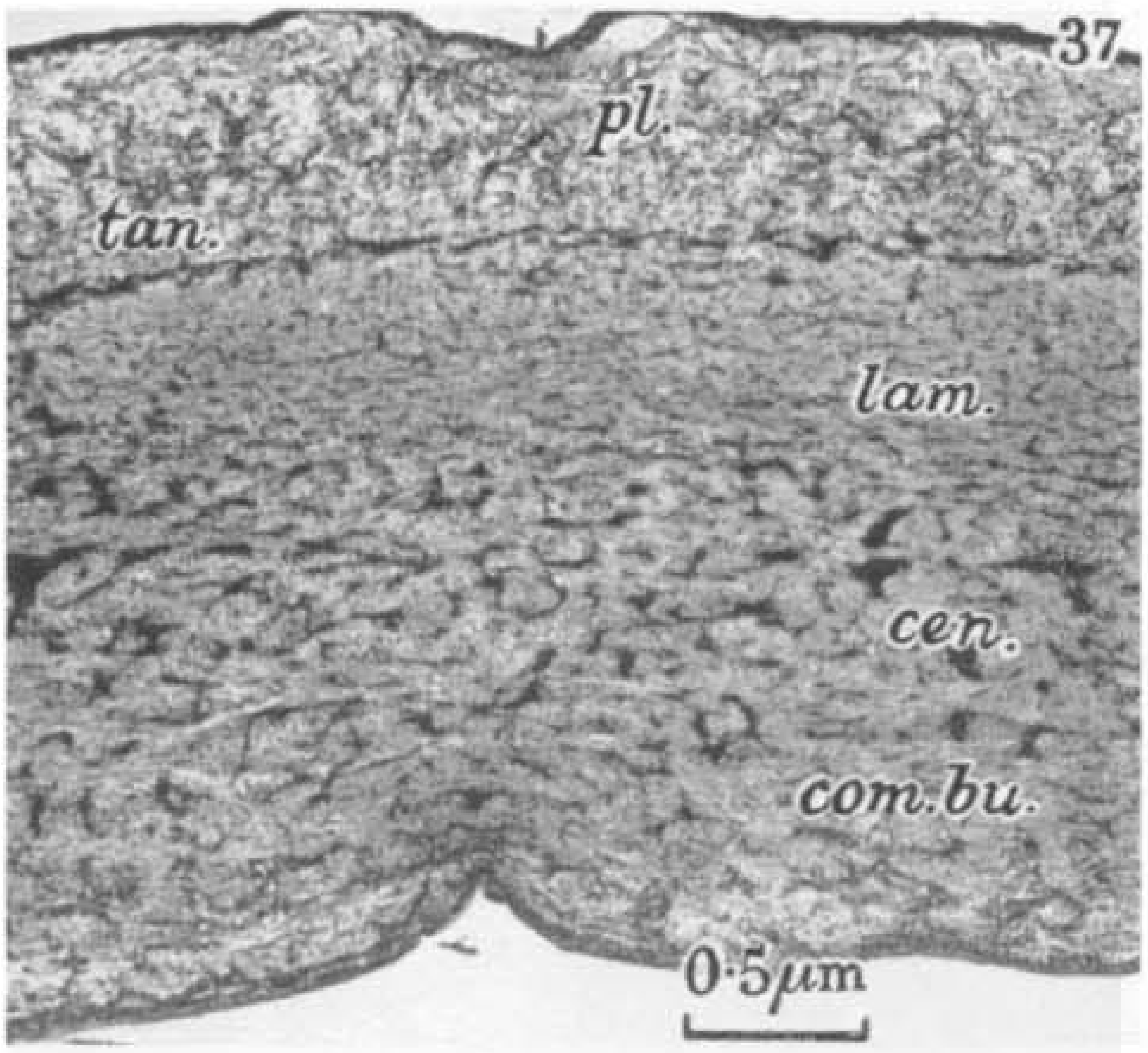
37
pl.
tan.
lam.
cen.
com.bu.
0·5μm

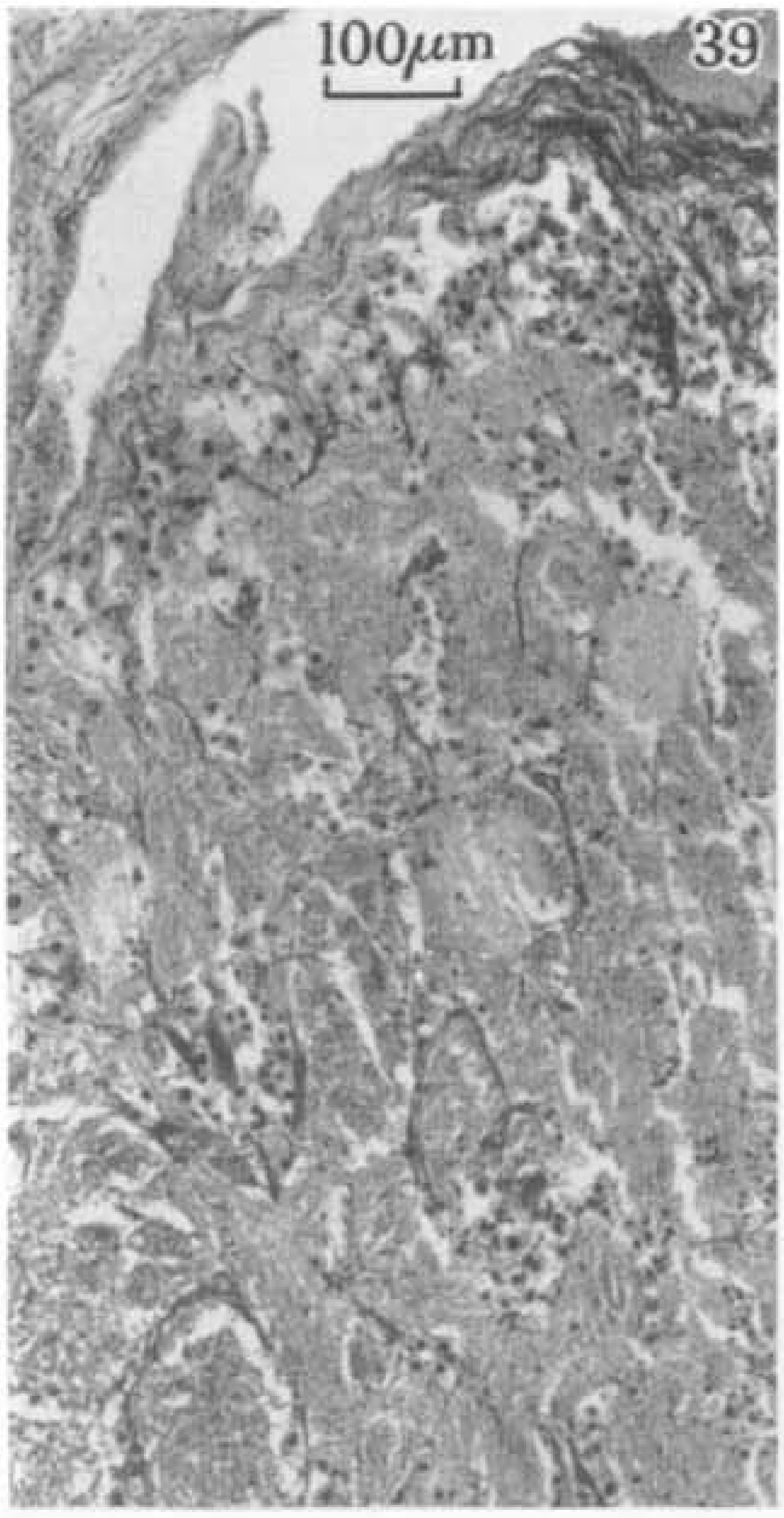
100μm
39

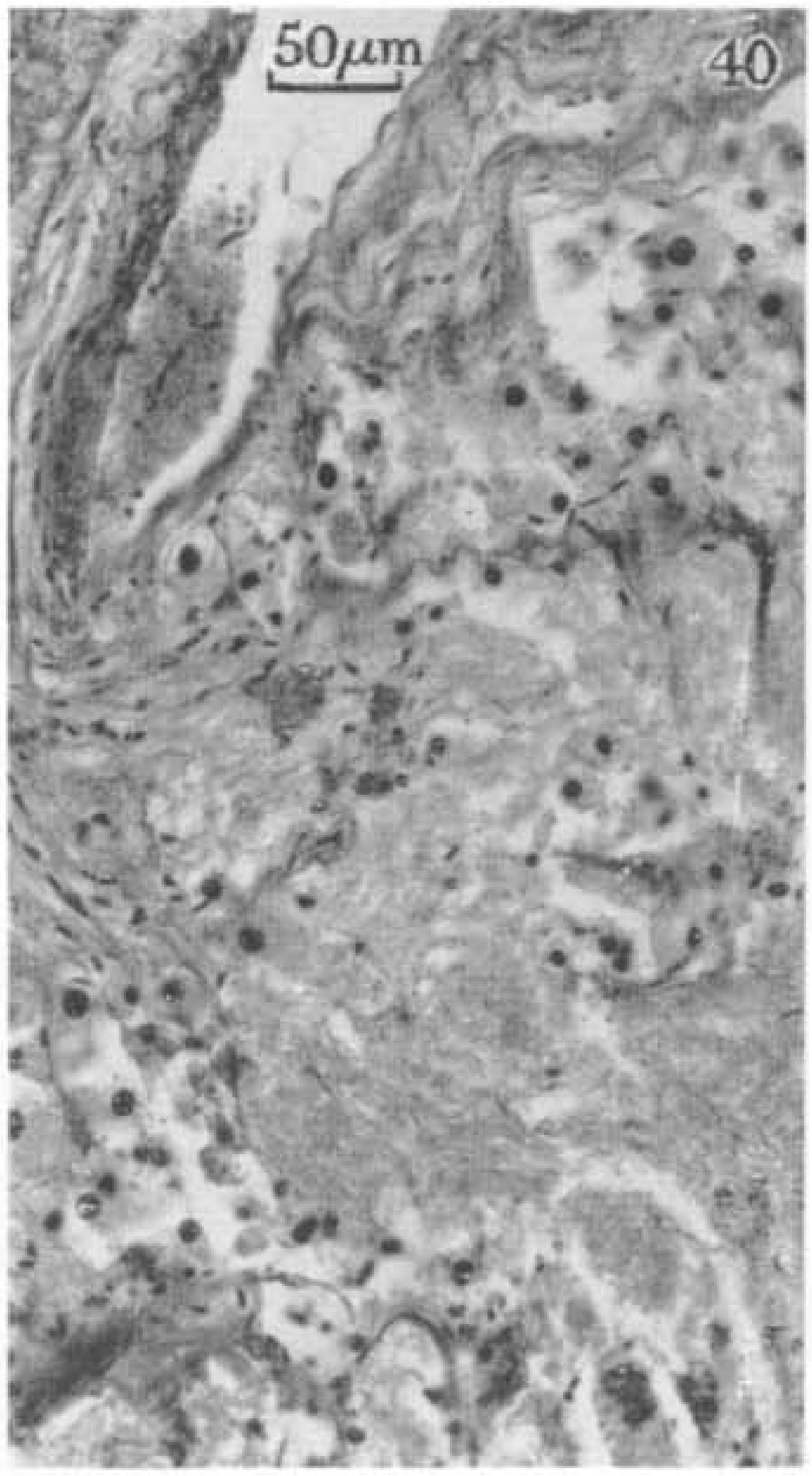
50μm
40

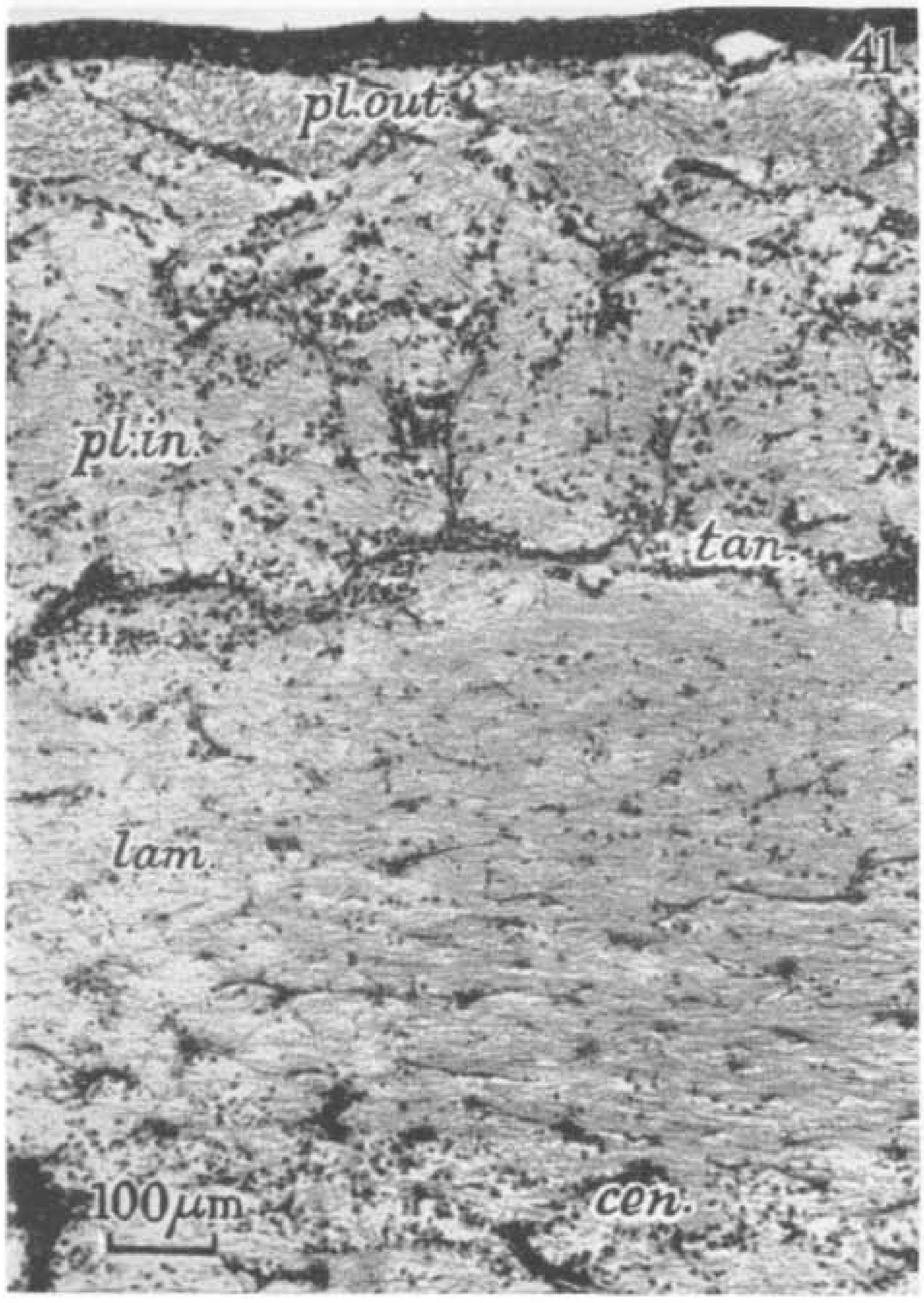
41
pl.out.
pl.in.
tan.
lam.
100μm
cen.

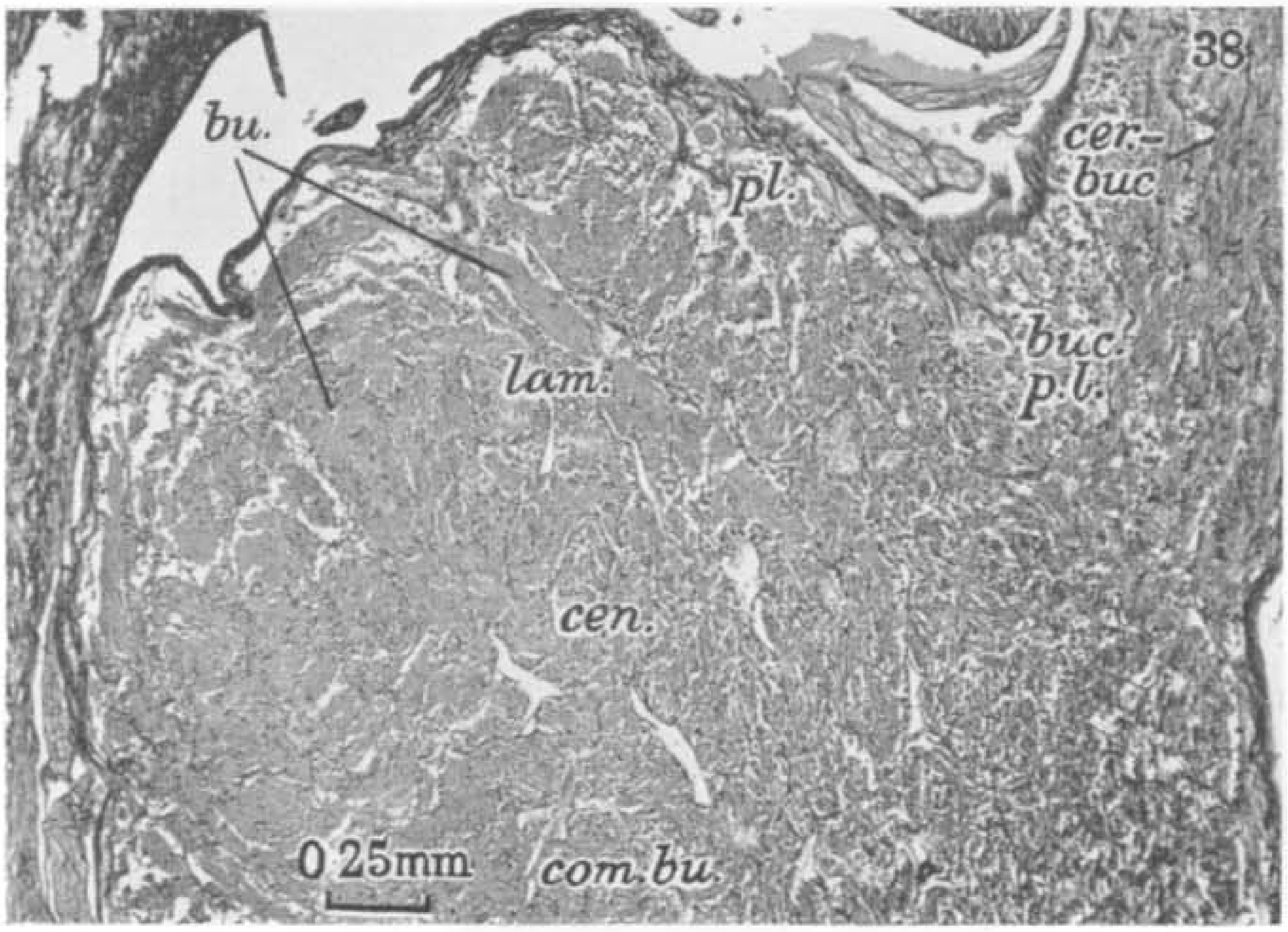
38
bu.
pl.
cer.-
buc
buc.
p.l.
lam.
cen.
0 25mm
com.bu.

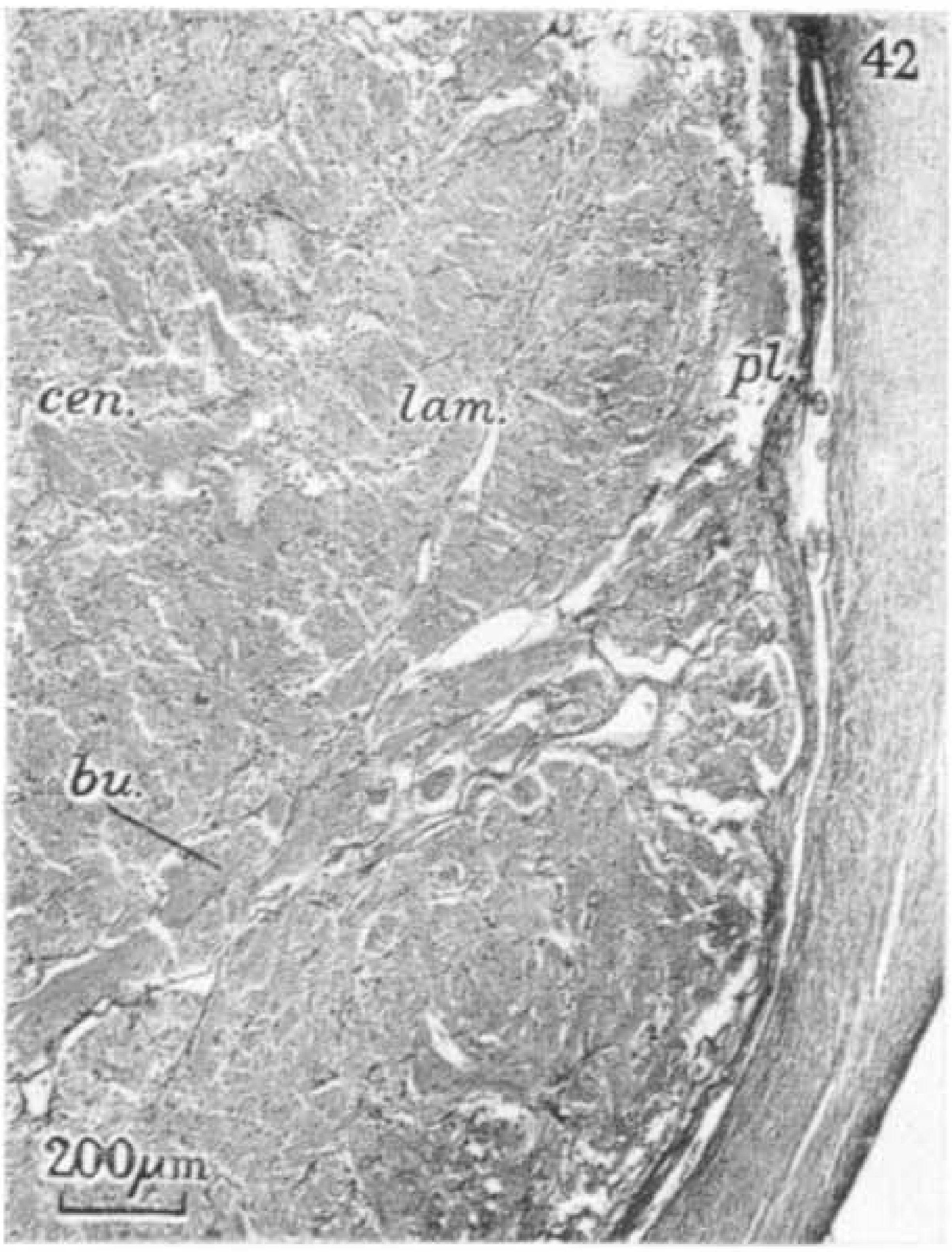
42
cen.
lam.
pl.
bu.
200μm

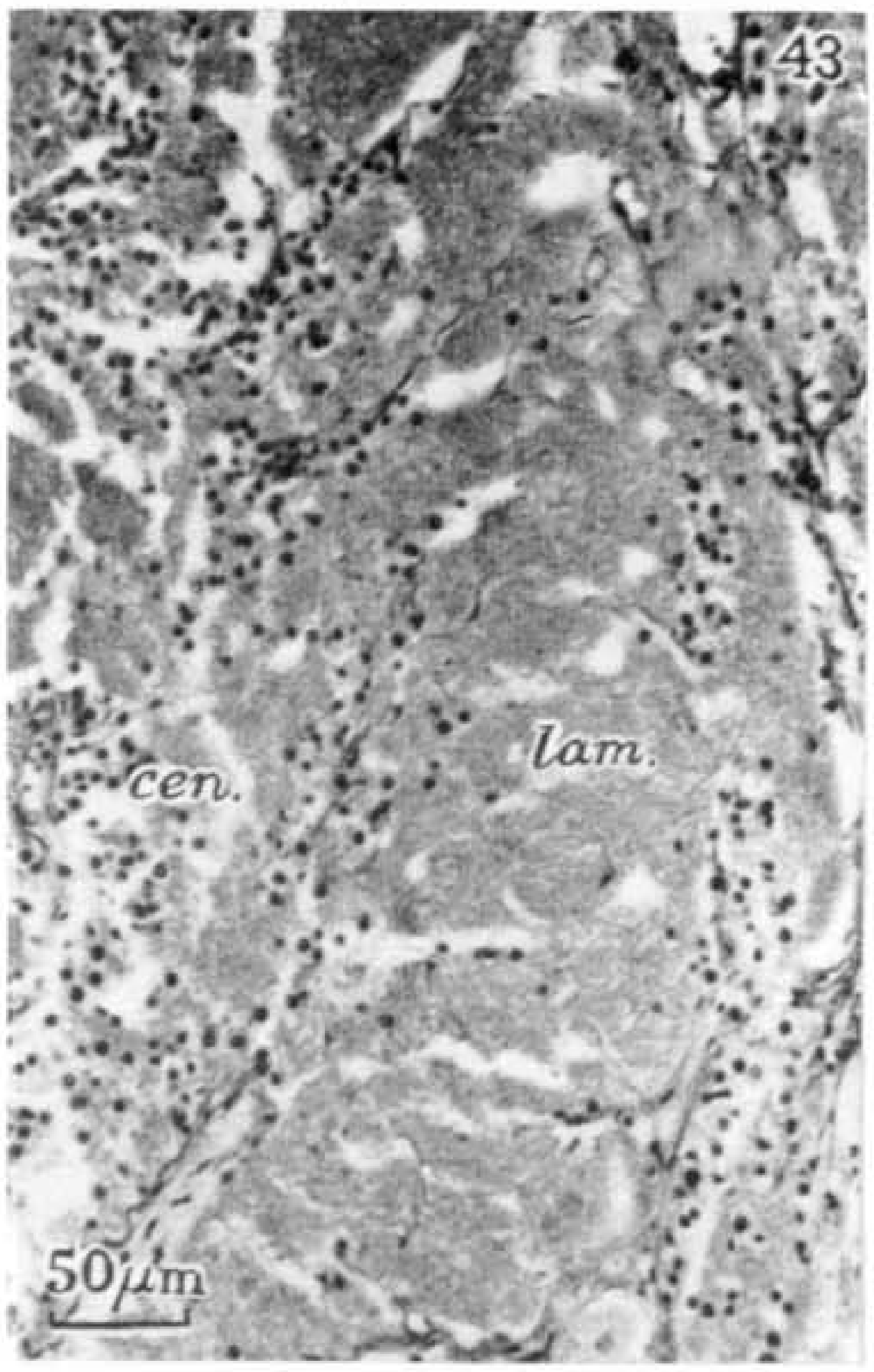
43
cen.
lam.
50μm

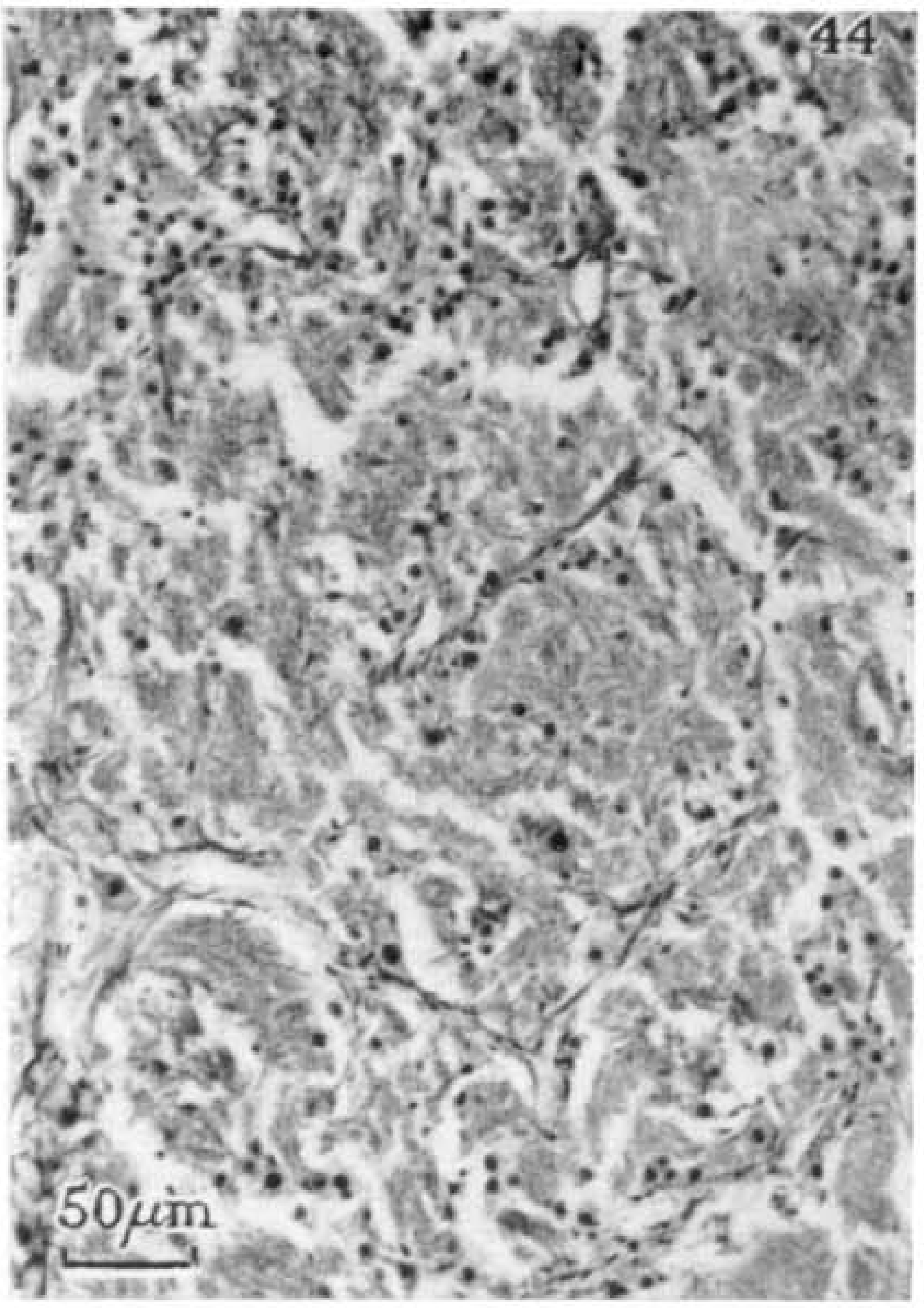
44
50μm

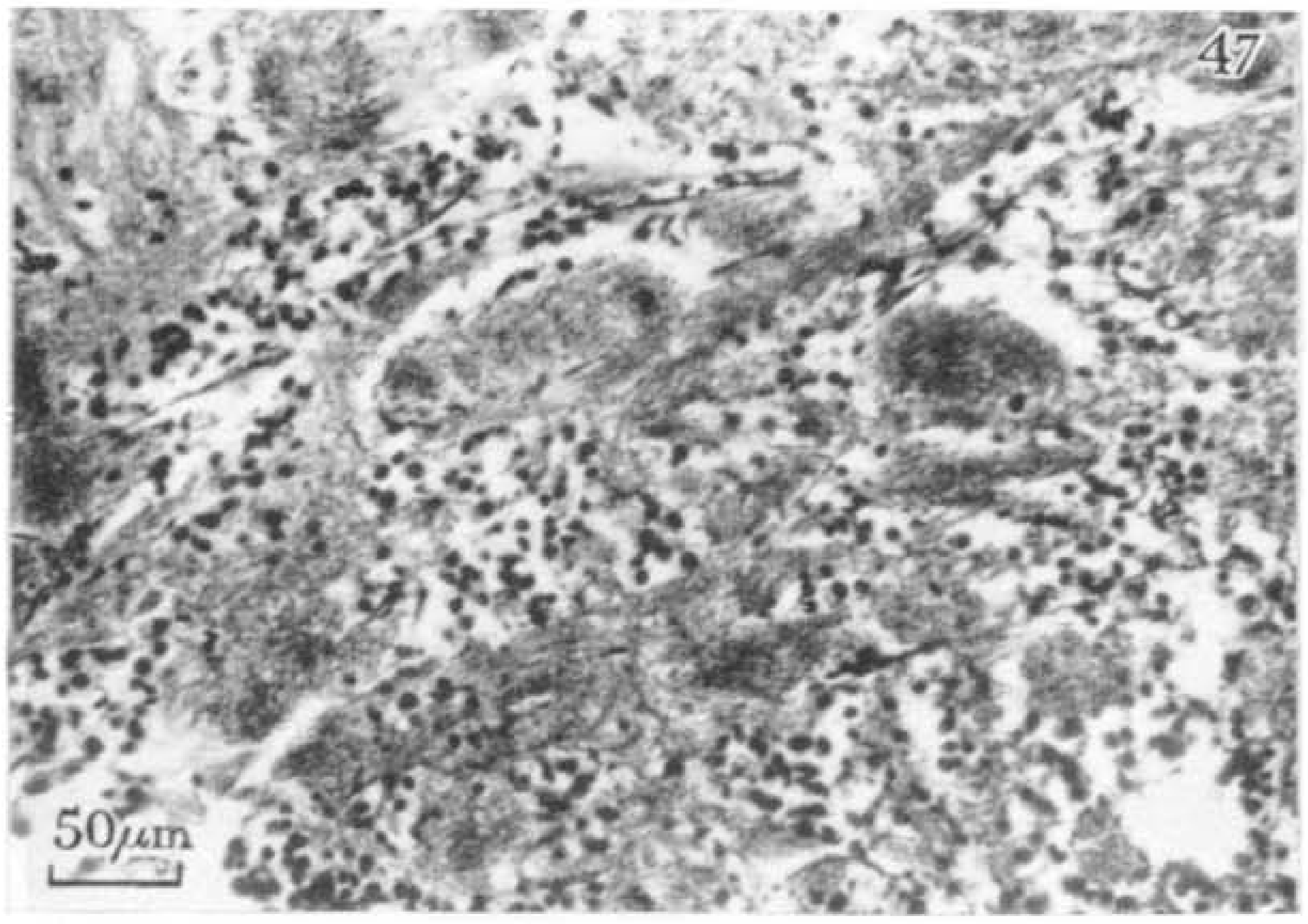
47
50μm

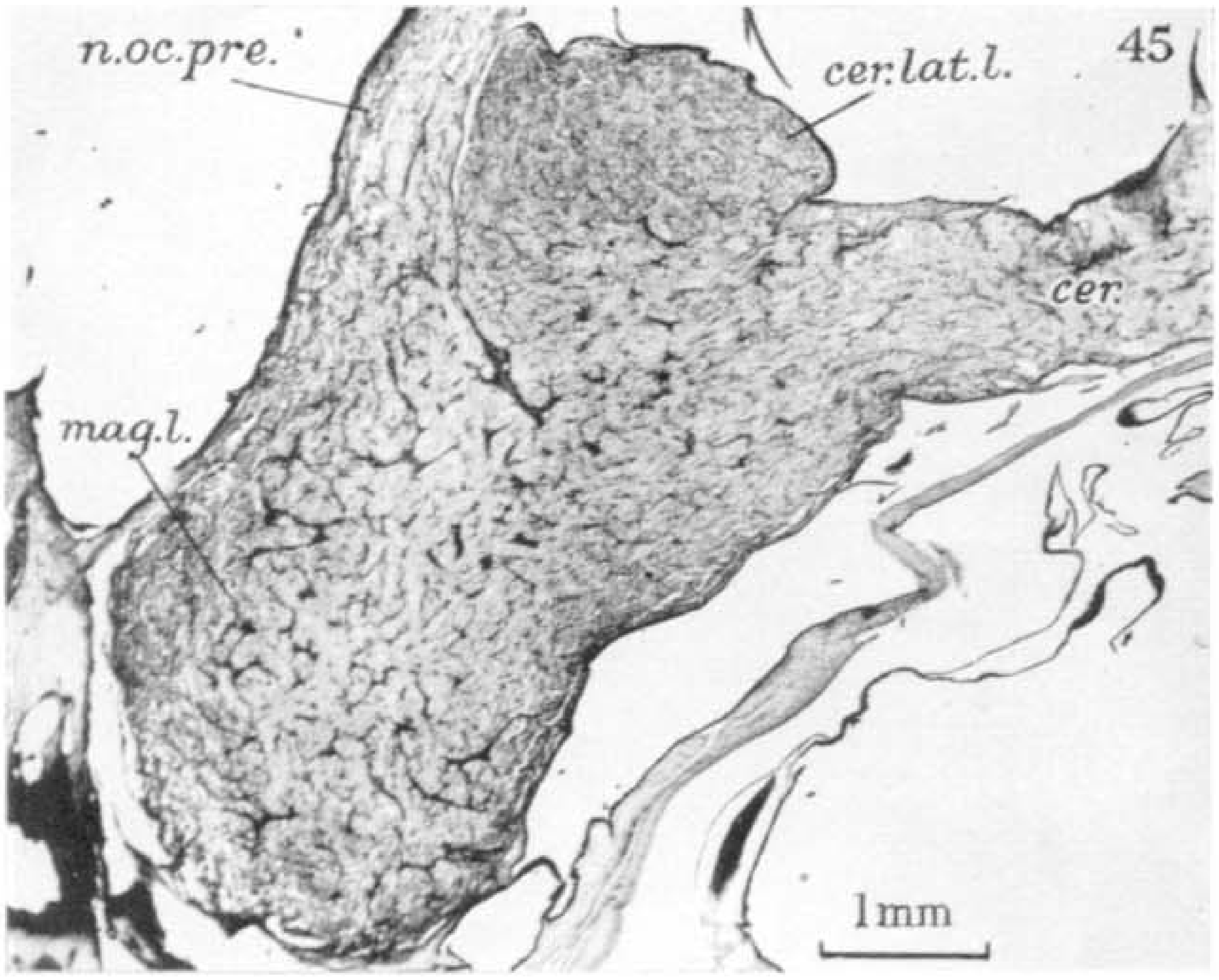
n.oc.pre.
cer.lat.l.
45
cer.
mag.l.
1mm


0·5mm
46
o.l.
cer.
lat.l.
br.n.fib.
br.l.
n.br.

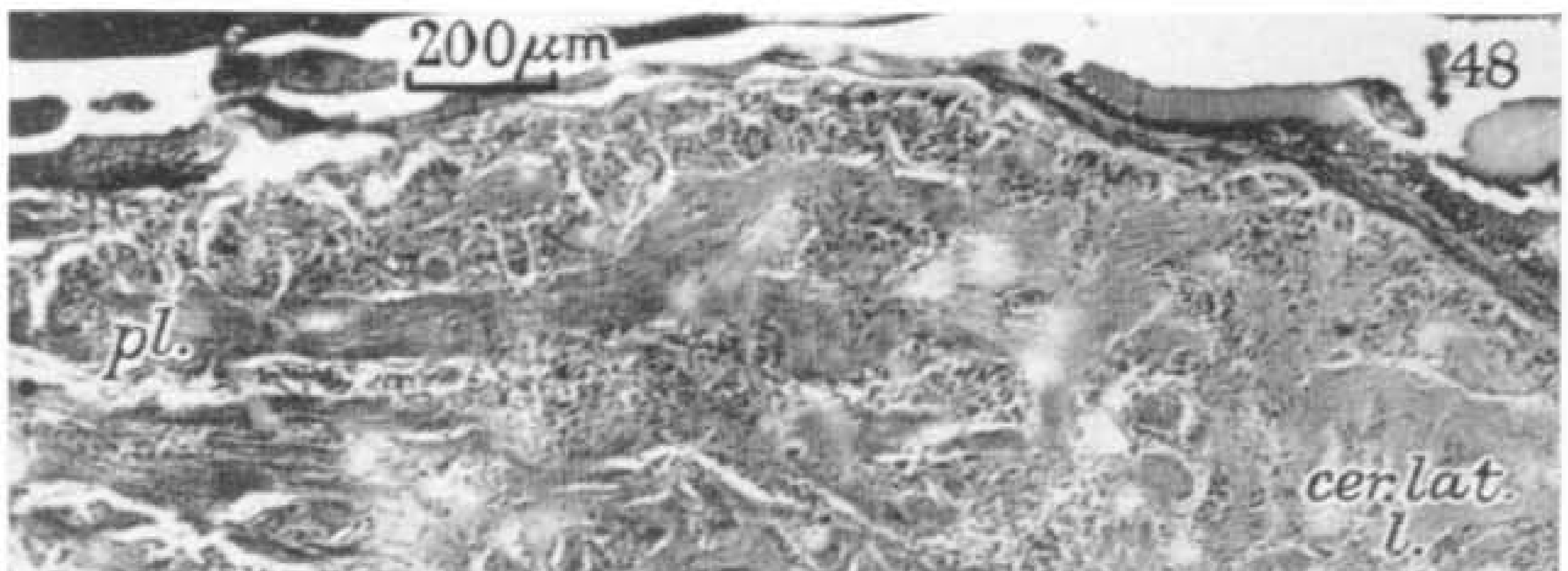
200μm
48
pl.
cer.lat.
l.

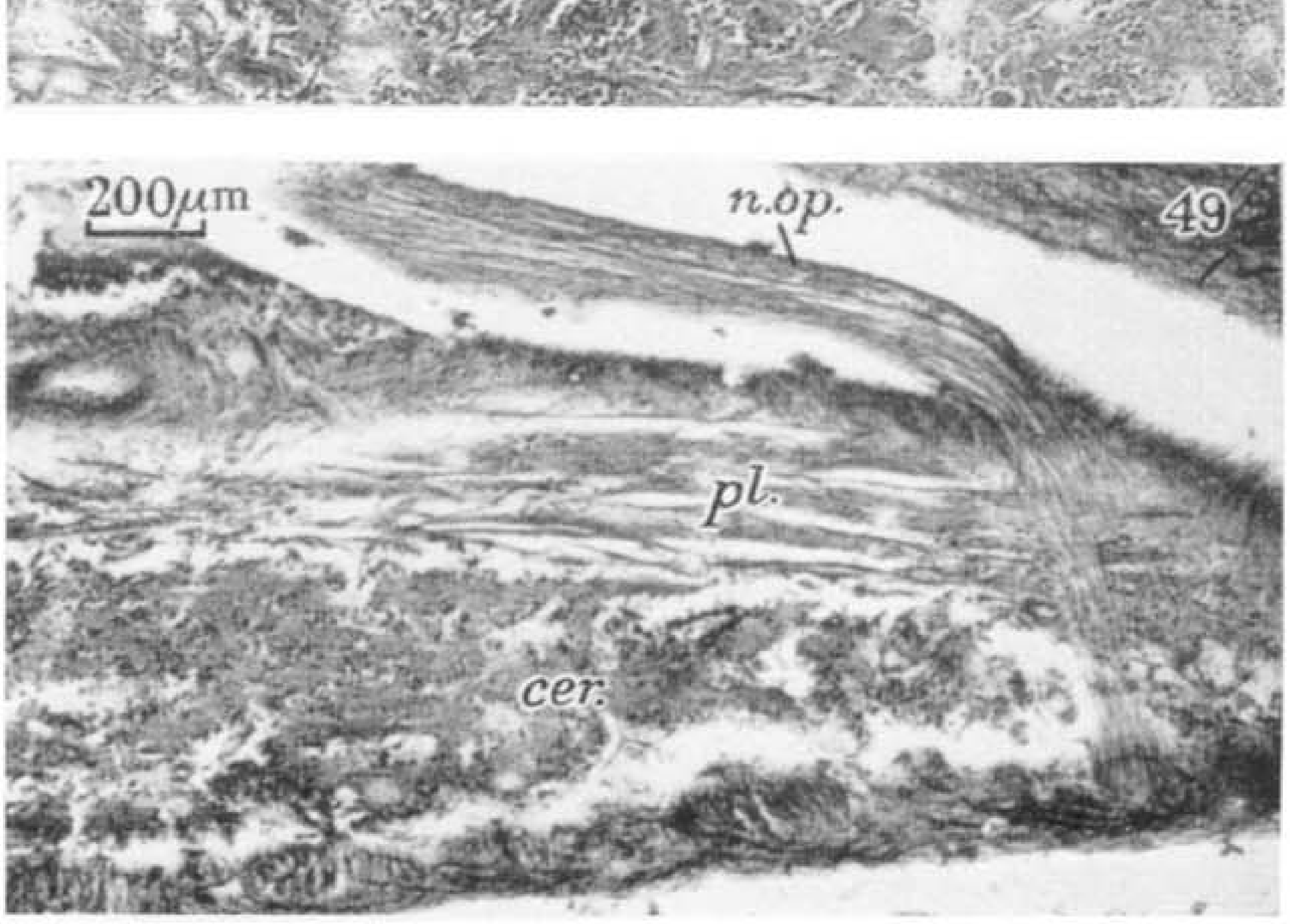
200μm
n.op.
49
pl.
cer.

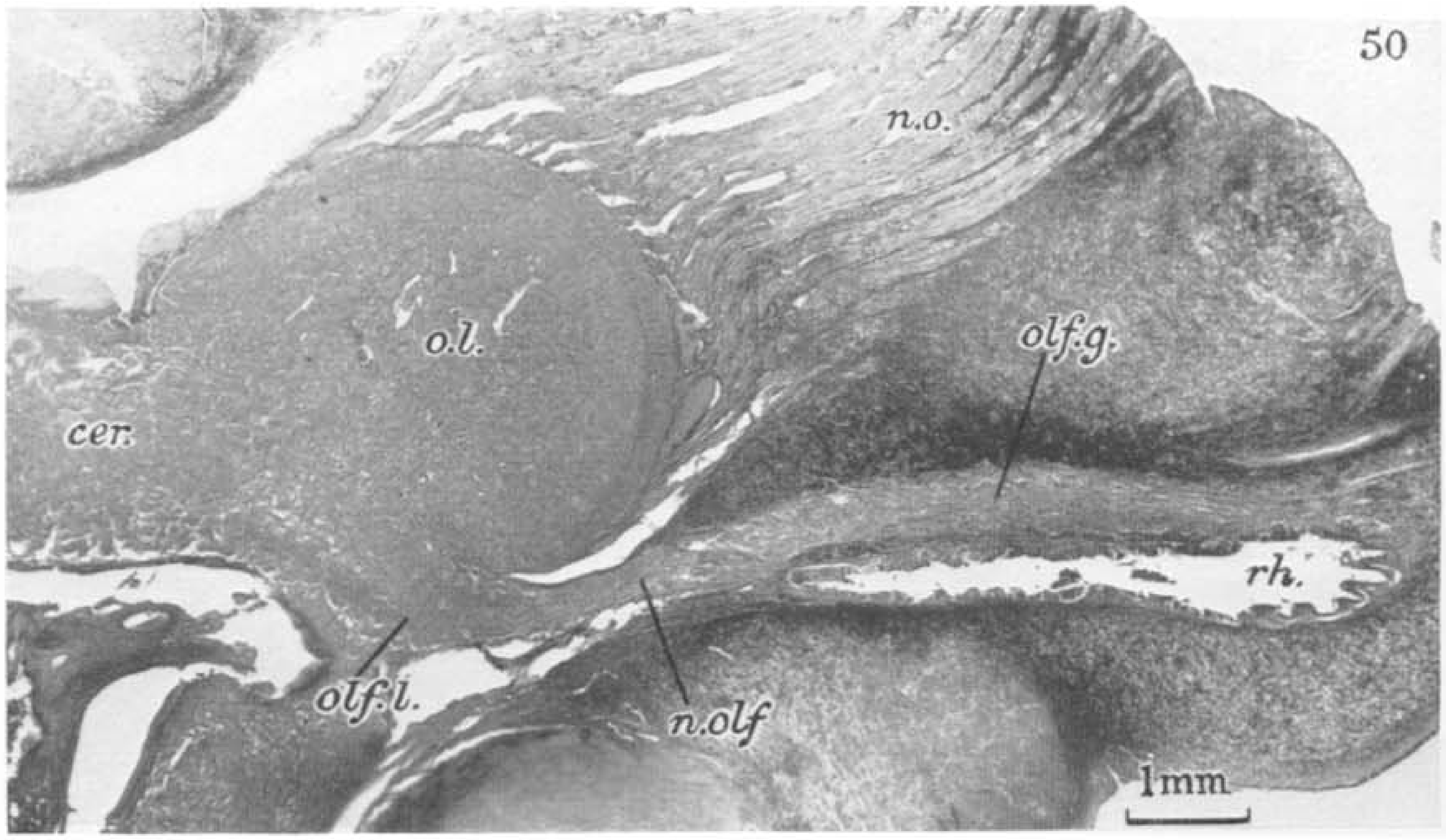
50
n.o.
o.l.
olf.g.
cer.
rh.
olf.l.
n.olf
1mm

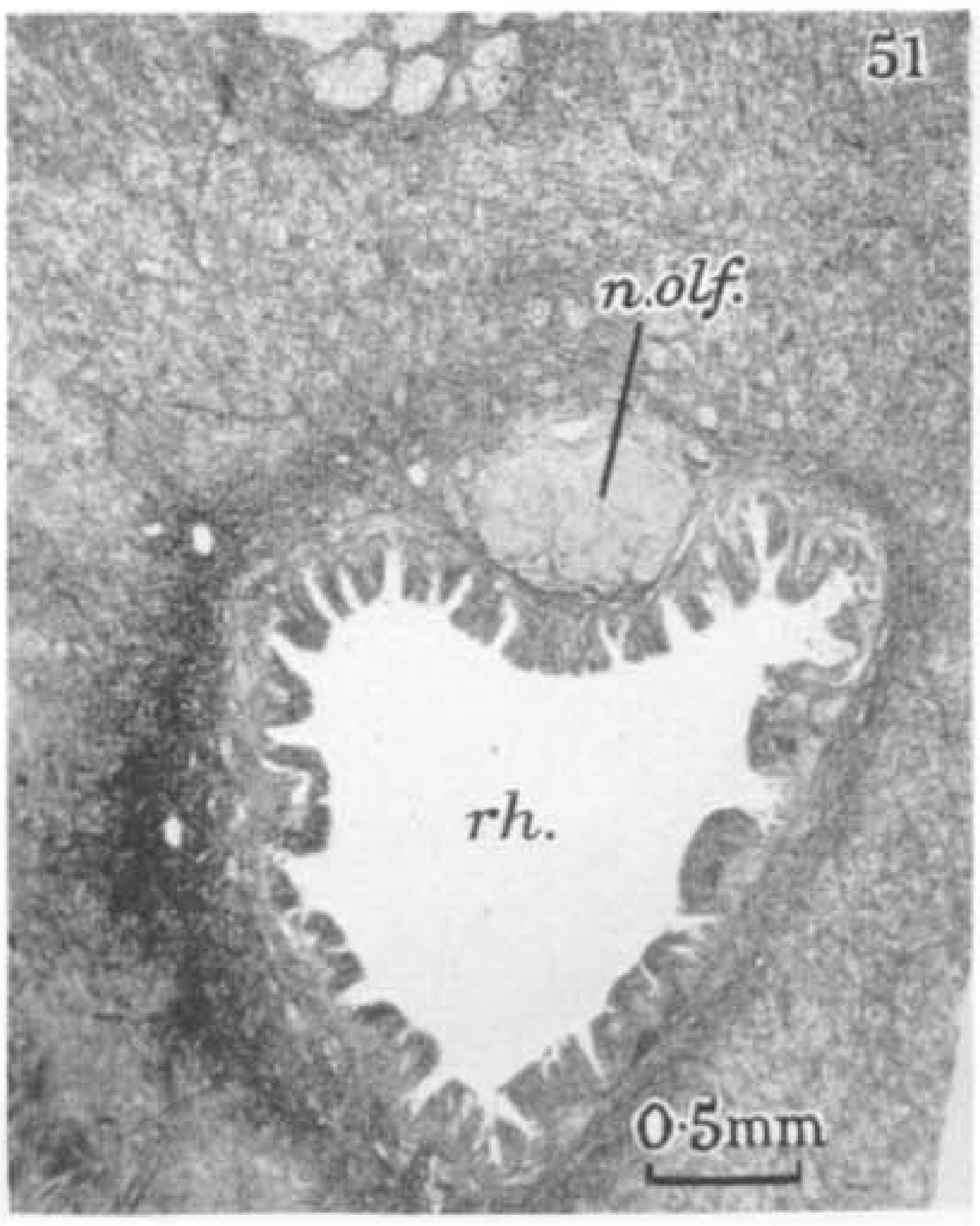
51
n.olf.
rh.
0·5mm

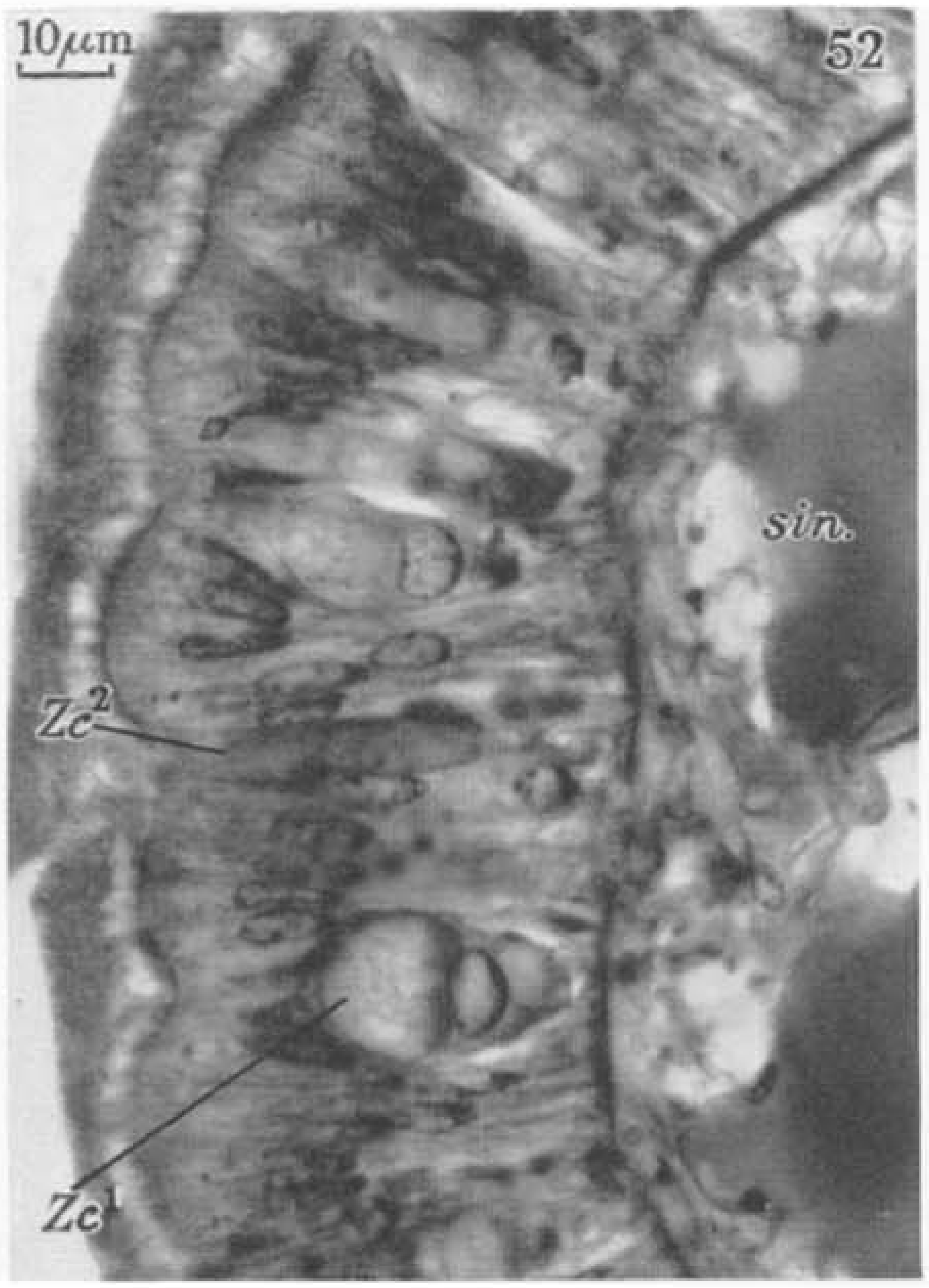
10μm
52
sin.
Zc²
Zc¹

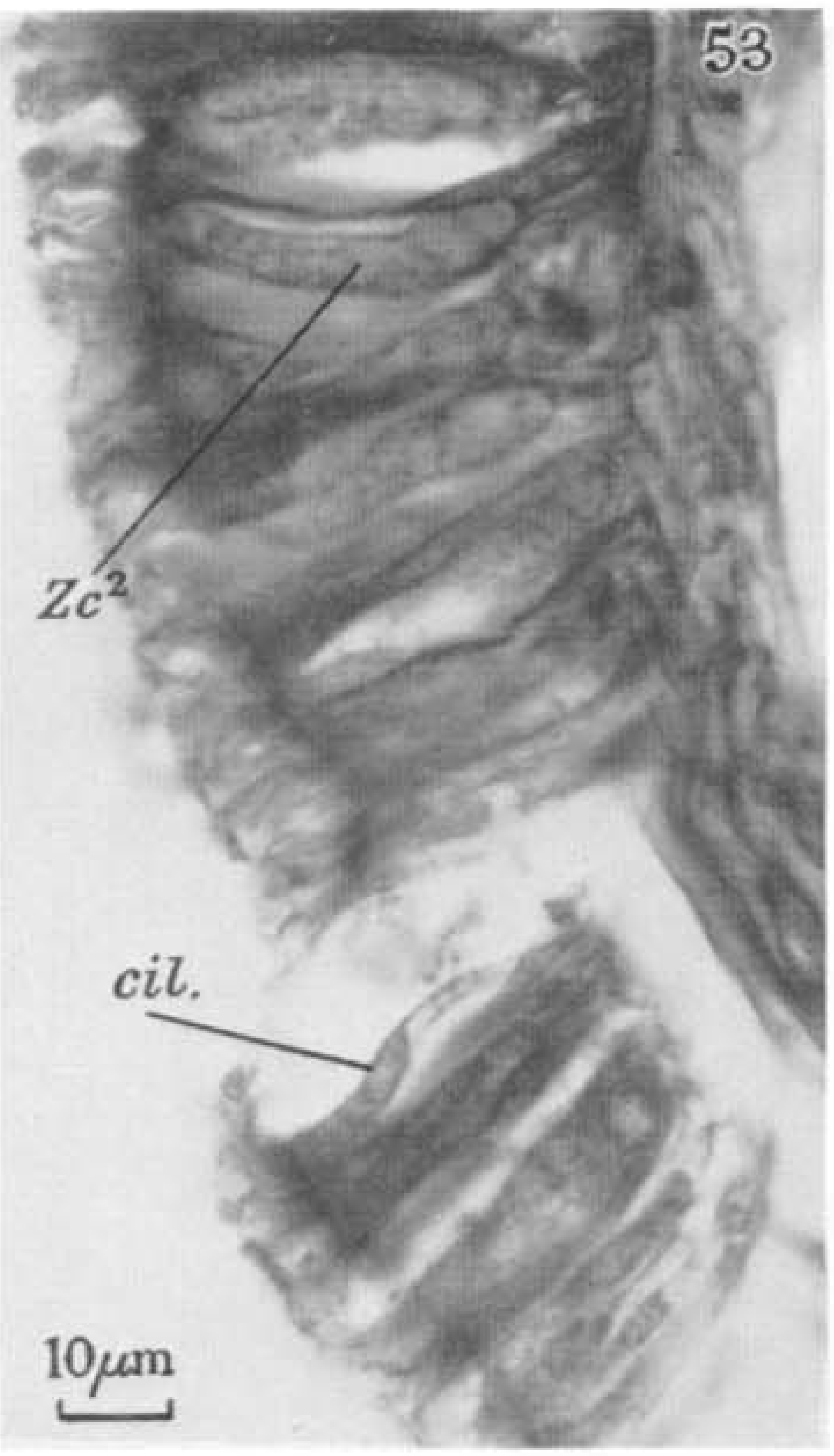
53
Zc²
cil.
10μm


50μm
54
olf.g.

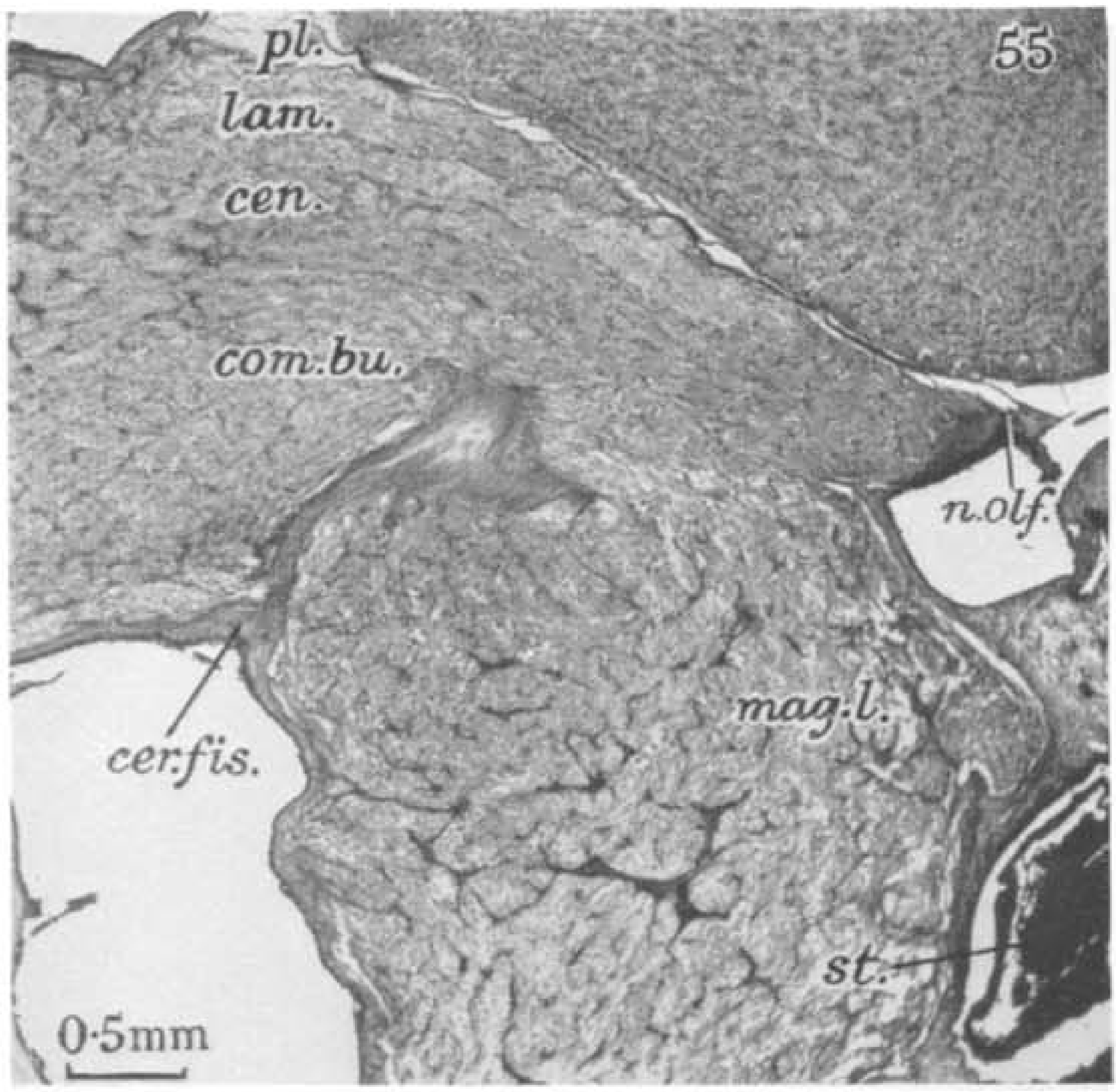
pl.
55
lam.
cen.
com.bu.
n.olf.
cer.fis.
mag.l.
st.
0·5mm

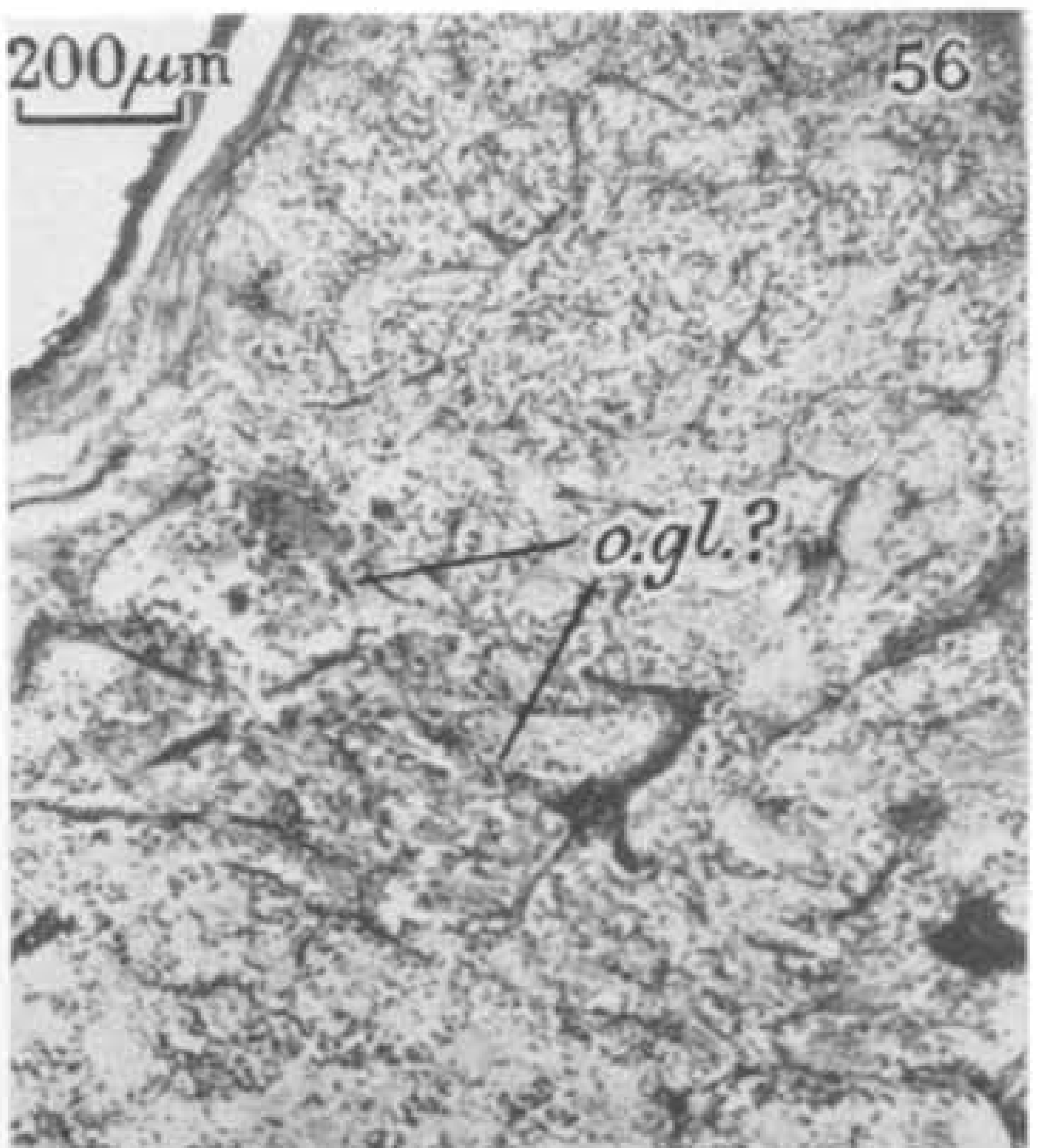
200μm
56
o.gl.?

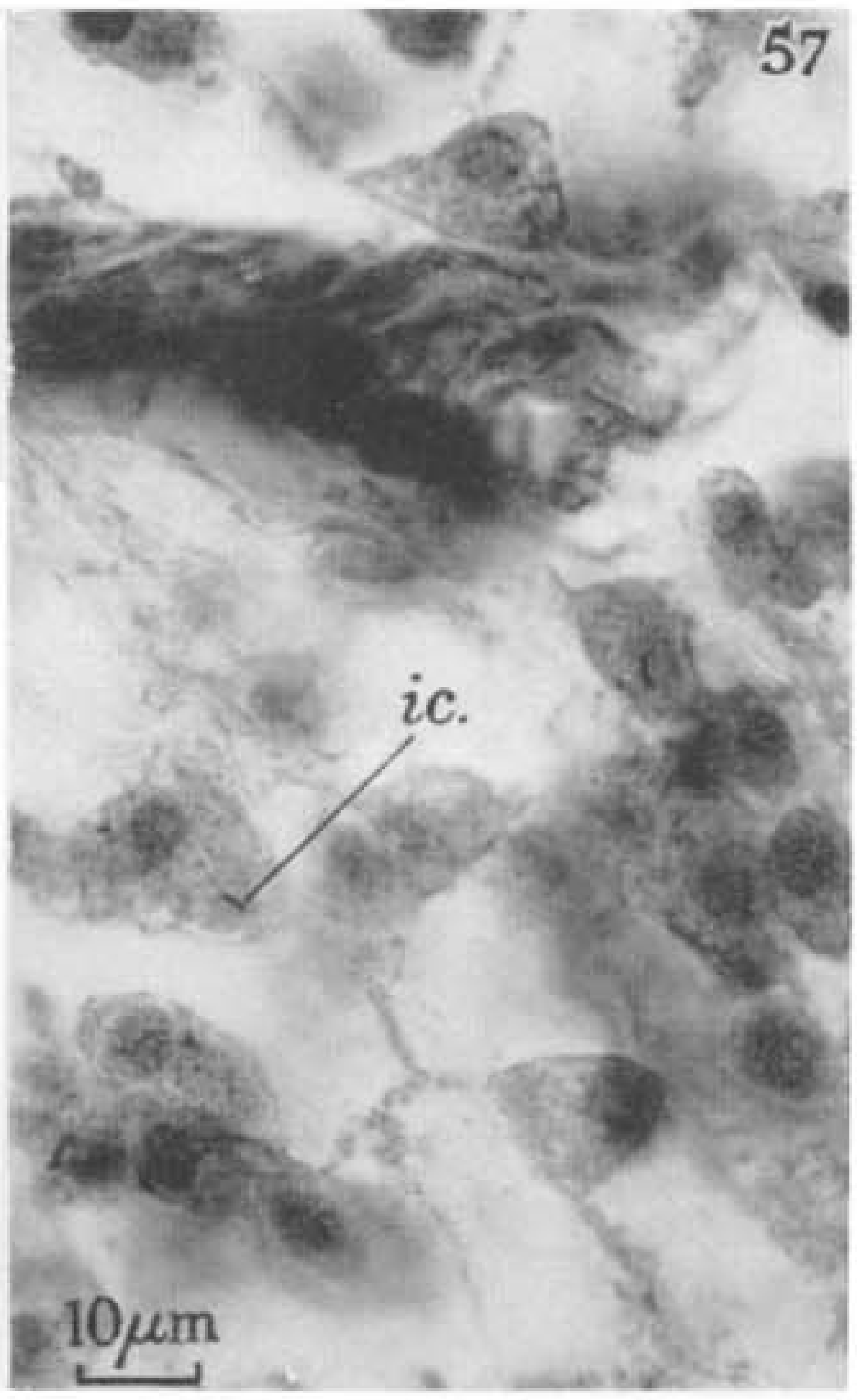
57
ic.
10μm

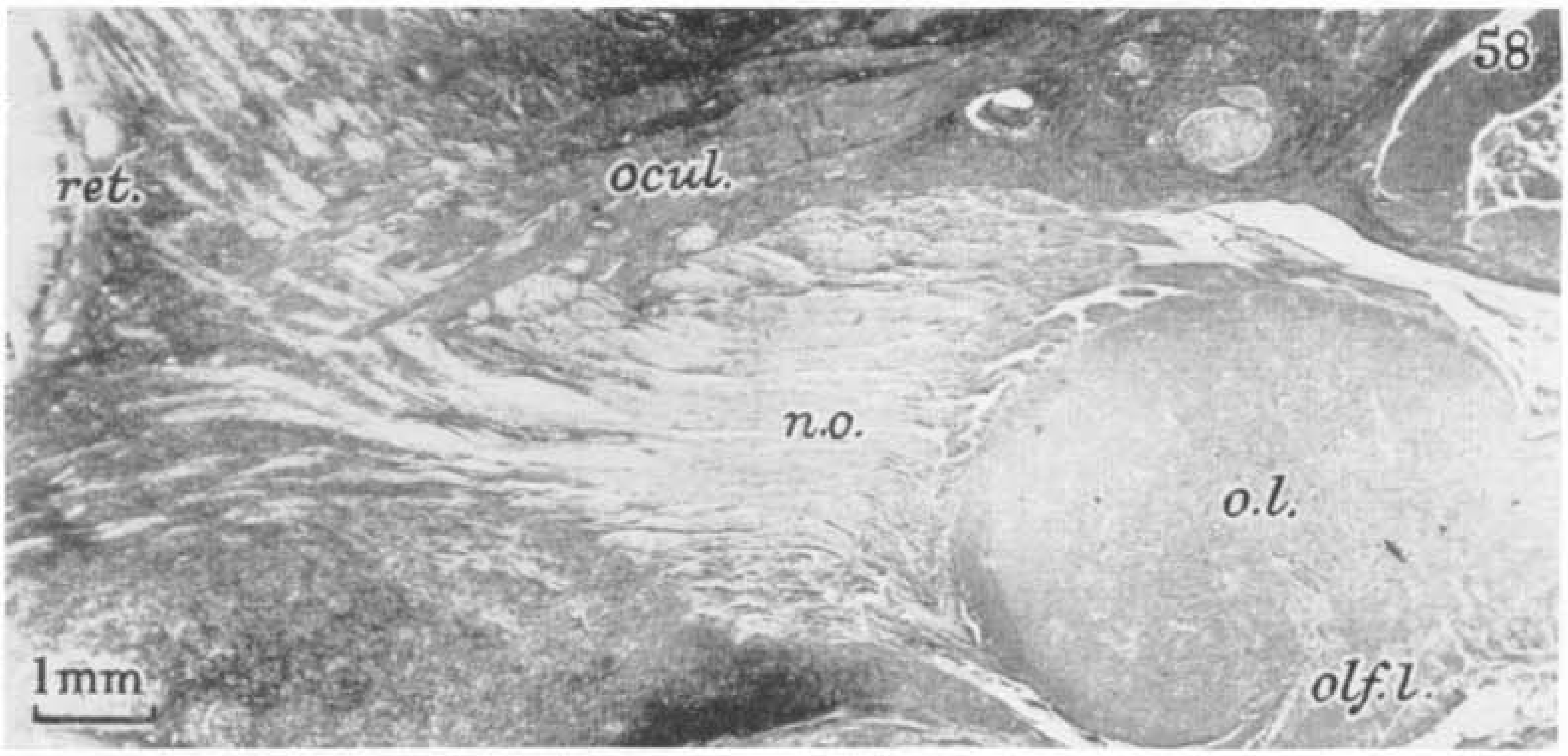
58

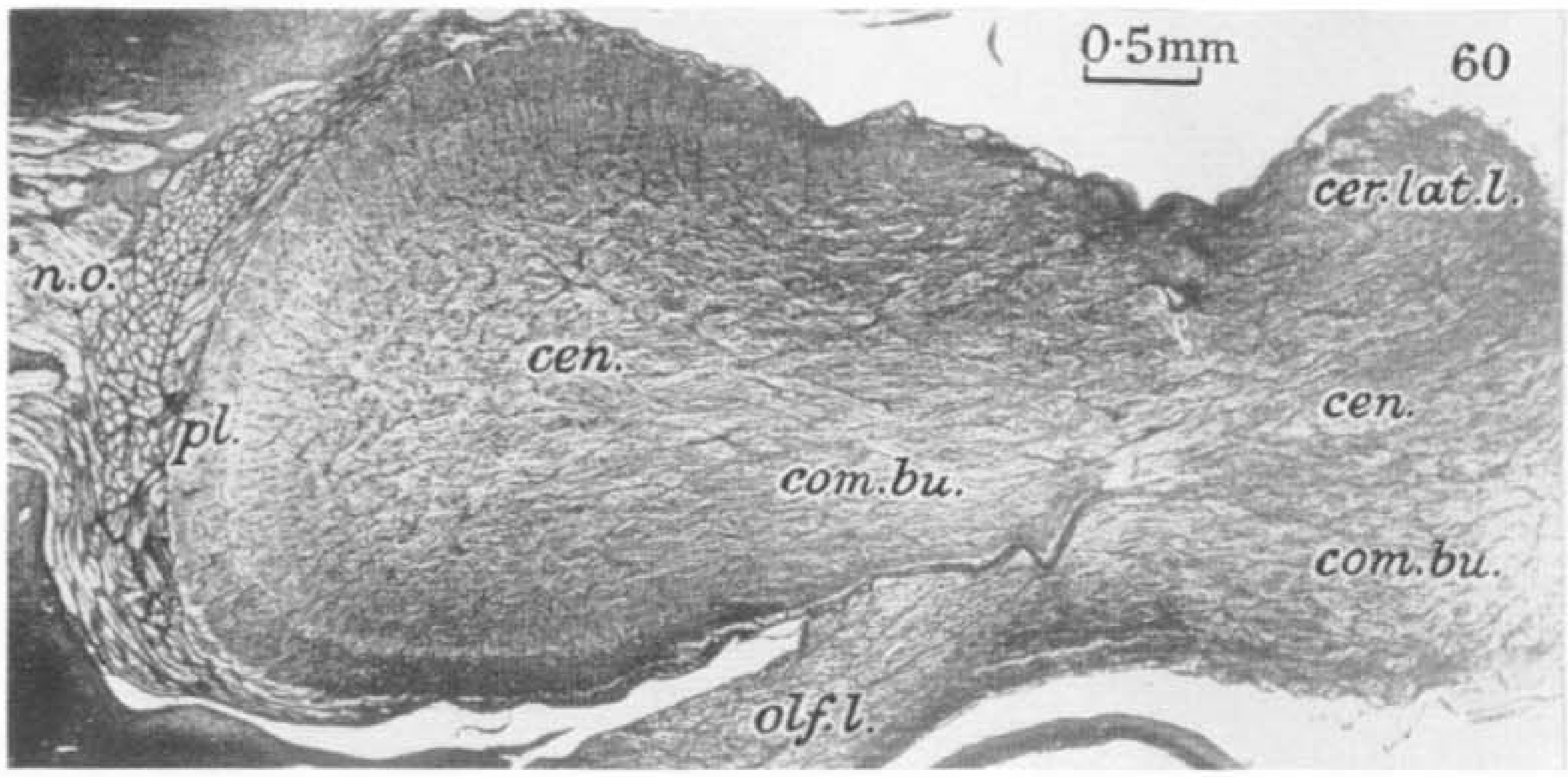
60

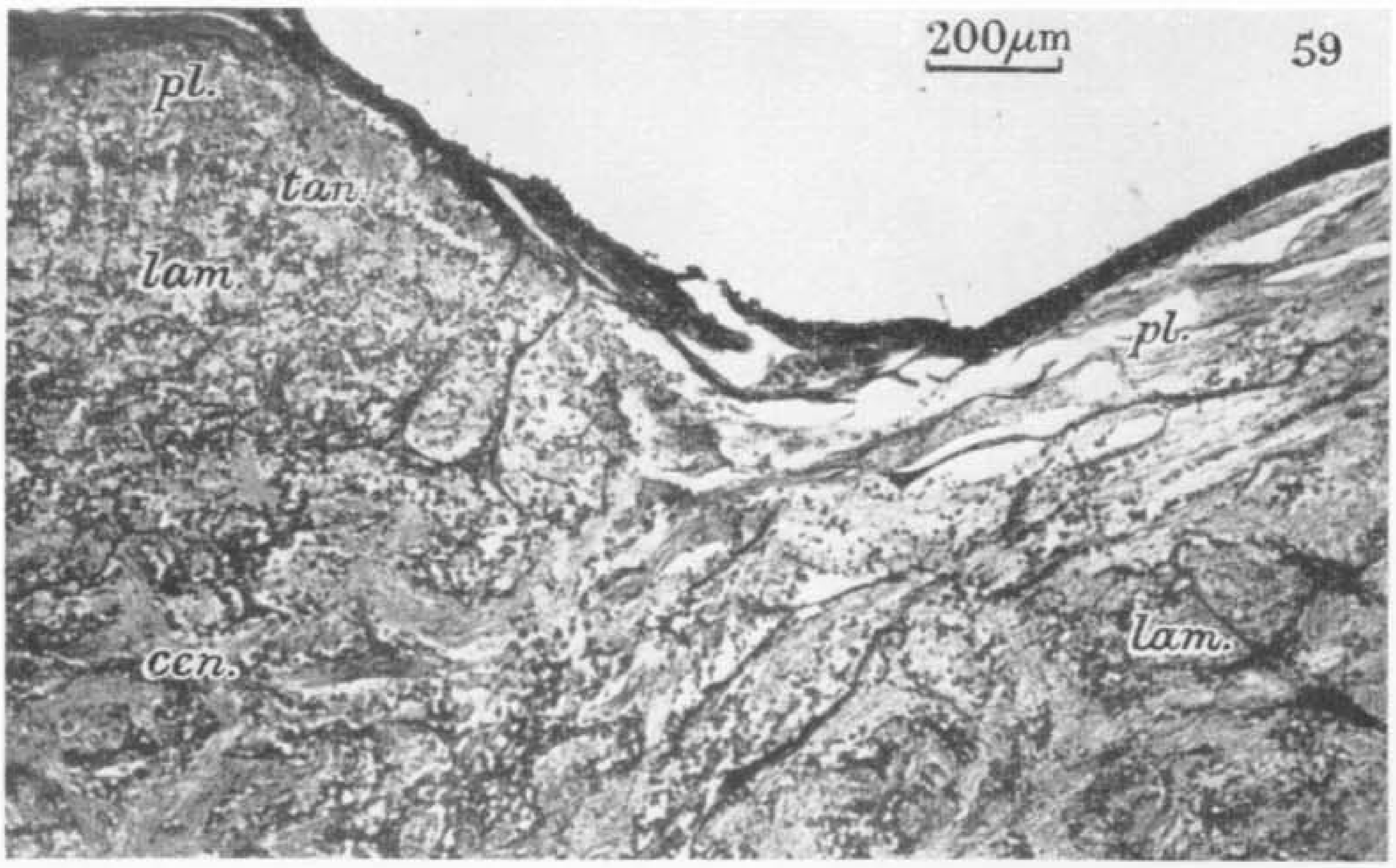
59

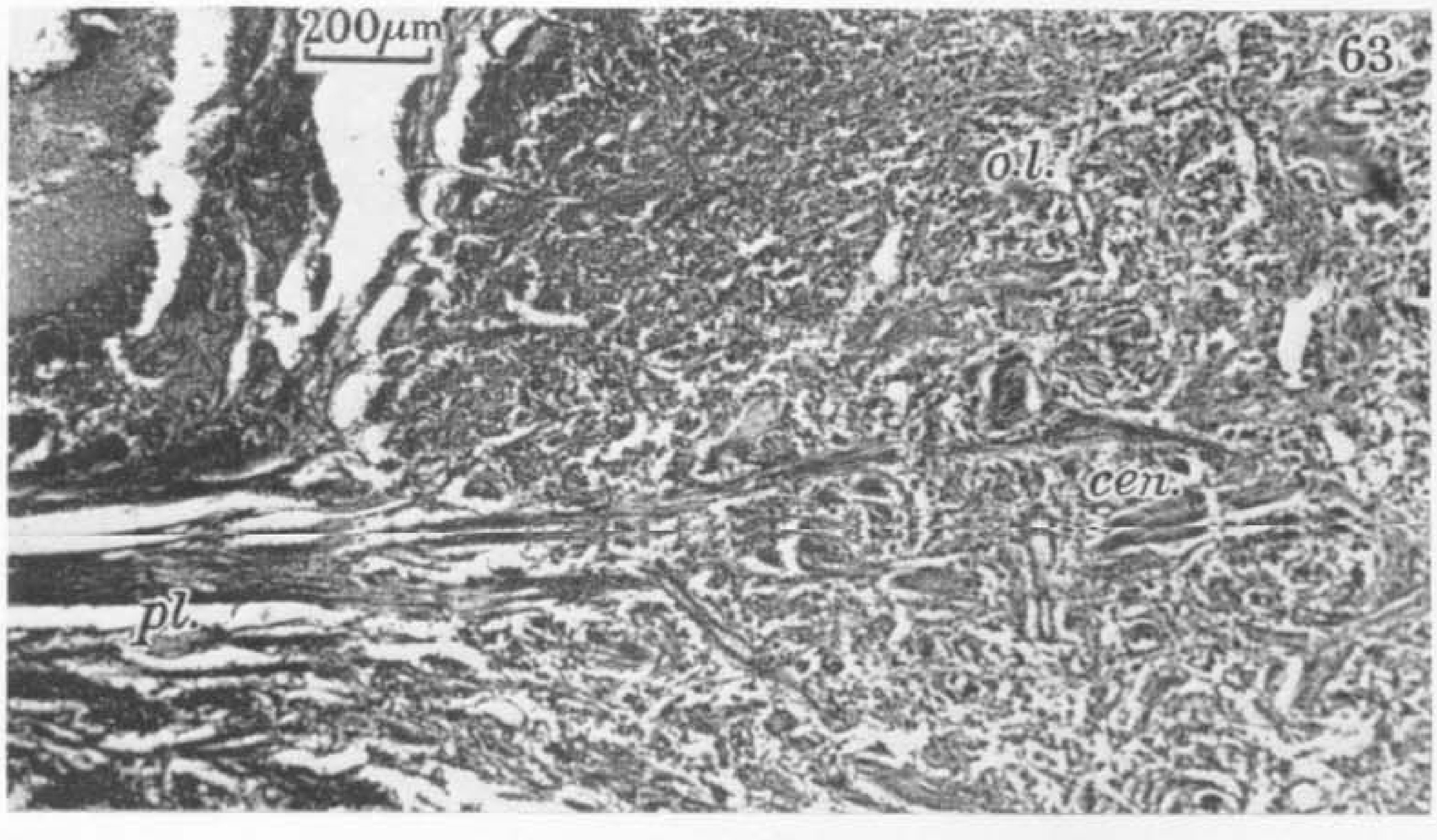
63

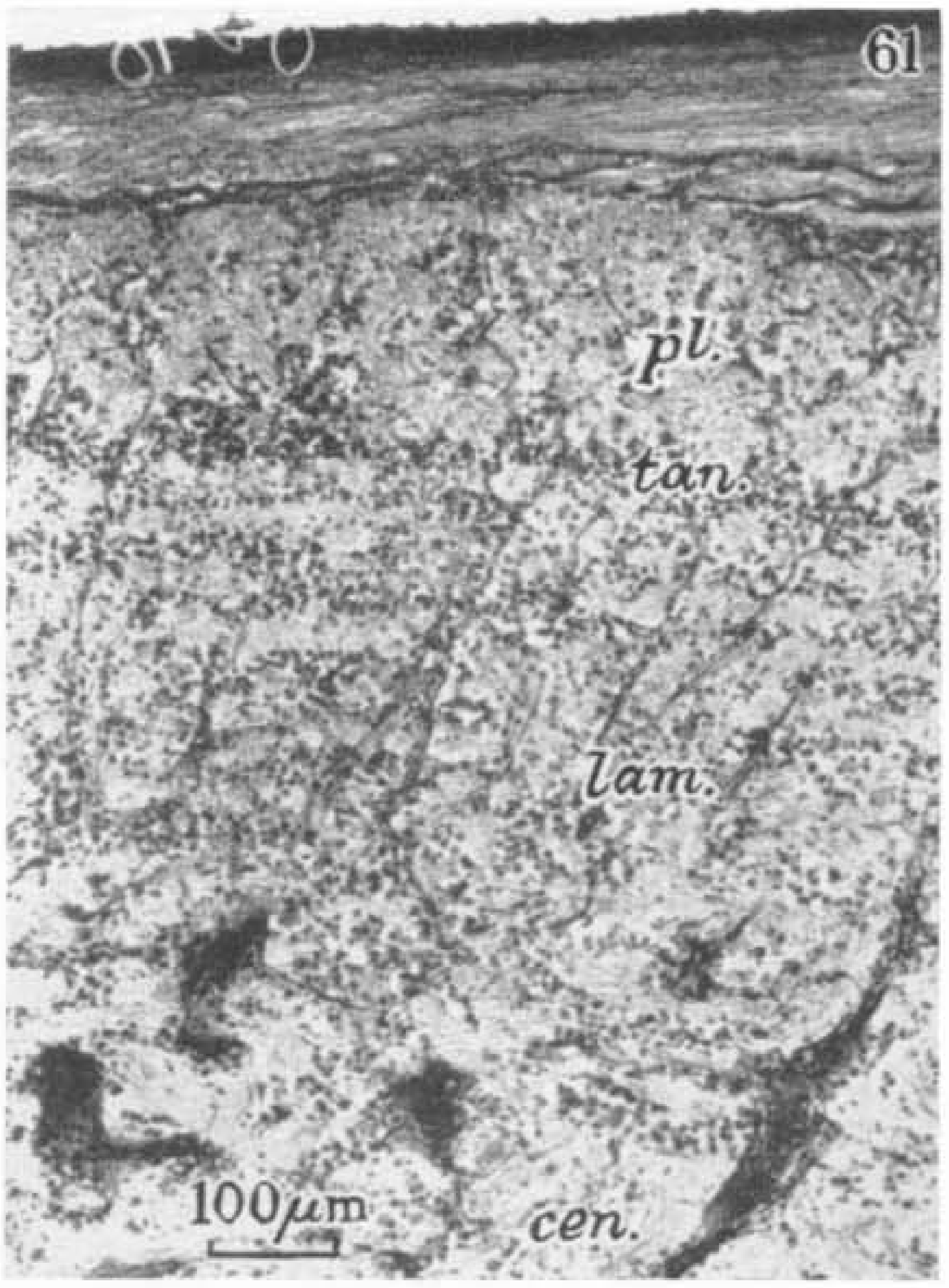
61

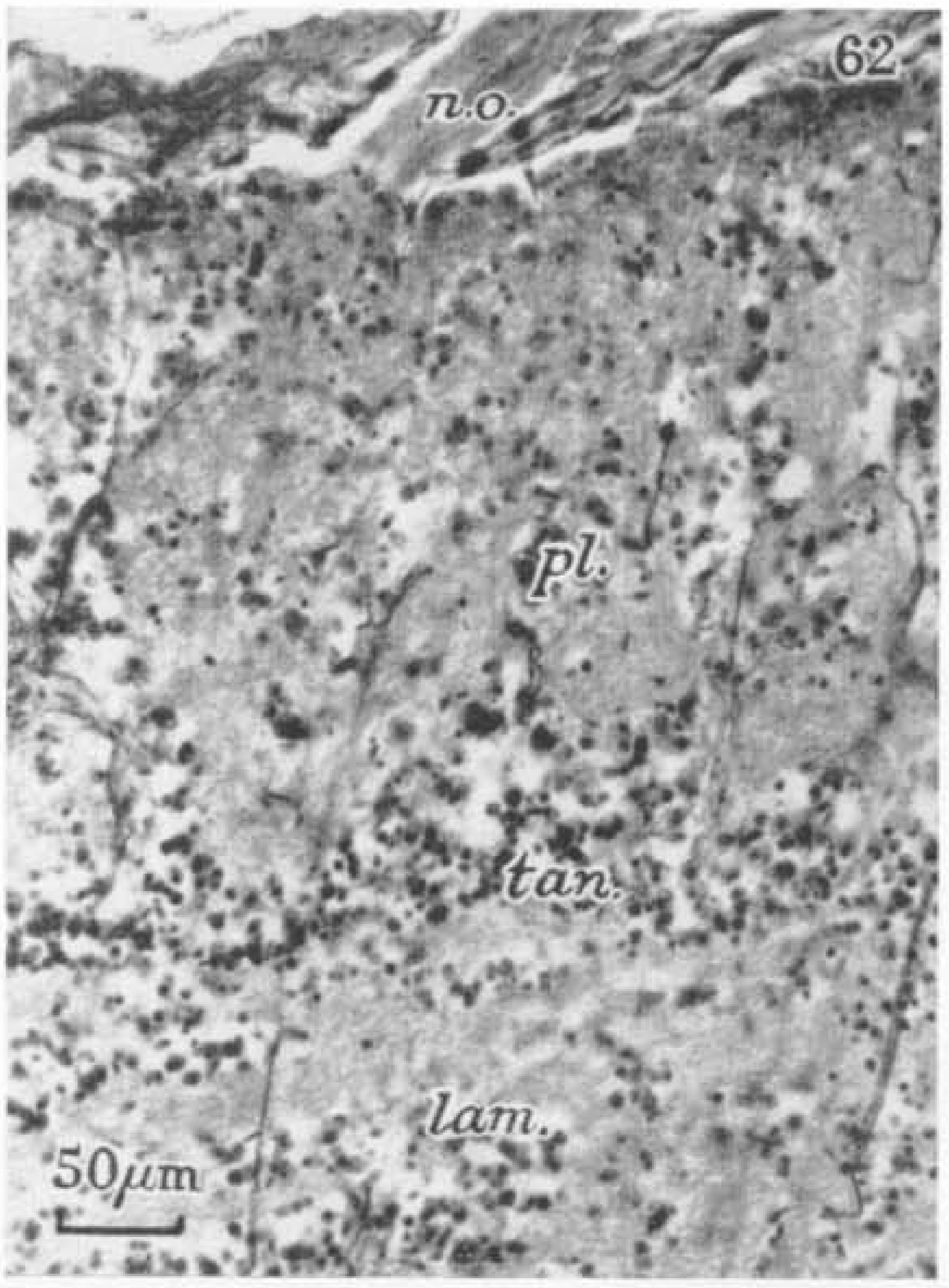
62

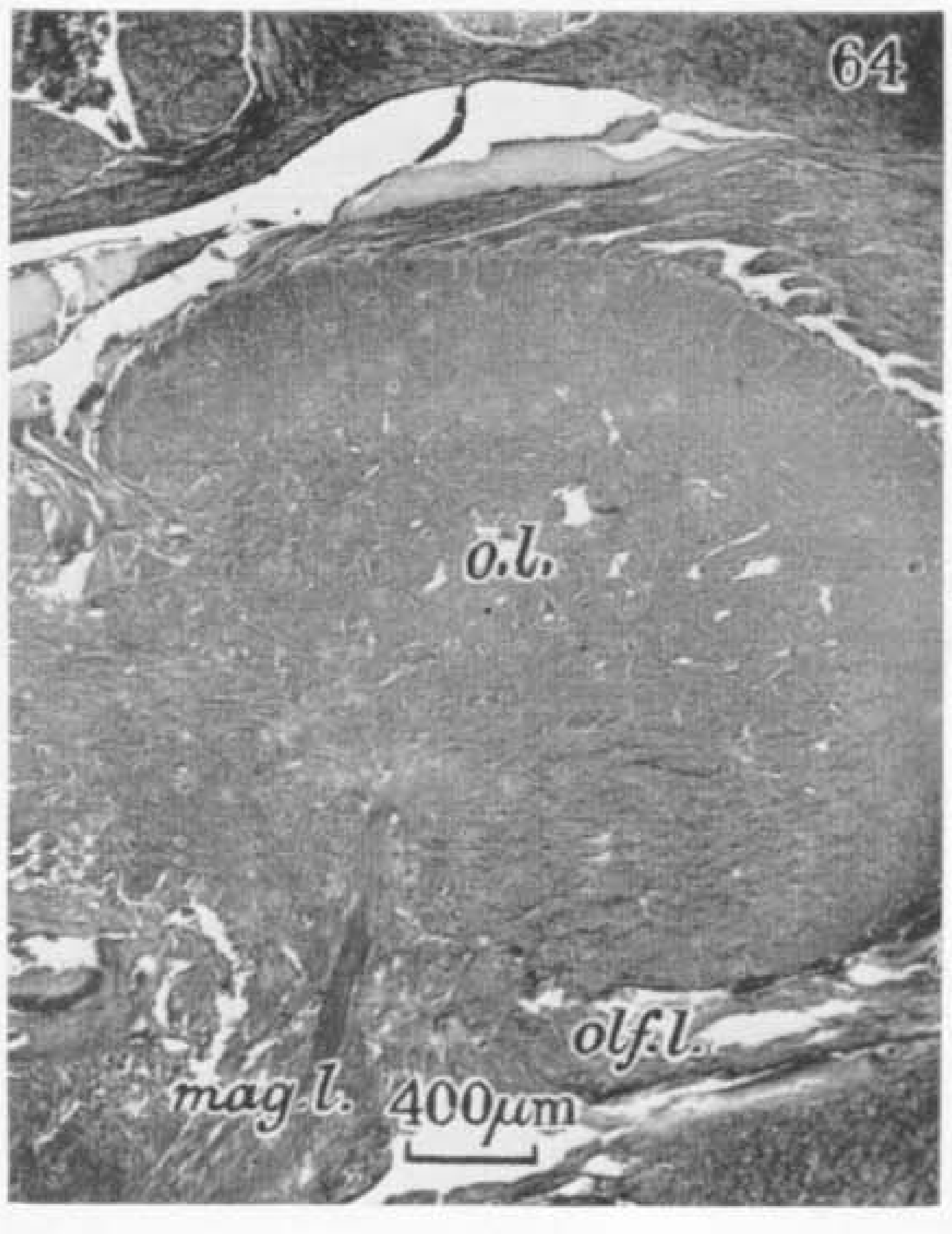
64